









Renal Epithelioid Angiomyolipoma with Aggressive Progression: A Case Report and Literature Review

Emre Altıntaş¹  Ali Furkan Batur²  Mehmet Kaynar²  Murat Gül² 
Murat Akand²  Serdar Göktaş²  Zeliha Esin Çelik²  Özcan Kılıç² 

1 Akcakale State Hospital, Department of Urology, Şanlıurfa, Turkey

2 Selcuk University Medical Faculty, Department of Pathology, Konya, Turkey

Abstract

Epithelioid cellular morphology can be seen in clinically benign usual (or classic) angiomyolipoma (AML). Perivascular Epithelioid Cell Tumors (PEComa) are rarely seen as a variant of AML and usually benign in nature; however, they may have unpredictable pathological behavior. Here, we present a case of renal PEComa with malignant clinical progression and compare it with the current literature. A 56-year-old patient with a history of recurrent side pain present for about four months applied to our clinic. A hypodense mass was detected on the upper pole of the left kidney by ultrasonography. Computerized tomography showed an 8x4 cm mass originating from the upper pole of the left kidney and the adrenal gland, and was thought to invade the psoas muscle. The patient underwent a left transperitoneal radical nephrectomy. During the operation, vena cava inferior repair was required due to invasion and performed. Histopathologic examination revealed a PEComa. During the third month follow-up visit, a recurrent mass and lymph node enlargement were detected at the operation site. The mass was excised, and histopathology revealed a PEComa again. Considered as a rare variant of AML, PEComa is a tumor with the potential to exhibit malignant behavior. Although only a limited number of cases of renal PEComa have been reported; diagnosis, treatment, and follow-up are important due to their high potential for malignancy.

Key words: Renal Epithelioid Angiomyolipoma, PEComa, Angiomyolipoma.

Cite this article as: Altıntaş E, Batur AF, Kaynar M, Gül M, Akand M, Göktaş S, Çelik ZE, Kılıç O. Renal epithelioid angiomyolipoma with aggressive progression: A case report and literature review. Arch Curr Med Res. 2021;2(2):128-131

Corresponding Author:

Emre Altıntaş, Akcakale State Hospital, Department of Urology,
Şanlıurfa, Turkey
E-mail: dre.altintas@gmail.com



Content of this journal is licensed under a Creative Commons Attribution-NonCommercial 4.0 International License.

INTRODUCTION

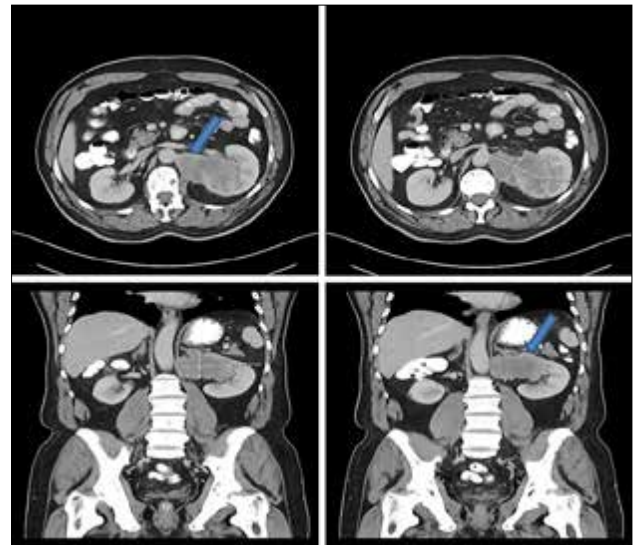
Angiomyolipoma (AML) constitute 3% of solid renal masses (1). Although AMLs are mostly composed of smooth muscle, blood vessels, and fat cells, Epithelioid AML (Perivascular Epithelioid Cell Tumor-PEComa), a type of AML that may show malignant potential, is caused by perivascular epithelial cells (2). 2016 WHO Renal Neoplasia Classification defined Renal Epithelioid AML as a potentially malignant mesenchymal neoplasm (3) PEComa is in the "Tumors of uncertain differentiation" group in the 2020 WHO classification of soft tissue tumors. (4) Like classic AML, PEComa can be seen as sporadic or with tuberous sclerosis syndrome (1). PEComa group consists of renal and hepatic AMLs, clear cell-sugar-tumor of the lung, lymphangiomyomatosis, myelomelanocytic clear cell tumor of ligamentum teres. Therefore, PEComa can be observed in many tissues such as retroperitoneum, abdominopelvic region, gastrointestinal tract, kidney and the liver (5). In this case report, an aggressive case of renal PEComa showing invasion to adjacent tissues is presented.

CASE REPORT

A 56-year-old male patient was admitted due to left flank pain that had been ongoing for a few months. The patient had no history of hematuria, another disease, or a previous surgical operation. Following the physical examination, ultrasonography (USG) was performed because of a suspected mass in the left lumbar region. A hypoechoic mass approximately eight cm long was detected in the middle-upper pole of the left kidney. Later, computed tomography (CT) revealed a heterogeneous hypodense mass of 84 mm by 52 mm that extended exophytically in the upper-middle part of the left kidney (Figure 1). The mass was invading the left diaphragmatic crus and partially

holding in the adrenal gland. It also was invading the psoas muscle and part of the renal vein. No abnormality was shown by the patient's routine laboratory tests. The patient underwent an open transperitoneal radical nephrectomy. Vena cava inferior was opened due to the possible invasion and repaired afterwards. On the 10th postoperative day, the patient was discharged without any complications.

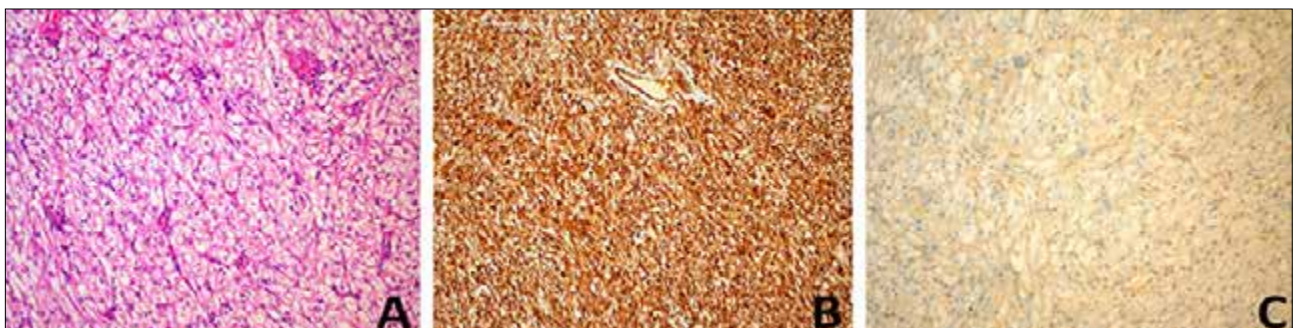
Figure 1. Computerized Tomography (CT) images of the heterogenous hypodense mass, 84x52 mm



The pathology result was reported to be an epithelioid AML or PEComa with dimensions of 8 x 6 x 4.5 cm. Tumor cells were immuno-diffused positive with immunohistochemical staining for vimentin. Focal staining was observed with HMB-45, Cd31, and SMA. (Figure 2) Staining with CD34, S100, desmin, and melanin A was not observed. The Ki-67 index was high. Local necrosis areas were observed. The tumor invaded the kidney parenchyma. There was no sign of invasion of the renal artery and vein.

Figure 2. Microscopic images of tumor cells:

- A: Tumoral structure consisting of nesting of epithelioid cells around the vessels (HEX200)**
- B: Widespread vimentin positivity in tumor cells (X200)**
- C: HMB45 positivity in tumor cells (X200).**



At the third month follow up visit, a control CT revealed a mass 10 mm in diameter which was reported to be possibly a lymphadenopathy (LAP) in the left kidney lobe. No surgery was planned at this stage and a decision was made to check the progression of the mass 3 months later with another follow-up CT. 3 months later, the patient's positron emission tomography using fluorodeoxyglucose (FDG) revealed a mass of 27 mm by 18 mm (SUV max: 16.68) adjacent to the psoas anterior muscle in the left kidney lobe. In addition, another mass with a size of 20 mm by 26 mm (SUV max: 22,27) with FDG involvement was observed in the left paraaortic region. The patient was presented and discussed at the oncology council, and the decision was made that the recurrent mass be removed surgically. The recurrent mass and LAP were excised 3 months after the first operation. Epithelioid AML that was compatible with the first pathology, was determined again from the histopathologic examination. Lymph node involvement was present. (Diffuse staining was performed with vimentin, EMA, and SMA S-100; focal immunosuppressive with HBM-45, desmin, and Melan-A.)

DISCUSSION

Martignoni first described PEComa as a potentially mesenchymal neoplasm that is a variant of AML (6). In 2016, tumors consisting of 80% or more epithelioid cells were defined by World Health Organization (WHO) as a PEComa (3). Histologically, classic AMLs consist of mature adipose tissue, dysmorphic blood vessels, and spindle-shaped smooth muscle cells. An AML consists of polygonal, atypical, and dense cytoplasm, vesicular nucleus, and prominent nucleoli (6).

Renal PEComas usually present with nonspecific symptoms such as flank pain and hematuria. Laboratory tests are often normal. CT observes the PEComas as a solid mass with heterogeneous changes. Unlike classic AMLs, they contain very little or no adipose tissue. In radiological evaluations, PEComa can be confused with renal cell carcinoma (1). In our case, the kidney mass observed by CT was reported by radiology as renal cell carcinoma.

Immunohistochemically, PEComas are observed to be mostly diffused or focally stained with melanocyte markers such as HMB45, Melan A, and A103. PEComas can also be stained with smooth muscle markers such as SMA and negatively stained with the S100 marker (7). In our case, focal staining with HMB45 and diffuse staining

with vimentin was observed, and negative staining was observed with S100. Some studies have suggested that Ki-67, a proliferation marker, can also be used as a marker in PEComas. (8). Tumor cells were stained with Ki-67 in the case of a renal PEComa with ileum and lung metastasis reported by Shi et al. (9). In another study, it was reported that the Ki-67 index was above 10% and that overexpression of p53 could increase the potential for malignant behavior of PEComas (10). The PEComa in our case was high Ki-67 index and therefore exhibited malignant behavior.

In a study by Brimo et al. (11), they examined 40 epithelioid-AML cases. In order to predict malignant behavior, they have determined four features: (1) >70% atypical epithelioid cells, (2) >2 mitotic figures per 10 hpf, (3) atypical mitotic figures, and (4) necrosis; the presence of 3 or all of the features was highly predictive of malignant behavior. In another study, Nese et al. (12), which included 41 renal PEComa cases, metastasis was detected in half of the cases, and three of these patients died during the follow-ups. In the same study (12), the relationship with tuberous sclerosis, necrotic areas larger than 7 cm, extrarenal spread, renal vein invasion, and a pattern of cancer-like growth have been reported as criteria of malignancy.

In our case, the size of the tumor was 8 x 6 x 4.5 cm. Invasion of the surrounding tissues (especially the vena cava's inferior wall) in CT, necrosis, and strong staining with Ki-67 in the pathological evaluation showed a high potential for malignancy. There was no relationship with tuberous sclerosis in the case. The patient who was diagnosed with metastatic lymph nodes after nephrectomy; consulted with the oncology department and was evaluated for chemotherapy. Currently, there is no conventional and routine chemotherapy protocol for PEComas. A 50% reduction in PEComa recurrence was detected after two cycles of doxorubicin in a study with doxorubicin (13).

Regarded as a rare variant of AML, PEComa is a tumor with the potential to exhibit malignant behavior. When imaging methods of detection are used, PEComas can often be confused with renal cell carcinomas. Although only a limited number of cases of renal PEComa have been reported, its diagnosis, treatment, and follow-up are important due to its high potential for malignancy. High-risk patients may receive adjuvant treatment; however, there are not well-established treatment guidelines.

Declarations

The authors received no financial support for the research and/or authorship of this article. There is no conflict of interest.

REFERENCES

1. Zhu J, Li H, Ding L, Cheng H. Imaging appearance of renal epithelioid angiomyolipoma: A case report and literature review. *Medicine*. 2018;97(1):e9563.
2. Hasan H, Howard AF, Alassiri AH, et al. PEComa of the terminal ileum mesentery as a secondary tumour in an adult survivor of embryonal rhabdomyosarcoma. *Curr Oncol* 2015;22:e383–6.
3. Martignoni G, Reuter VE, Fletcher CDM, World Health Organization (2016) Angiomyolipoma of World Health Organization classification of tumours of the urinary system and male genital organs. Lyon: IARC Press, pp 62–65
4. The 2020 WHO Classification of Soft Tissue Tumours: news and perspectives. Sbaraglia M, Bellan E, Tos Dei A. *Journal of The Italian Society of Anatomic Pathology and Diagnostic Cytopathology*. Published: Nov 3, 2020. doi: 10.32074/1591-951X-213
5. Ameurtesse H, Chbani L, Bennani A, Toughrai I, Beggui N, Kamaoui I, Elfatemi H, Harmouch T, Amarti A. Primary perivascular epithelioid cell tumor of the liver: new case report and literature review. *Diagn Pathol* 2014; 9: 149.
6. Martignoni G, Pea M, Bonetti F, Zamboni G, Carbonara C, Longa L, Zancanaro C, Maran M, Brisigotti M, Mariuzzi GM. Carcinomalike monotypic epithelioid angiomyolipoma in patients without evidence of tuberous sclerosis: a clinicopathologic and genetic study. *Am J Surg Pathol*. 1998;22(6):663–72
7. Jayaprakash PG, Mathews S, Azariah MB, Babu G. Pure epithelioid perivascular epithelioid cell tumor (epithelioid angiomyolipoma) of kidney: case report and literature review. *J Canc Res Therapeut*. 2014;10(2):404–406.
8. Stone CH, Lee MW, Amin MB, et al. Renal angiomyolipoma: further immunophenotypic characterization of an expanding morphologic spectrum. *Arch Pathol Lab Med* 2001;125:751–758.
9. Ooi SM, Vivian JB and Cohen RJ: The use of the Ki-67 marker in the pathological diagnosis of the epithelioid variant of renal angiomyolipoma. *Int Urol Nephrol* 2009 41: 559-565.
10. Shi H, Cao Q, Li H, et al. Malignant perivascular epithelioid cell tumor of the kidney with rare pulmonary and ileum metastases. *Int J Clin Exp Pathol* 2014;7:6357–63.
11. Li W, Guo L, Bi X, Ma J, Zheng S. Immunohistochemistry of p53 and Ki-67 and p53 mutation analysis in renal epithelioid angiomyolipoma. *Int J Clin Exp Pathol*. 2015;8(8):9446–9451.
12. Brimo F, Robinson B, Guo C et al. Renal Epithelioid Angiomyolipoma With Atypia: A Series of 40 Cases With Emphasis on Clinicopathologic Prognostic Indicators of Malignancy. *Am J Surg Pathol*. 2010;34(5):715-22.
13. Nese N, Martignoni G, Fletcher CD, et al. Pure epithelioid PEComas (so-called epithelioid angiomyolipoma) of the kidney: a clinicopathologic study of 41 cases: detailed assessment of morphology and risk stratification. *Am J Surg Pathol* 2011; 35:161-76.
14. Cibas ES, Goss GA, Kulke MH, Demetri GD, Fletcher CD. Malignant epithelioid angiomyolipoma ('sarcoma ex angiomyolipoma') of the kidney: a case report and review of the literature. *Am J Surg Pathol* 2001; 25:121-6.