

Unexpected Arrhythmia in a Young Patient: Hookah Smoking Triggered Atrial Fibrillation

Muhammed Keskin¹  Tufan Çınar¹  Murat Selçuk¹  Selami Doğan¹ 
Vedat Çiçek¹  Ahmet Lütfullah Orhan¹ 

¹ Health Sciences University, Sultan II. Abdulhamid Han Training and Research Hospital, Department of Cardiology, Istanbul, Turkey

Abstract

In the current literature, although it has been known that hookah smoking increases the heart rate and predisposes to arrhythmia, no case report has been published regarding hookah smoking and the development of arrhythmia, including atrial fibrillation (AF). In this case report, we presented an adult patient without known cardiovascular disease who experienced AF after a heavy hookah smoking session. Following IV amiodarone infusion, normal sinus rhythm was achieved. The patient was advised to stop hookah smoking and discharged with a beta-blocker therapy and an oral anticoagulant treatment for 3 weeks. The patient's rhythm was normal at one-month outpatient visit. This case emphasizes that hookah smoking could not be considered as a less harmful alternative to cigarette smoking because of its' apparent side effects to the cardiovascular system.

Key words: Atrial Fibrillation, Hookah, Smoking..

INTRODUCTION

Smoking is one of the major causes of mortality and morbidity, especially in patients with cardiovascular disease. In recent years, hookah (water pipe) smoking, which is considered to be less harmful than cigarette smoking, is becoming increasingly popular among young population. However, experimental studies have shown that the chemicals and toxic substances in the hookah have

the potential to cause cardiovascular events as much as cigarette smoking (1-3). Following the inhalation of smoke through hookah leads to increase of blood pressure, heart rate, and peripheral vascular resistance in the body. In addition, people who smoke hookah have a higher risk of acute myocardial infarction due to abnormal platelet activation (4). In the current literature, although it has been known that hookah smoking increases the heart rate and predisposes to arrhythmia, no case report

Cite this article as: Keskin M, Çınar T, Selçuk M, Doğan S, Çiçek V, Orhan AL. Unexpected arrhythmia in a young patient: Hookah smoking triggered atrial fibrillation. Arch Curr Med Res. 2021;2(2):132-135

Corresponding Author:

Tufan Çınar, Health Sciences University, Sultan II. Abdulhamid Han Training and Research Hospital, Department of Cardiology, Istanbul, Turkey
E-mail: drtufancinar@gmail.com



Content of this journal is licensed under a Creative Commons Attribution-NonCommercial 4.0 International License.

has been published regarding hookah smoking and the development of arrhythmia, including atrial fibrillation (AF) (5). In this case report, we presented an adult patient without known cardiovascular disease who experienced AF after a heavy hookah smoking session.

CASE REPORT

A 28-year-old male patient without a history of alcohol or illegal drug use presented to our emergency department with complains of palpitation, which developed approximately 30 minutes before admission. The patient expressed that he smoked hookah for 1 hour and suddenly felt irregular heartbeats. The patient did not experience a chest pain or dyspnea during this period. The past medical history was not contributory and he did not smoke hookah before. On emergency admission, patient's heart rate was 180 beats per minute and his blood pressure was 138/73 mmHg. Physical examination did not reveal any abnormal findings other than increased heart rate. Electrocardiography (ECG) obtained in the emergency room showed an irregular heart rhythm with the absence of P waves (Figure 1-A). The patient's oxygen saturation was 94% in ambient air and blood gas analysis revealed that his carboxyhemoglobin level was 6%. The patient was diagnosed with an AF, and intravenous (IV) diltiazem (25 mg) was administered to control his heart rate by an emergency physician. The laboratory analysis demonstrated no abnormal findings. Echocardiography was performed providing a normal left ventricular ejection fraction and mild mitral insufficiency. Despite the administration of IV diltiazem (25 mg) and IV metoprolol (5 mg) at the emergency room, a control over the heart rate was not achieved. Therefore, the patient was consulted to our department and a single dose of 600 mg propafenone was given to achieve normal sinus rhythm. In addition, the patient was anticoagulated with a low-molecular-weight heparin (enoxaparin, 8000 anti-Xa IU/0.8 ml, SC). It was observed that the patient's abnormal rhythm did not convert to sinus rhythm after 3 hours of propafenone treatment. Hence, it was decided to administer IV amiodarone to convert the patient's abnormal rhythm into sinus rhythm. A loading dose of IV 150 mg amiodarone was given over 30 minutes, followed by a 1 mg/min infusion for 6 hours. After that, a normal sinus rhythm was achieved following 4 hours

of IV amiodarone infusion (Figure 1-B). After medical cardioversion, a bed-side echocardiography performed and revealed no abnormal findings. A posterior-anterior chest scan was also performed, revealing normal findings (Figure 2). The patient was advised to stop a hookah smoking, and he was discharged with a beta-blocker therapy and an oral anticoagulant treatment for 3 weeks. The patient's rhythm was normal at the two-week and one-month control appointments after the first admission.

Figure 1. (A) Electrocardiography showed an irregular heart rhythm with the absence of P wave (B) Following IV amiodarone infusion, normal sinus rhythm was achieved

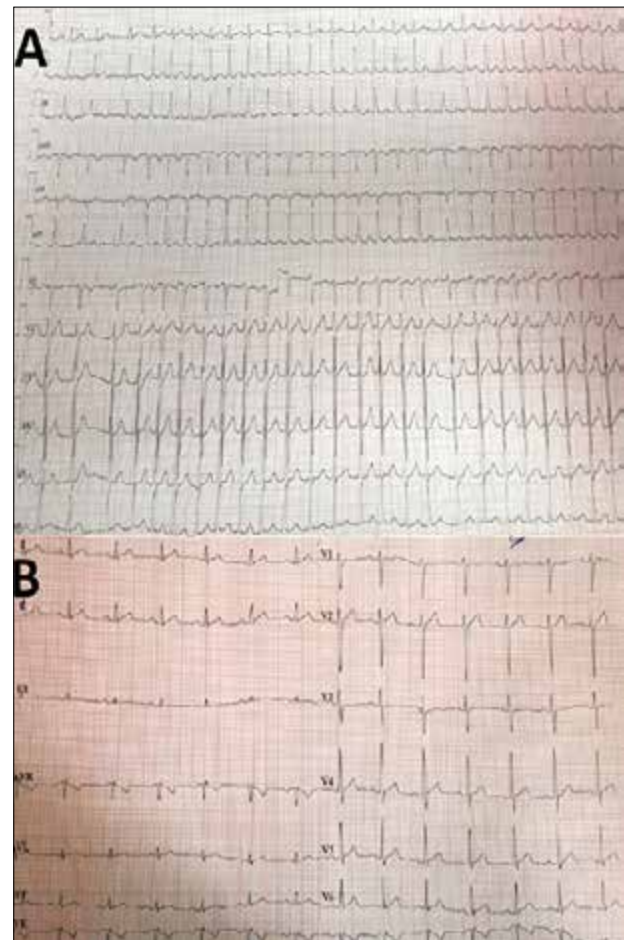
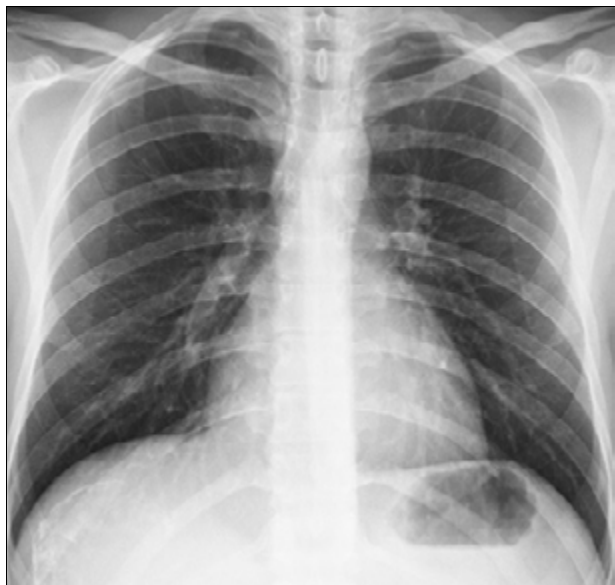

Figure 2. Posterior-anterior chest scan of the patient (Noted that there were no significant pathological findings)



DISCUSSION

Currently, the negative effects of cigarette smoking on the cardiovascular system are well-known. So far, there have been fewer studies on hookah smoking than cigarette smoking despite the fact that hookah has been available for many years, especially in the Middle East region. The primary chemical and toxic substances present in hookah are nicotine, carcinogenic polycyclic aromatic hydrocarbons, aromatic amines, aldehydes, phenolic compounds, tar, heavy metals, and ammonia (1-5). Hookah smokers are exposed to these toxic compounds for much longer periods than those who smoke cigarette. Moreover, plasma carboxyhemoglobin levels are usually higher in hookah smokers than cigarette smokers due to the prolonged exposure to carbon monoxide (CO) (2). Since CO's affinity for hemoglobin is 200 times greater than oxygen, the oxygen curve shifts to the left, resulting in a cellular hypoxia and deterioration in cellular respiration. This cellular hypoxia and prolonged exposure to toxic substances may lead to cardiac arrhythmia as shown in our case.

Hookah smoking also might have some negative effects on the cardiovascular system. Heavy hookah smoking can lead to the hyperactivation of the sympathetic nervous system, thereby resulting in an

increase in the peripheral vascular resistance and heart rate (6-9). Moreover, abnormal fluctuation in systolic and diastolic blood pressures can occur due to the deterioration in the baroreflex mechanism (10). The prolonged exposure to hookah smoking also increases susceptibility to acute ischemia because of endothelial dysfunction and hypercoagulability. Moreover, the levels of nicotine during hookah smoking are considerably higher than cigarette smoking. Consequently, cardiac arrhythmia, including AF, can occur due to increased sympathetic activation and plasma catecholamine levels. Previously, occurrence of ischemic heart disease, atherosclerosis, and heart failure after long periods of hookah smoking have been reported (8-9). Even though abnormal elevation in heart rate and predisposition to arrhythmia after hookah smoking is demonstrated in experimental studies, no specific hookah-related arrhythmia has been reported in the current literature. According to our literature research and to our knowledge, this is the first case of acute AF due to heavy hookah smoking. Besides, this case emphasizes that hookah smoking should not be considered as a less harmful alternative to cigarette smoking because of its apparent side effects to the cardiovascular system. In this case, for the first time in the literature, we presented an adult patient who presented with AF following heavy exposure to hookah smoke.

Declarations

The authors received no financial support for the research and/or authorship of this article. There is no conflict of interest.

REFERENCES

1. Shihadeh A, Saleh R. Polycyclic aromatic hydrocarbons, carbon monoxide, "tar", and nicotine in the mainstream smoke aerosol of the narghile waterpipe. *Food Chem Toxicol.* 2005;43:655-61.
2. Schubert J, Hahn J, Dettbarn G, Seidel A, Luch A, Schulz TG. Mainstream smoke of the waterpipe: does this environmental matrix reveal as significant source of toxic compounds? *Toxicol Lett.* 2011;205:279-84.
3. Shihadeh A. Investigation of mainstream smoke aerosol of the argileh waterpipe. *Food Chem Toxicol.* 2003; 41:143-52.
4. Jacob P 3rd, Abu Raddaha AH, Dempsey D, Havel C, Peng M, Yu L, et al. Nicotine, carbon monoxide, and carcinogen exposure after a single use of a water pipe. *Cancer Epidemiol Biomarkers Prev.* 2011;20:2345-53.
5. Shihadeh A, Salman R, Jaroudi E, Saliba N, Sepetdjian E, Blank MD, et al. Does switching to a tobacco-free waterpipe product reduce toxicant intake? A crossover study comparing CO, NO, PAH, volatile aldehydes, "tar" and nicotine yields. *Food Chem Toxicol.* 2012;50:1494-8.

6. El-Nachef W, Hammond S. Exhaled carbon monoxide with waterpipe use in us students. *JAMA*. 2008;299:36–8.
7. Elsayed Y, Dalibalta S, Abu-Farha N. Chemical analysis and potential health risks of hookah charcoal. *Sci Total Environ*. 2016;569-570:262–8.
8. Jaquet FS, Shapiro D, Uijtdehaage SHJ. The acute effects of smoking on heart rate and blood pressure: an ambulatory study. *Hum Psychopharmacol Clin Exp*. 1994;9:273–83.
9. Al-Safi SA. Does smoking affect blood pressure and heart rate? *Eur J Cardiovasc Nurs*. 2005;4:286–9.
10. Quillen JE, Rossen JD, Oskarsson HJ, Minor RL Jr, Lopez AG, Winniford MD. Acute effect of cigarette smoking on the coronary circulation: constriction of epicardial and resistance vessels. *J Am Coll Cardiol*. 1993;22:642-7.