

Olgu Sunumu

Oral Rehabilitation of a Severe Trauma Patient: Case Report

Trauma Geçirmi Hastada Tüm A ız Tedavisi: Olgu Sunumu

Nilüfer Tülin POLAT¹, Mustafa Hayati ATALA¹, Fuat AHMETO LU², Serkan POLAT³

¹ nönü Üniversitesi Di Hekimli i Fakültesi Protetik Di Tedavisi AD, Malatya

² nönü Üniversitesi Di Hekimli i Fakültesi Endodonti AD, Malatya

³ nönü Üniversitesi Di Hekimli i Fakültesi A ız, Di ve Çene Cerrahisi AD, Malatya

Abstract

It's been aimed to do the oral rehabilitation of a patient with a delayed dental treatment after a severe accident, by using limited invasive methods. It is learned from the anamnesis that the patient had been fallen down from the fourth floor at the age of 16. The patient's oral and dental treatments, except the broken mandibula, had been postponed 4 years for various reasons. She had lost her teeth numbered 11, 25 and 43. Her fourteen teeth had different sized crown fractures and 7 of these were embedded in the alveolar bone and mucosa. In the bite occlusion, upper and lower alveolar ridges were in contact on the right side and lower posterior teeth were in contact with the upper alveolar ridge on the left. There was only 1 mm freeway space. Because of the patient's depression; she had no demand or tolerance to invasive treatments. The lower anterior 3 teeth which had lost the alveolar support and 3 embedded roots in the right maxilla had been extracted. Partial bone adjustments -upper and lower right side and upper left alveolar ridges- had been performed. The roots (23, 44, 45, and 46) had been exposed to the oral cavity. Endodontic treatments were done to these roots and 8 other teeth. On the upper right side, 3 implants had been placed after the sinus lifting. The treatment had been completed with the porcelain-fused-to-metal restorations. The patient had been satisfied by minimum invasive treatment in a complicated case.

Key words: Dental trauma, crown fracture, crown-root fracture.

Özet

Bu olguda, a ır bir kaza sonrası dental tedavisi gecikmi ve yo un giri imsel tedavilerden kaçınan bir hastanın, daha basit tedavilerle tüm a ız restorasyonu amaçlanmı tır. Alınan anamnezde, hastanın 16 ya ındayken balkondan dü tü ü, mandibula da dahil bir çok kemi inin kırıldı ı ö renildi. Çe itli nedenlerle mandibula kırılı dı ındaki, di ve çevre doku tedavileri 4 yıl ertelenmi olan hastanın, 11, 13, 14, 15, 16, 25, 26, 43, 45 nolu di lerinin kaybedilmi oldu u görüldü. 17, 18, 24, 33, 34, 35 ve 42 nolu di lerde de i ik boyutlarda kron kırıklar vardı. 23, 44 ve 46 nolu di lerinin kökleri kemik içinde gömülü kalmı tı. Kapanı ta sa da alt ve üst di siz kreter birbirlerine, solda ise alt yan grup di ler üst di siz krete de iyordu. stiraht ve oklüzal vertikal boyutları arasında 1 mm fark vardı. Hastanın görünümünden dolayı psikolojisi bozulmu , yo un giri imsel tedavilere istek ve tahammülü yoktu. Bu nedenle, a ır travmatik tedavilerden kaçınıldı. Bunun için alt anterior bölgedeki kemik deste i kaybedilmi 31, 32 ve 41 nolu di ler çekildi. Sa üst ve alt, sol üst kreterlerden kemik kaldırıldı. 23, 44 ve 46 nolu di lerin kökleri açılı a çıkarıldı. Bu köklere ve 24, 36 ve 47 nolu di lere kanal tedavisi yapıldı. Sa tarafta sinüs yükseltme ve 3 adet implant yerle tirilmesi sonrası alt üst metal destekli seramik restorasyonlarla tedavi tamamlandı. Karma ık bir vakada, çok az giri imsel uygulamayla hasta memnun edildi.

Anahtar Kelimeler: Dental travma, kron kırılı 1, kron-kök kırılı 1.

Introduction

Facial injuries occur more frequently in children than adults and usually as a result of sports activities, falls, car accidents, fights and intentional assaults (1-3). Severity of the cases varies depending on the strength of the impact force and its vector (3). The patients are affected by trauma both physically and mentally (4).

Displacement and/or fracture of the teeth, separation in supportive tissues (gingival tissues, periodontal ligament, and bone) and contusions could occur after the traumatic dental injuries (5). Treatment plan differs according to the age of the patient, degree of apexification, fracture region, elapsed time after the trauma and the grade of the mobility or the displacement in traumatic injuries (4).

The treatment strategy of a crown-root fracture is complex and the esthetics is an important requirement. Several different treatments for this kind of problem, ranging from the maintenance and use of the tooth fragment either as a temporary or permanent crown

(6, 7); definitive crown after an orthodontic or surgical extrusion or a crown lengthening (6) to an extraction of the residual tooth followed by an immediate or delayed implant surgery (8, 6) or fixed partial denture (9).

This type of treatment usually implies a multidisciplinary approach, with an endodontist, an orthodontist, a periodontologist, a surgeon and a prosthodontist (10).

In this case, the aim was to restore the complex dento-alveolar problems with minimal invasive therapy in a patient who didn't get any treatment for 4 years after the severe trauma.

Case Report

20 years old severely depressed female patient was applied to the Prosthodontic clinic with the complaints of; loss of function, esthetics and phonation. The patient gave a history of fall from the fourth floor of a building four years ago. The patient's oral and dental treatments, except the broken mandibula, had been postponed 4 years for various reasons.

Clinical and radiographic examinations were performed. The patient had lost their teeth numbered 11, 25 and 43. Her fourteen teeth had complicated crown and crown-root fractures. Seven of these fractured teeth were embedded in the alveolar bone and mucosa.

In the bite occlusion, upper and lower alveolar ridges were in contact on the right side and lower posterior teeth were in contact with the upper alveolar ridge on the left. There was only 1 mm freeway space. Because of the patient's depression; she had no demand or tolerance to invasive treatments.

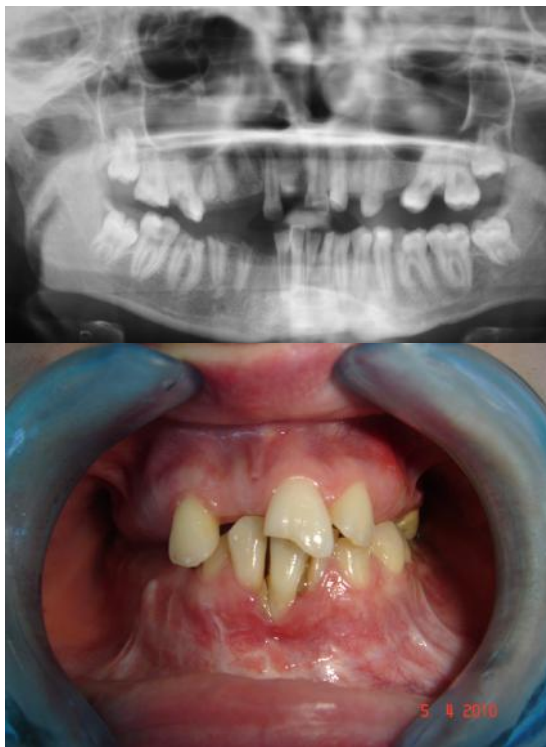


Figure 1. Orthopantomogram and oral view of the patient before treatment

The lower anterior 3 teeth which had lost the alveolar support and 3 embedded roots in the right maxilla had been extracted. Partial bone adjustments -upper and lower right side and upper left alveolar ridges- had been performed. The roots (23, 44, 45, and 46) had been exposed to the oral cavity. Endodontic treatments were done to these roots and 8 other teeth.

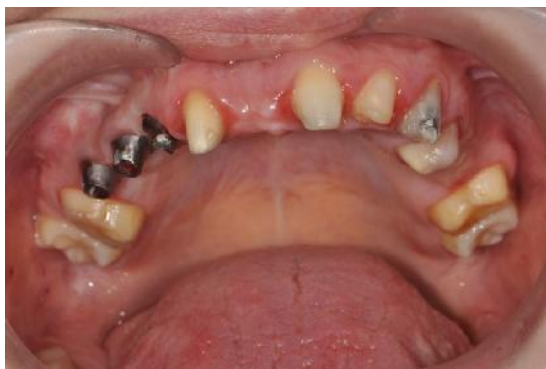

Figure 2. After post-core restoration and implant placements

Cleaning and shaping of root canals were instrumented with a rotary nickel-titanium files (HeroShaper, Migro-Mega, France) using a crown-down technique under abundant irrigation with 5% sodium hypochlorite (NaOCl) and 15% ethylenediaminetetraacetic acid (EDTA). After root canals were dried thoroughly, all canals were obturated using lateral condensation of gutta-percha cones with an endodontic finger spreader and epoxy resin based root canal sealer (AH Plus, De Trey, Dentsply, Konstanz, Germany). The teeth (23, 44, 45 and 46) were restored with titanium prefabricated posts (Screw posts, Svenska Dentorama AB, Stockholm Sweden) and photo-polymerized composite cores (Spectrum TPH 3, Dentsply, UK). On the upper right side, after sinus lifting, 3 implants (Astra Tech Implants, Astra Tech, Mölndal, Sweden) had been placed.

The patient has used fixed and removable provisional prosthesis until her permanent restoration is done. She had waited with these provisional restorations for three months for the osseointegration of the implants.

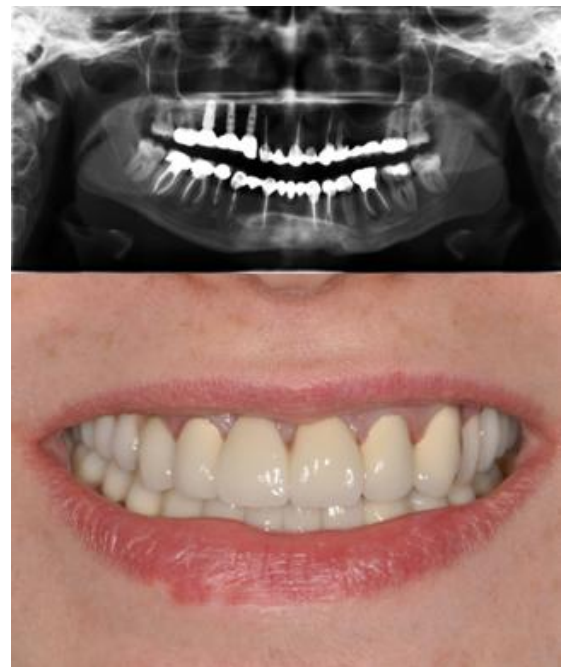


Figure 3. Orthopantomogram of the patient after treatment and Final restorations

After recovery, impressions were taken with additional silicone impression material (SwissTec-C silicone, Coltene/Whaledent, OH, USA). Face-bow records were taken with the (Axioquick, SAM, Prazisionstechnik GmbH - München) face-bow. These records were transferred to the semi-adjustable articulator (SAM 2PX Articulator, SAM Prazisionstechnik GmbH, Germany). Porcelain-fused-to-metal restorations were planned. Metal cast substructures (Wiron 99, Bego, Bremen, Germany) were evaluated for fitting in the mouth. Then porcelain supra-structures had been completed (Vita Omega 900, Vita Zahnfabrik, Bad Sackingen, Germany). The crown and bridge restorations were cemented with temporary cement (Cavex Temporary Cement, Cavex Holland BV, Netherlands). After three weeks of function partial fixed restorations were cemented with glass ionomer cement (Ionofil U, Voco Germany).

The patient had been instructed for oral hygiene procedures and had been scheduled for control after 6 months.

Discussion

The currently accepted dental injuries classification system is based on the World Health Organization's Application of International Classification of Diseases to Dentistry and Stomatology (11), and modified by Andreasen (12). According to this classification;

Complicated crown fracture: A fracture involving enamel and dentin, and exposing the pulp. Fully developed teeth will most likely require a prosthetic crown, thus the patient may wisely choose to have root canal treatment done prior to the restoration (13, 14).

Crown-root fracture: A fracture involving enamel, coronal and radicular dentin, and cementum. These complicated fractures often involve pulpal exposure, and in developing teeth, pulpal protection is essential if the tooth is going to continue to develop. Because the fractures extend to the roots to varying depths, treatment options depend on the level of the fracture. After the removal of the loose tooth fragment, one may allow the gingiva to adapt to the exposed dentin by formation of long junctional epithelium, or surgically expose the fracture site, or extrude the tooth orthodontically or surgically (15). In fully developed teeth, all of these procedures are likely to be associated with root canal therapy (16). Numerous complicated crown fractures and crown-root fractures were seen in this case according to the severity of the trauma.

The key factors in a successful functional and esthetic rehabilitation of complicated crown fracture and crown-root fracture are multidisciplinary approaches, which involves surgeries, endodontics, orthodontics, periodontics, and prosthodontics (17).

Physical trauma is aggravated by the esthetic disfigurement which is a major concern for both the children and their parents (12, 18). The patient was in major depression because of her appearance and the lost functions for 4 years after the trauma. It had been advised to do orthognatic surgery in the other health departments she had appealed. She stated that, she had refused these treatments because of the probable complications and the high costs. Therefore, it's been advised to do minimum invasive treatment procedures. The treatment process period was as short as possible.

Surgical or orthodontic extrusion has been recommended for horizontal and oblique cervical-root-fractured teeth (19). However, alveolar adjustments were done instead of surgical or orthodontic extrusion to the embedded roots because there was not enough occluso-gingival space for the restorations. Some alveolar bone was eliminated during the extrusion of the maxillary embedded roots because the alveolar crests were in occlusion on the right side. It had been waited for 6 months for the implant implementation because it has been thought that this bone elimination on the side of sinus lifting would trigger the bone resorption. Two 3.5 S x 11 mm and one 5x11 mm Astra Tech Dental implant

fixtures (Astra Tech Implants, Astra Tech, Mölndal, Sweden) were placed in this site.

Prefabricated posts are practical and economical than cast posts (20). For this reason prefabricated posts and composite cores were used in this case.

In this complex case, esthetic and function were restored by minimal invasive applications. The patient's mood had improved by the final restoration.

References

1. Holan G, Shmueli Y. Knowledge of physicians in hospital emergency rooms in Israel on their role in cases of avulsion of permanent incisors. *Int J Paediatr Dent* 2003;13:13-9
2. Al-Nazhan S, Andreasen JO, Al Bavardi S Al Roug S. Evaluation of the effect of delayed management of traumatized permanent teeth. *J Endodon* 1995; 21: 391-3.
3. Glendor U, Marcenes W and Andreasen JO (2007). Classification, epidemiology and etiology. In: Andreasen JO, Andreasen FM and Andersson L (eds.), *Textbook and Color Atlas of Traumatic Injuries to the Teeth*. 4th ed. Copenhagen, Denmark: Blackwell-Munksgaard, pp. 217-244.
4. Andreasen FM, Andreasen JO. C In: *Textbook and color atlas of traumatic injuires to the teeth*. Andreasen FM, Andreasen JO. Mosby Co. Denamark, p:151-79,1994.
5. Keçeci AD. Sporcularda dental travma. *Egzersiz* 2007,1:6-15.
6. Villat C, Machtou P, Naulin-Ifi C. Multidisciplinary approach to the immediate esthetic repair and long-term treatment of an oblique crown-root fracture. *Dent Traumatol* 2004;20:56-60.
7. Koparal E, Ilgenli T. Reattachment of a subgingivally fractured central incisor tooth fragment: report of a case. *J Clin Pediatr Dent* 1999;23:113-6.
8. Leroy RLRG, Asp JKM, Raes FM, Martens LC, De Boever JA. A multidisciplinary treatment approach to a complicated
9. Meiers JC, Freilich MA. Chairside prefabricated fiberreinforced resin composite fixed partial dentures. *Quintessence Int* 2001;32:99-104.
10. Olsburgh S, Jacoby T, Krejci I. Crown fracture in the permanent dentition: pulpal and restorative considerations. *Dent Traumatol* 2002;18:103-15.
11. *Application of the International Classification of Diseases to Dentistry and Stomatology IDC-DA*, 3rd edn. Geneva: WHO, 1995.
12. Andreasen JO, Andreasen FM. Classification, etiology and epidemiology of traumatic dental injuries. In: Andreasen JO, Andreasen FM, eds. *Textbook and Color Atlas of Traumatic Injuries to the Teeth*, 3rd edn. Copenhagen: Munksgaard, 1993: 151-177.
13. Andreasen FM, Nore'n JG, Andreasen JO, Engelhardtson S, Lindh-Stro'mberg U. Long-term survival of crown fragment bonding in the treatment of crown fractures. A multicenter clinical study of fragment retention. *Quintessence Int* 1995; 26: 669-681.

14. Cvek M. Endodontic management of traumatized teeth. In: Andreasen JO, Andreasen FM, eds. Textbook and Color Atlas of Traumatic Injuries to the Teeth, 3rd edn. Copenhagen: Munksgaard, 1993: 517-585.
15. Kahnberg K-E. Surgical extrusion of root fractured teeth – a follow-up study of two surgical methods. Endod Dent Traumatol 1988: 45-89.
16. Warfvinge J, Kahnberg K-E. Intraalveolar transplantation of teeth. IV. Endodontic considerations. Swed Dent J 1989: 13: 229-233.
17. Poi WR, Cardoso LC, Castro JCM, Cintra LTA, Gulinelli JL, Lazari JAB. Multidisciplinary treatment approach for crown fracture and crown-root fracture a case report. Dental Traumatology 2007; 23:51-55.
18. Clark JC, Jones JE. Tooth fragments embedded in soft tissue: a diagnostic consideration. Quintessence International 1987; 18: 653-654.
19. Kahnberg KE. Surgical extrusion of root-fractured teeth a follow-up study of two surgical methods. Endod Dent Traumatol 1988;4:85-89.
20. Alaçam T, Nalbant L, Alaçam A. İeri restorasyon teknikleri. Ankara: Polat Yayınları; 1998. s. 66.

İleti im
Mustafa Hayati ATALA
nönü Üniversitesi Di Hekimli Fakültesi
Protetik Di Tedavisi AD, Malatya
hayatiatala@gmail.com