



OLGU SUNUMU/CASE REPORT

Appendix mucinous cystadenoma mimicking a right adnexal mass

Sağ adneksiyel kitleyi taklit eden apendiks müsinöz kistadenomu

Mehmet Tolga Kafadar¹, Bahadır Kösem², Emine Kırtış³, Nermin Köşüş³, Aydın Köşüş³

¹Turgut Özal University Faculty of Medicine Department of General Surgery, ²Department of Anesthesiology and Reanimation, ³Department of Obstetrics and Gynecology, Ankara, Turkey

Cukurova Medical Journal 2016;41(3):570-572.

Abstract

Appendix mucocoele is a mass formed by the dilatation of appendix lumen due to abnormal mucinous secretions. It develops as a result of epithelial proliferation, mucinous secretion, and luminal dilatation on the background of mucosal hyperplasia, mucinous cystadenoma, or mucinous cystadenocarcinoma. Appendix mucinous cystadenoma is the most common type that may have different clinical presentations. The preoperative diagnosis remains difficult and the pathology is usually detected during laparotomy. Despite concerns about the rupture risk of appendix mucocoeles, laparoscopic surgery has been increasingly used for its treatment. Perforation of a lesion and spread of its contents into abdominal cavity produces a condition known as pseudomyxoma peritonei. In this paper we report a case of 75-year-old woman who was taken to the operating room to be operated for a right adnexial mass and but ultimately underwent laparoscopic appendectomy after detecting an appendix mucocoele in laparoscopic exploration.

Key words: Appendix, laparoscopic appendectomy, mucocoele

Öz

Apendiks mukoseli anormal müsinöz sekresyonlara bağlı apendiks lümeninin dilatasyonu ile oluşan kitledir. Mukosel, mukozal hiperplazi, müsinöz kistadenoma veya müsinöz kistadenokarsinoma şeklinde epitelyal proliferasyon, müsinöz sekresyon ve lümenal dilatasyon sonucunda oluşur. Apendiks müsinöz kistadenomu en sık görülen şekli olup, farklı klinik tablolarla kendini gösterebilir. Preoperatif tanısı zordur ve genellikle laparotomi sırasında tespit edilir. Rüptür riskinden dolayı mevcut endişelere rağmen, tedavide laparoskopik cerrahi giderek artan sıklıkla uygulanmaktadır. Lezyonun perforasyon ve içeriğinin peritoneal kaviteye yayılması sonucu psödomiksoma peritonei oluşabilir. Bu yazıda, sağ adneksiyel kitle ön tanısıyla ameliyata alınan ve laparoskopik eksplorasyonda apendiks mukoseli izlenmesi üzerine laparoskopik apendektomi yapılan 75 yaşında kadın bir olgu sunulmuştur.

Anahtar kelimeler: Apendiks, laparoskopik apendektomi, mukosel

INTRODUCTION

Appendix mucocoele is a rare appendiceal lesion characterized by the dilatation of appendiceal lumen by abnormal mucus collection. It lacks a typical clinical course and its preoperative diagnosis is challenging. Thus, it is usually diagnosed coincidentally during an operation performed for other indications¹. Herein, we report a case of a 75-year-old woman with appendix mucinous cystadenoma who was operated with the laparoscopic method with a discussion of the relevant literature.

CASE

A 75-year-old woman presented to the Obstetrics and Gynecology Clinic with pain that started from the right lower abdominal quadrant 1 month ago and extended to the right groin region. On physical examination she had no pathological sign except for tenderness in the right lower quadrant. Her laboratory examinations showed the following results: WBC: 7100/mm³, Hb: 12.6 g/dL, CA-125: 6.4 U/mL, CEA: 4.2 ng/mL; all other laboratory tests were normal. An ultrasonographic examination performed by a gynecologist revealed a cystic

Yazışma Adresi/Address for Correspondence: Dr. Mehmet Tolga Kafadar, Turgut Özal University Faculty of Medicine, Department of General Surgery, Ankara, Turkey. E-mail: drtolgakafadar@hotmail.com
Geliş tarihi/Received: 12.11.2015 Kabul tarihi/Accepted: 04.01.2016

formation measuring 61x34 mm that had a dense content and partial areas of echogenic material in its lumen. In addition, there was also minimal paraovarian free fluid.

Based on these findings, a gynecological surgical team performed a diagnostic laparoscopy and observed bilaterally normal adnexes and uterus. There was, however, a mass presumably of mesenteric origin. These finding prompted surgeons to consult the case with the general surgery department intraoperatively. The general surgery operative team made an abdominal exploration,

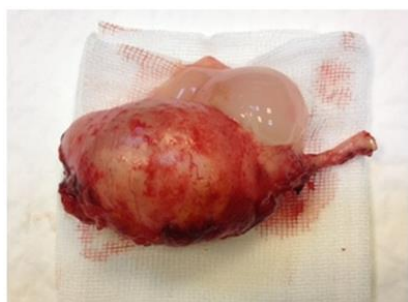

Figure 1. The macroscopic appearance of a mucocoele that was unpacked outside the abdomen.

which spotted a mass with a size of 6x4 cm originating from the appendix at the lateral aspect of the caecum; the mass was considered to be a mucocoele.

A laparoscopic appendectomy operation was performed from the same trocar site. The excised piece was removed without being ruptured from the trocar site at the umbilicus (Figure 1). The patient was discharged with full recovery 2 days later. A histopathological examination revealed that the lesion was an appendix mucocoele with no invasion of surrounding tissues (Figure 2).

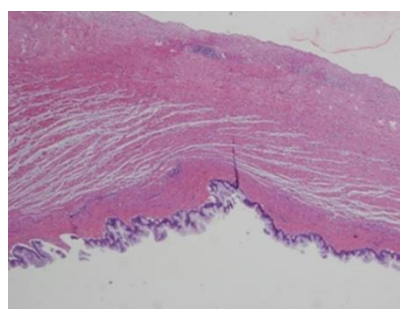


Figure 2. This photomicrograph show that cystic wall of the appendix lining by stratified columnar mucinous epithelium, gross examination revealed cytic appendix tissue full filled by mucin (HEX40)

DISCUSSION

Appendix mucocoele is a cystic dilatation of appendix lumen that occurs as a result of mucus collection. Formerly, it used to be considered to originate from luminal obstruction due to fecaliths or inflammation; however, subsequent histopathological studies have revealed that neoplastic changes in appendix mucosa lead to mucocoele. These lesions have been histologically classified as mucosal hyperplasia, mucinous cystadenoma, and mucinous cystadenocarcinoma².

It has been reported that appendix mucocoele is encountered in 0,2-0,3% of all appendectomy materials³. Patients are generally over the age of 50, and lesions tend to appear 4 times more commonly in women than men. Approximately 25-30% of affected patients are asymptomatic, who are coincidentally diagnosed by radiological examinations, during endoscopic procedures, or surgery. In symptomatic patients, the most common pattern of presentation is acute or chronic lower right abdominal quadrant pain⁴. In about half of

affected persons a mass is palpable in the right lower abdominal quadrant. There may also be nausea, vomiting, or irregular defecation habits⁵. Our patient was ultimately diagnosed by laparoscopic examination performed for the finding of a right adnexial mass upon the intensification of her pain at the right lower abdominal quadrant that intermittently persisted for 1 month.

It is difficult to make the diagnosis of an appendix mucocoele owing to its non-specific presentation. It is usually diagnosed by imaging modalities. On ultrasonography, it appears as an encapsulated, well-demarcated lesion adjacent to caecum, which contains onion skin-like layers and echogenicities in its internal structure⁶. On abdominal tomography it may appear as a round, low-density, thin-walled, encapsulated mass adjacent to caecum⁷. Appendix mucocoele may accompany concurrent neoplasias, most commonly colonic neoplasia. Ovarian, cystic, renal, mammarian, and thyroidal neoplasias can also be found. A study reported that appendix mucocoele co-occurred with colon adenocarcinoma in 19,5-% to 25,4% of the cases⁸. Therefore, cases with

appendix mucocele should be thoroughly examined for a simultaneous colonic neoplasm. Although we did not find any sign of a colonic neoplasm in laparoscopic exploration, we recommended the patient a colonoscopic examination to be performed one month later.

Appendix mucocele is surgically treated. Surgical excision can be performed by laparoscopy or laparotomy. It is imperative to avoid manipulations that would cause cyst rupture or leakage of cyst content. An inadvertent cyst rupture may result in pseudomyxoma peritonei. Strikingly, 5-year survival rate of pseudomyxoma peritonei drops to 20% when the underlying pathology is a cystadenocarcinoma⁹. While some authors object to laparoscopic mucocele operation due to associated risk of pseudomyxoma peritonei, some others have advocated that this operation can be successfully performed laparoscopically. Standard appendectomy alone suffices for the treatment of benign mucocele¹⁰.

In our case, the surgical exploration started by gynecologists with the laparoscopic method was continued and finished with the same method. Mucocele was excised with care without rupturing or causing any leakage of its content into abdominal cavity. As the exact pathological diagnosis was unknown and no sign of the invasion of surrounding tissues was evident, appendectomy alone was performed and the operation finished, with a plan of a future surgery depending on the pathology result.

In conclusion, appendix mucocele has no specific clinical presentation. It should be remembered in differential diagnosis when a mass with atypical appearance is detected by imaging modalities in right iliac fossa, particularly in elderly woman. A careful laparoscopic excision following diagnostic laparoscopy may be a good option. Care should be taken not to spill mucocele content into abdominal

cavity. The possibility of a simultaneous colonic neoplasia should always be kept in mind and appropriate investigations should be undertaken.

REFERENCES

1. Shukunami K, Kaneshima M, Kotsuji F. Preoperative diagnosis and radiographic findings of a freely movable mucocele of the vermiform appendix. *Can Assoc Radiol J.* 2000;51:281-2.
2. Rampone B, Roviello F, Marrelli D, Pinto E. Giant appendiceal mucocele: Report of a case and brief review. *World J Gastroenterol.* 2005;11:4761-3.
3. Carr NJ, Mc Carthy WF, Sobin LH. Epithelial noncarcinoid tumors and tumor-like lesions of the appendix: a clinicopathologic study of 184 patients with a multivariate analysis of prognostic factors. *Cancer.* 1995;75:757-68.
4. Minni F, Petrella M, Morganti A, Santini D. Giant mucocele of the appendix. *Dis Colon Rectum.* 2001;44:1034-6.
5. Coulier B, Pesticau S, Hamels J, Lefebvre Y. US and CT diagnosis of complete cecocolic intussusception caused by an appendiceal mucocele. *Eur Radiol.* 2002;12:324-8.
6. Caspi B, Cassif E, Auslender R, Herman A, Hagay Z, Appelman Z. The onion skin sign: a specific sonographic marker of appendiceal mucocele. *J Ultrasound Med.* 2004;23:117-21.
7. Pickhardt PJ, Levy AD, Rohrmann CA Jr, Kende AI. Primary neoplasms of the appendix: radiologic spectrum of disease with pathologic correlation. *Radiographics.* 2003;23:645-62.
8. Pitiakoudis M, Tsaroucha AK, Mimidis K, Polychronidis A, Minopoulos G, Simopoulos C. Mucocele of the appendix: a report of five cases. *Tech Coloproctol.* 2004;8:109-12.
9. Chiu CC, Wei PL, Huang MT, Wang W, Chen TC, Lee WJ. Laparoscopic resection of appendiceal mucinous cystadenoma. *J Laparoendosc Adv Surg Tech A.* 2005;15: 325-8.
10. Rangarajan M, Palanivelu C, Kavalakat AJ, Parthasarathi R. Laparoscopic appendectomy for mucocele of the appendix: report of 8 cases. *Indian J Gastroenterol.* 2006;25:256-7.