

# A comparison of clinical results of transtibial and transportal anatomical techniques in the arthroscopic reconstruction of anterior cruciate ligament

Alim Can Baymurat<sup>1</sup> , Mesut Tahta<sup>2</sup> , Nazmi Uysal<sup>3</sup> ,

1 Gazi University Faculty of Medicine, Department of Orthopedics and Traumatology, Ankara, Turkey

2 Egepol Surgery Hospital, İzmir, Turkey

3 Menemen State Hospital, İzmir, Turkey

## Abstract

**Background:** The present study aims to compare the clinical outcomes of patients who underwent arthroscopic anterior cruciate ligament (ACL) reconstruction with Transtibial (TT) and Transportal Anatomical (TA) techniques with the diagnosis of ACL rupture.

**Methods:** A total of 56 patients who underwent arthroscopic ACL repair in the Orthopedics and Traumatology Clinic of Menemen State Hospital between 2015 and 2020 were included in the study. The mean age of the patients was 25 years, and follow-up period was 31 months. Of the patients, 53 were male, 3 were female, and 43 had ACL ruptures in the right knee and 13 in the left knee. ACL reconstruction was performed using the TT technique in 29 patients and the TA technique in 27 patients. Patients were evaluated using the Lysholm Assessment score, the Modified Cincinnati Rating System Questionnaire, the Tegner Activity Level Scale, and the International Knee Documentation Committee scoring.

**Results:** There was a significant difference in pre and postoperative controls ( $p < 0.05$ ) and while normal and near-normal results were obtained with the TT (89%) and TA (87%) techniques, there was no statistically significant difference between the two techniques when the postoperative data were compared ( $p > 0.05$ ).

**Conclusions:** In this study, there was no significant difference between the two techniques in terms of clinical outcome and patient satisfaction. Although there are studies in the literature showing that the TA technique is superior in terms of knee stability, good results are obtained with both techniques.

**Keywords:** Anterior Cruciate Ligament, Transtibial, Transportal Anatomical, Femoral Tunnel.

*Cite this article as:* Baymurat AC, Tahta M, Uysal N. A comparison of clinical results of transtibial and transportal anatomical techniques in the arthroscopic reconstruction of anterior cruciate ligament. Arch Curr Med Res. 2022;3(1):18-23

## Corresponding Author:

Alim Can Baymurat, Gazi University Medical Faculty, Department of Orthopedics and Traumatology, Ankara, Turkey  
E-mail: alimcanbaymurat@yahoo.com



Content of this journal is licensed under a Creative Commons Attribution-NonCommercial 4.0 International License.

## INTRODUCTION

The anterior cruciate ligament (ACL) is the primary stabilizer that limits the anterior translation of the tibia from the femur and has a mechanical function to prevent tibial torsion, valgus, and varus stresses (1,2). Due to its important function in knee kinematics, ACL insufficiency causes instability, pain and osteoarthritis in the knee, resulting in deterioration of the patient's quality of life (3,4). The success of ACL reconstruction depends on patient selection, surgical technique, and post-operative rehabilitation.

While the opening of the tibial tunnel in single-bundle arthroscopic reconstruction surgery in anterior cruciate ligament ruptures are the same in both transtibial and transportal anatomical methods, the opening of the femoral tunnel in both methods are different. In the transtibial technique, the femoral guide is passed through the tibial tunnel and placed on the medial surface of the lateral femoral condyle. The femoral tunnel is opened at 10:30 in the right knee and at 1:30 in the left knee, leaving 1-2 mm of the posterior cortex. In the transportal anatomical method, the femoral tunnel is opened using the medial portal or the accessory medial portal. The femoral guide is passed through the medial or medial accessory portal, and the femoral tunnel is opened from the anatomical attachment of the anterior cruciate ligament on the medial surface of the lateral femoral condyle.

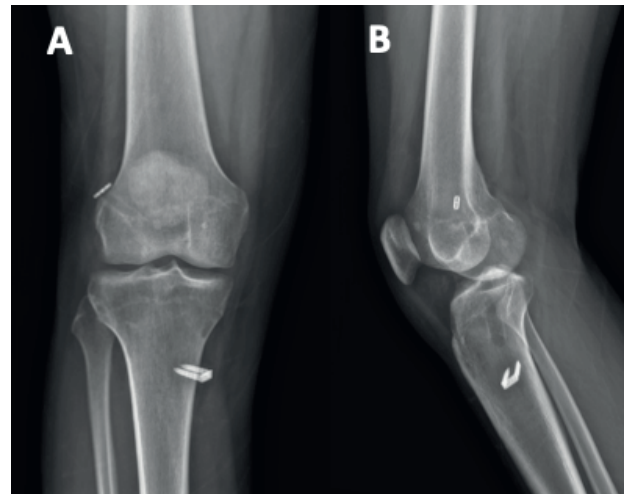
In terms of surgical technique, transtibial and transportal anatomical techniques are commonly used to open the femoral tunnel (5-7). The transtibial technique has been used by orthopedic surgeons for many years, and good results have been reported (8-10). However, there are also studies stating that the transtibial (TT) technique is not anatomical and does not provide rotational stability (11-14). The transportal anatomical (TA) technique, also known as the anteromedial technique, is the technique adopted and widely used by orthopedic surgeons. Various studies have shown that the anteromedial technique provides better knee stability (15-18). There are also studies in the literature showing that there is no statistically significant difference between TT and TA techniques (19-21).

This study aims to compare the clinical outcomes of patients who underwent ACL reconstruction using transtibial and transportal anatomical techniques with the diagnosis of ACL rupture and to determine whether the two techniques have any superiority over each other.

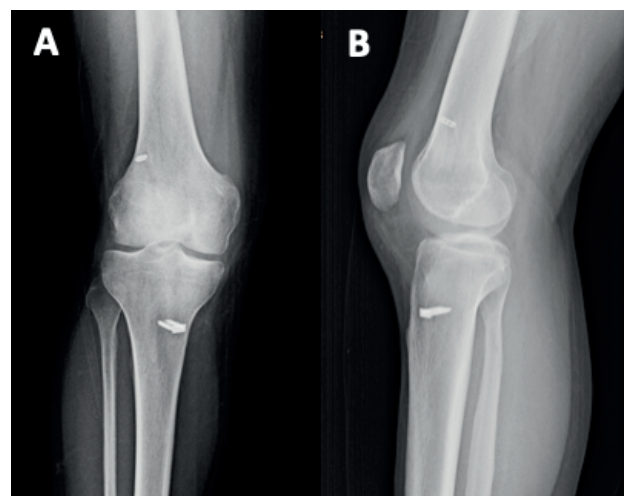
## MATERIALS AND METHODS

Between January 2015 and September 2020 74 patients with the diagnosis of anterior cruciate ligament rupture underwent arthroscopic ACL reconstruction in the Department of Orthopedics and Traumatology of Menemen State Hospital. A total of 56 patients with adequate follow-up period were included in the study. Arthroscopic ACL repair was performed using autogenous hamstring tendon graft with the transtibial technique in 29 (52%) patients and the transportal anatomical technique in 27 (48%) patients (Figure 1, 2). The mean follow-up period of the patients was 31 (6 – 68) months.

**Figure 1. ACL reconstruction with transportal anatomical technique. (Postoperative anteroposterior (A) and lateral (B) X-Ray view)**



**Figure 2. ACL reconstruction with transportal anatomical technique. (Postoperative anteroposterior (A) and lateral (B) X-Ray view)**



The ethics committee approval was received for this study from the Ethics Committee of Izmir University of Health Sciences Tepecik Training and Research Hospital (Date: 17/05/2021. No: 2021/05-28). Of the patients treated with the TT technique, 27 (93%) were male and 2 (7%) were female. 21 (72%) patients had ACL rupture in the right knee and 8 (28%) in the left knee. The mean age was 25 (17-39) years. Of the patients treated with the TA technique, 26 (92%) were male and 1 (8%) was female. Twenty (74%) patients had ACL rupture in the right knee and 7 (26%) in the left knee. The mean age was 26 (18 -40) years (Table 1). The diagnosis was made according to the clinical examination and MRI findings of the patients.

**Table 1. Patients demographics and baseline information.**

	Transtibial	Transportal Anatomical
Number of patients	29 (%52)	27 (48%)
Age (years)	25 (17-39)	26 (18-40)
Male/Female	27 (93%) / 2 (7%)	21 (72%) / 8 (28%)
Right / left	21 (72%) / 8 (28%)	20 (74%) / 7 (26%)
Follow-up periods (month)	31 (6-68)	31 (6-68)

All patients were given 1 g first generation cephalosporin antibiotic prophylactically one hour before the operation. The graft removal and reconstruction were performed after the ACL rupture was arthroscopically confirmed.

Lysholm score, Tegner Activity Level score, Modified Cincinnati evaluation questionnaire and International Knee Documentation Committee (IKDC) evaluation form were filled in by all patients before the surgery and at the final checks.

All pre- and postoperative data of the patients in the study were recorded and statistical analyses were performed using the IBM SPSS Statistics 22.0 program. Significance level was accepted as  $p=0.05$ . The conformity of the variables to the normal distribution was tested with the Shapiro-Wilk test. Variables that did not fit the normal distribution were given with median (minimum-

maximum) values, and the Mann-Whitney U test was used for comparisons between two independent groups, and the Wilcoxon test was used for comparison of two dependent groups. Categorical variables were given with frequency and percentage values ( $n$  (%)), and the Fisher's Exact Test and the McNemar-Bowker test were used for comparisons.

This study was approved by the clinical research ethics committee of the Health Sciences University Tepecik Training and Research Hospital (Date: 17.05.2021 number: 2021/05-28) and written consent was obtained from all patients participating in the study.

## RESULTS

A significant difference was observed in the pre- and postoperative Tegner activity scores, Modified Cincinnati and Lysholm scores of the patients who underwent ACL reconstruction with the transtibial technique ( $p<0.05$ ). Postoperative Tegner activity level, Modified Cincinnati and Lysholm scores were higher than preoperative scores (Table 2).

**Table 2. Investigation of Tegner activity levels and Modified Cincinnati and Lysholm Scores before and after surgery in patients who underwent ACL reconstruction with the transtibial technique**

	Before	After	Significance (p)
	Median (Min-Max)	Median (Min-Max)	
Tegner Activity Score	2(1-3)	7(5-8)	<0.001
Modified Cincinnati Score	40(16-50)	85(67-96)	<0.001
Lysholm Score	38(14-50)	85(68-95)	<0.001
<i>p&lt;0.05, Wilcoxon Signed-Rank Test</i>			

There is a significant difference between IKDC scores in the transtibial technique ( $p<0.05$ ). Patients treated with the transtibial technique show improvement in their postoperative IKDC scores compared to preoperative scores. (Table 3)

**Table 3. Preoperative and postoperative IKDC scores of patients who underwent ACL reconstruction with the transtibial technique**

Before	After				Significance (p)
	A	B	C	D	
A	0	0	0	0	0.010
B	1	2	0	0	
C	9	3	3	0	
D	7	3	1	0	

*p*<0.05, McNemar-Bowker Test

(IKDC grade: A – normal, B – nearly normal, C – Abnormal, D – severely abnormal)

Preoperative and postoperative Tegner activity, Modified Cincinnati and Lysholm scores of patients who underwent ACL reconstruction with the transportal anatomical technique differ (*p*<0.05). Postoperative Tegner activity score, Modified Cincinnati and Lysholm scores of patients who underwent ACL reconstruction with the transportal anatomical technique were higher than preoperative scores. (Table 4)

**Table 4. Preoperative and postoperative Tegner Activity Level, Modified Cincinnati and Lysholm Scores in patients who underwent ACL reconstruction with the transportal anatomical (TA) technique**

	Before	After	Significance (p)
	Median (Min-Max)	Median (Min-Max)	
Tegner Activity Score	2(1-3)	7(5-8)	<0.001
Modified Cincinnati Score	42(30-53)	84(73-96)	<0.001
Lysholm Score	42(31-55)	85(68-96)	<0.001

*p*<0.05, Wilcoxon Signed-Rank Test

There is a significant difference between the preoperative and postoperative IKDC scores of patients who underwent ACL reconstruction with the transportal anatomical technique (*p*<0.05). Patients undergoing ACL reconstruction with the transportal anatomical technique show an improvement in their postoperative IKDC scores compared to preoperative scores. (Table 5)

**Table 5. Preoperative and postoperative IKDC scores of patients undergoing ACL reconstruction with the transportal anatomical technique**

Before	After				Significance (p)
	A	B	C	D	
A	0	0	0	0	0.004
B	4	0	0	0	
C	8	4	2	0	
D	5	3	1	0	

*p*<0.05, McNemar-Bowker Test

(IKDC grade: A – normal, B – nearly normal, C – Abnormal, D – severely abnormal)

There was no significant difference between transtibial and transportal anatomical techniques in terms of postoperative Tegner activity score, Modified Cincinnati and Lysholm scores (*p*>0.05). (Table 6)

**Table 6. Postoperative Tegner activity level, Modified Cincinnati and Lysholm Scores of the Groups Included in the Study**

	Post-operation		Significance (p)
	Transtibial	Transportal	
Tegner Activity Score	7(5-8)	7(5-8)	0.770
Modified Cincinnati Score	85(67-96)	84(73-96)	0.980
Lysholm Score	85(68-95)	85(68-96)	0.667

*P*<0.05, Mann-Whitney U Test

There was no significant difference between the postoperative IKDC scores of patients who underwent ACL reconstruction with transtibial and transportal anatomical techniques (*p*>0.05). (Table 7)

**Table 7. Postoperative IKDC Scores of the Groups Included in the Study**

Postoperative IKDC Score	Transtibial	Transportal	Significance (p)
A	17(58.6)	17(63)	1.000
B	8(27.6)	7(25.9)	
C	4(13.8)	3(11.1)	
D	0(0)	0(0)	

*p*<0.05, Fisher's Exact Test

(IKDC grade: A – normal, B – nearly normal, C – Abnormal, D – severely abnormal)

## DISCUSSION

The ACL is the most injured ligament of the knee joint, and about 70% of tears occur during sports activities. Its incidence in the general population is approximately 1 in 3000 (22). Ligament reconstruction is widely used because of the low success rate in the conservative treatment of ACL injuries (23). The main goals of ACL reconstruction are to restore knee stability, restore pre-injury sports ability to the patient, and prevent joint degeneration in the long term (24-26). Transtibial and transportal anatomical techniques in ACL reconstruction are generally accepted by orthopedic surgeons, although debates continue regarding their superiority over each other (25,27,28). The success of ACL reconstruction surgery depends on many factors. Transtibial and transportal anatomical techniques are commonly used treatment modalities in ACL reconstruction (5-7).

In the present study, normal and near-normal results were obtained at a rate of 89% in the IKDC scores in ACL reconstruction performed with the transtibial technique, while this rate was 87% with the transportal anatomical technique. There was no statistically significant difference between the two techniques. There was no significant difference between transtibial and transportal anatomical techniques in terms of postoperative Tegner activity score, Modified Cincinnati and Lysholm scores.

Good results have been obtained for many years with the transtibial technique (8-10). It has been shown that the transtibial technique can generally lead to anteriorly located femoral tunnels (11,12,29). Kopf et al. suggested that although the transtibial technique prevents anterior translation of the knee, it does not provide rotational stability (30). Hefzy et al. reported that the most important cause of ACL graft failure is non-anatomical tibial and femoral tunnel location (31). There are studies showing that better results are obtained in terms of knee stability and functionality with the anatomical technique (15-18). Transportal drilling is considered the best option for anatomical placement of the ACL graft into the femur (32). Silva et al. stated that the anatomical technique placed the femoral and tibial tunnels in the center of the ACL footprint and provided better anteroposterior and rotational stability of the knee joint (29). Mirzatoeloei et al. reported that the transportal anatomical technique achieved better short-term clinical results compared to the transtibial technique in ACL reconstruction (33). Alentorn-

Geli et al. found a statistically significant difference in favor of the anatomical technique in their study including 1–2-year follow-up period. They reported that this was due to the more anatomical placement of the graft on the femoral side, but this difference was not observed between anatomical and transtibial techniques at 3-5 years and 6-10 years of follow-up (12). Metso et al. reported that there was no significant difference between the anteromedial and transtibial techniques in terms of maintaining knee stability (34). Jinzhong Zhao stated that an anatomical femoral tunnel will be created when the tibial tunnel is opened in accordance with the sagittal plane and tibial axis during the creation of the tibial tunnel (35, 36).

The limitations of our study are that it is retrospective, the number of patients included in the study is low, and there is no control group.

In conclusion, placement of the graft in accordance with the anatomy and tension, and fixation of the graft provide anterior-posterior and rotational stability of the knee joint in anterior cruciate ligament reconstruction. Although there are studies in the literature showing that the transportal anatomical technique is superior in knee stability, good results are obtained with both techniques. According to current study, it was considered that it could be achieved satisfactory results regardless to the technique if the tibial and femoral tunnels were opened appropriately according to the anatomy and the tension of the tendon graft.

### Declarations

The authors received no financial support for the research and/or authorship of this article. There is no conflict of interest.

This study was approved by the clinical research ethics committee of the Health Sciences University Tepecik Training and Research Hospital (Date: 17.05.2021 number: 2021/05-28) and written consent was obtained from all patients participating in the study.

### REFERENCES

1. Woo SLY, Fox RJ, Sakane M, Livesay GA, Rudy TW, Fu FH. Biomechanics of the ACL: Measurements of in situ force in the ACL and knee kinematics. *The Knee*. 1998;5:267-288.
2. Zantop T, Petersen W, Sekiya JK, Musahl V, Fu FH; Anterior cruciate ligament anatomy and function relating to anatomical reconstruction. *Knee Surg Sports Traumatol Arthrosc*. 2006;982-92.

3. Gillquist J, Messner K. Anterior cruciate ligament reconstruction and the long-term incidence of gonarthrosis. *Sports Med* 1999;27:143-56.
4. Lohmander LS, Englund PM, Dahl LL, Roos EM. The long-term consequence of anterior cruciate ligament and meniscus injuries: osteoarthritis. *Am J Sports Med* 2007;35:1756-69.
5. Ahn JH, Jeong HJ, Ko CS, Ko TS, Kim JH. Three-dimensional reconstruction computed tomography evaluation of tunnel location during single-bundle anterior cruciate ligament reconstruction: a comparison of transtibial and 2-incision tibial tunnel-independent techniques. *Clin Orthop Surg*. 2013;5:26–35
6. Shin YS, Ro KH, Lee JH, Lee DH. Location of the femoral tunnel aperture in single-bundle anterior cruciate ligament reconstruction: comparison of the transtibial, anteromedial portal, and outside-in techniques. *Am J Sports Med*. 2013;41:2533–9.
7. Riboh JC, Hasselblad V, Godin JA, Mather RC III. Transtibial versus independent drilling techniques for anterior cruciate ligament reconstruction: a systematic review, meta-analysis, and meta-regression. *Am J Sports Med*. 2013;41:2693–702.
8. Smith F, Rosenlund E, Aune A, MacLean J, and Hillis S. Subjective functional assessments and the return to competitive sport after anterior cruciate ligament reconstruction. *Br J Sports Med*. 2004;38:279–284.
9. Lee DYH , Karim SA, Chang HC. Return to sports after anterior cruciate ligament reconstruction - a review of patients with minimum 5-year follow-up. *Ann Acad Med Singap*. 2008;37:273-8.
10. Jinzhong Zhao. Anatomical single-bundle transtibial anterior cruciate ligament reconstruction. *Arthrosc Tech*. 2020;29:1275-1282.
11. Guglielmetti LG, Cury Rde P, de Oliveira VM, de Camargo OP, Severino NR, Fucs PM. Anterior cruciate ligament reconstruction: a new cortical suspension device for femoral fixation with transtibial and transportal techniques. *J Orthop Surg Res*. 2014;9:110.
12. Alentorn-Geli E, Lajara F, Samitier G, Cugat R. The transtibial versus the anteromedial portal technique in the arthroscopic bone-patellar tendon-bone anterior cruciate ligament reconstruction. *Knee Surg Sports Traumatol Arthrosc*. 2010;18:1013–37.
13. Yau WP, Fok AW, Yee DK. Tunnel positions in transportal versus transtibial anterior cruciate ligament reconstruction: a case-control magnetic resonance imaging study. *Arthroscopy*. 2013;29:1047–52.
14. Kopf S, Forsythe B, Wong AK, Tashman S, Irrgang JJ, Fu FH. Transtibial ACL reconstruction technique fails to position drill tunnels anatomically in vivo 3D CT study. *Knee Surg Sports Traumatol Arthrosc*. 2012;20:2200–7.
15. Song EK, Kim SK, Lim HA, Seon JK. Comparisons of tunnel-graft angle and tunnel length and position between transtibial and transportal techniques in anterior cruciate ligament reconstruction. *Int Orthop*. 2014;38:2357–62.
16. Mandal A, Shaw R, Biswas D, Basu A. Transportal versus transtibial drilling technique of creating femoral tunnel in arthroscopic anterior cruciate ligament reconstruction using hamstring tendon autograft. *J Indian Med Assoc*. 2012;110:773–5.
17. Brown CH Jr, Spalding T, Robb C. Medial portal technique for single-bundle anatomical anterior cruciate ligament (ACL) reconstruction. *Int Orthop*. 2013;37:253–69.
18. Haitao Chen, Kai Tie, Yongjian Qi, Bin Li, Biao Chen, Liaobin Chen. Anteromedial versus transtibial technique in single-bundle autologous hamstring ACL reconstruction: a meta-analysis of prospective randomized controlled trials. *J Orthop Surg Res*. 2017;12:167
19. Azboy I, Demirtas A, Gem M, Kiran S, Alemdar C, Bulut M. A comparison of the anteromedial and transtibial drilling technique in ACL reconstruction after a short-term follow-up. *Arch Orthop Trauma Surg*. 2014;134:963–9.
20. Tasdemir Z, Gulabi D, Saglam F, Tokgoz Ozal S, Elmali N. Does the anteromedial portal provide clinical superiority compared to the transtibial portal in anterior cruciate ligament reconstruction in nonprofessional athletes in short-term follow-up? *Acta Orthop Traumatol Turc*. 2015;49:483–491.
21. Ozel O, Yucel B, Orman O, Demircay E, Mutlu S. Comparison of anteromedial and transtibial ACL reconstruction using expandable fixation. *Orthopedics*. 2017;1;40:532-537
22. Sisk TD. Knee Injuries. In: *Campbell's Operative Orthopaedics*, 1996;8:1487–732.
23. Krause M, Freudenthaler F, Frosch KH, Achtnich A, Petersen W, Akoto R. Operative Versus Conservative Treatment of Anterior Cruciate Ligament Rupture. *Dtsch Arztebl Int*. 2018;24;115:855-862
24. Tashman S, Araki D. Effects of ACL reconstruction on in vivo, dynamic knee function. *Clin Sports Med*. 2013;32:47–59.
25. Tie K, Chen L, Hu D, Wang H. The difference in clinical outcome of single-bundle anterior cruciate ligament reconstructions with and without remnant preservation: A meta-analysis. *Knee*. 2016;23:566–74.
26. Kilinc BE, Kara A, Oc Y, Celik H, Camur S, Bilgin E. et al. Transtibial vs anatomical single bundle technique for anterior cruciate ligament reconstruction: A retrospective cohort study. *Int J Surg*. 2016;29:62–9
27. Kyung HS, Baek SG, Lee BJ, Lee CH. Single-bundle anterior Cruciate ligament reconstruction with semitendinosus tendon using the PINN-ACL crosspin system: minimum 4-year follow-up. *Knee Surg Relat Res*. 2015;27:43–48
28. Zhang Y, Xu C, Dong S, Shen P, Su W, Zhao J. Systemic review of anatomic single- versus double-bundle anterior cruciate ligament reconstruction: does femoral tunnel drilling technique matter? *Arthroscopy*. 2016;32:1887–904.
29. Silva A, Sampaio R, Pinto E. ACL reconstruction: comparison between transtibial and anteromedial portal techniques. *Knee Surg Sports Traumatol Arthrosc*. 2012;20:896–903.
30. Kopf S, Forsythe B, Wong AK, Tashman S, Anderst W, Irrgang JJ, et al. Nonanatomic tunnel position in traditional transtibial single bundle anterior cruciate ligament reconstruction evaluated by three-dimensional computed tomography. *J Bone Joint Surg Am*. 2010;92:1427–31
31. Hefzy MS, Grood ES, Noyes FR. Factors affecting the region of most isometric femoral attachments. Part II: The anterior cruciate ligament. *Am J Sports Med*. 1989;17:208-16.
32. Silver AG, Kaar SG, Grisell MK, Reagan JM, Farrow LD. Comparison between rigid and flexible systems for drilling the femoral tunnel through an anteromedial portal in anterior cruciate ligament reconstruction. *Arthroscopy*. 2010;26:790-5
33. Mirzatoloei F. Comparison of short term clinical outcomes between transtibial and transportal TransFix(R) femoral fixation in hamstring ACL reconstruction. *Acta Orthop Traumatol Turc*. 2012;46:361–366.
34. Metso L, Nyrhinen KM, Bister V, Sandelin J, Harilainen A. Comparison of clinical results of anteromedial and transtibial femoral tunnel drilling in ACL reconstruction. *BMC Musculoskeletal Disord*. 2020;21:341.
35. Jinzhong Zhao. Anatomical Single-Bundle Transtibial Anterior Cruciate Ligament Reconstruction. *Arthrosc Tech*. 2020;29:1275-1282.
36. Hatipoğlu MY, Bircan R, Özer H, Selek HY, Harput G, Baltacı YG. Radiographic assessment of bone tunnels after anterior cruciate ligament reconstruction: A comparison of hamstring tendon and bone-patellar tendon-bone autografting technique. *Jt Dis Relat Surg* 2021;32(1):122-128.