

## LEYDIG CELL (INTERSTITIAL CELL) TUMOR (OVERVIEW AND CASE REPORT)

L. Türkeri, M.D. \*\*\*\* / S. Küllü, M.D. \*\* / Y. İlker, M.D. \*\*\* / A. Akdaş, M.D. \*

\* *Professor, Department of Urology, Faculty of Medicine, Marmara University, Istanbul, Turkey.*

\*\* *Associate Professor, Department of Pathology, Faculty of Medicine, Marmara University, Istanbul, Turkey.*

\*\*\* *Assistant Professor, Department of Urology, Faculty of Medicine, Marmara University, Istanbul, Turkey.*

\*\*\*\* *Research Assistant, Department of Urology, Faculty of Medicine, Marmara University, Istanbul, Turkey.*

### SUMMARY

Leydig cell tumors are usually benign in nature, originating from testicular mesenchyme. Endocrinologic manifestations may precede the tumoral mass. Since there are no clear cut differences between the histopathologic appearance of benign and malignant tumors and differential diagnosis can be made only by the presence of metastases, a close follow-up is essential in these tumors.

**Key words:** Leydig cell, benign and malignant tumors

### INTRODUCTION

Leydig cell tumors are the most common type of sex chord mesenchyme lesions and constitute 1.2% to 3% of all testicular neoplasms (1,2,3,4).

Approximately one fourth have been reported before puberty (4), but the majority of cases are between 20-60 years (4).

Histologic features are well described (5, 6), however the ultrastructure of benign and malignant interstitial cell tumors is indistinguishable from normal cells and there are no reliable criteria for making a judgement about malignancy.

Leydig cell tumors are often associated with excess sex steroid production, although clinical symptoms of endocrine disturbance are less commonly reported (6), yet endocrinologic manifestations may occur before a palpable mass in the testis is noticed.

Virilizing types of congenital adrenocortical hyperplasia, Klinefelter's syndrome, and other feminizing testicular disorders should be considered in differen-

tial diagnosis (4).

In this paper we report two similar cases displaying the characteristics of this type of tumor and review the current literature on the aspect.

### CASE REPORT: (1)

A 30-year-old male patient was admitted to Marmara University Hospital, Department of Urology, with the complaints of pain and lump in the left testicle. The pain had begun 2.5 months before the admission when he noticed a mass in his testis at the same time. The severity of the pain had improved with antibiotics and analgesics prescribed by a doctor, but the lump persisted.

On physical examination, the patient had a left testicular mass nearly 5 cm in diameter. He was normal otherwise. There were no manifestation of an endocrinologic abnormality. Serum levels of AFP, Beta-HCG, and also biochemical and hematologic tests were in normal limits. With the diagnosis of a testicular tumor, an immediate left sided inguinal orchiectomy was performed. His postoperative period was uneventful.

Macroscopic examination of the surgical specimen revealed an orange colored tumor, which was 2.5 cm in diameter and extending to tunica albuginea. In microscopic examination, there were neoplastic cells with large, pale, granular cytoplasm, some of them having vacuoles and Reinke crystals. Cells were producing solid masses in a fibrous stroma. The nuclei were small and rounded, displaying mild pleomorphism (Fig. 1, 2). Immunoperoxidase staining of the paraffin embedded tissue slides yielded negative re-

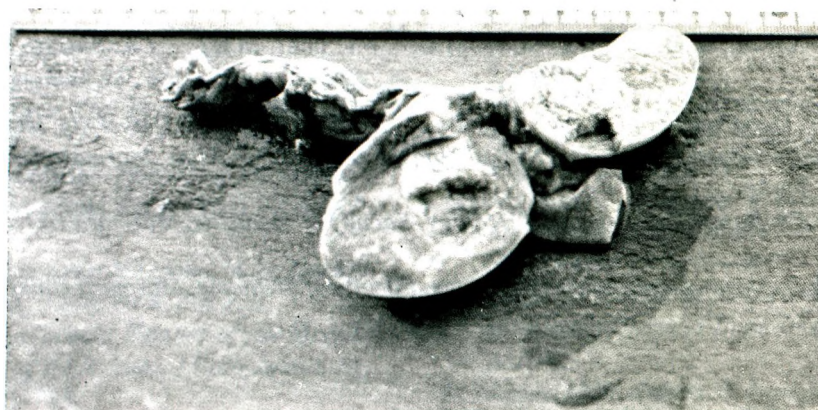

Fig. 1: Macroscopic appearance of the tumor.

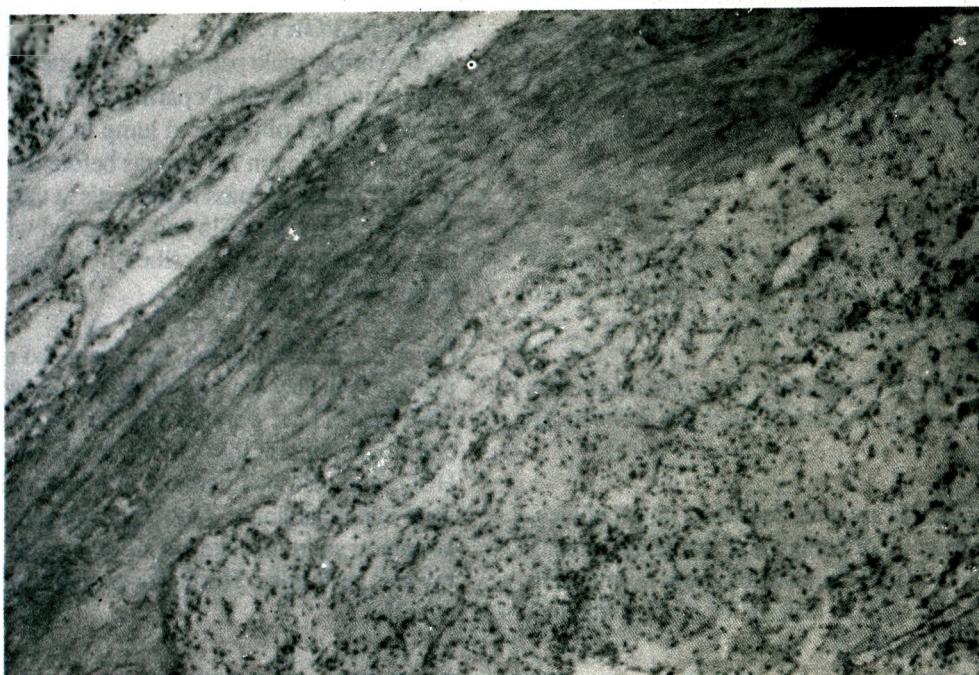


Fig. 2: Microscopic appearance of the tumor.



sults for AFP and Beta-HCG. The tumor with a small necrotic area, was found to be extending to the tunica albuginea. There was no invasion at the surgical margins. With these histologic findings a diagnosis of Leydig cell tumor was instituted.

After the operation the serum levels of FSH, LH, estrogen, testosterone, AFP and Beta-HCG were found to be in normal limits. The chest X-ray, retroperitoneal ultrasonography, and whole body CT scanning examination of the patient revealed normal findings.

As a result, the patient was regarded as having localised disease treated by complete excision of the tumor, and he was entered the surveillance program with monthly follow-ups.

#### CASE REPORT: (2)

A 32-year-old male patient was admitted to our department because of gynecomastia. His complaints had begun in December 1987, when he first noticed a painful left sided gynecomastia. He had been examined by a physician and in laboratory examinations performed elsewhere serum estradiol level was found to be elevated (patient value: 52 pg/mL, normal value: 6-44 pg/mL) and Beta-HCG in normal limits. With these findings a thorough physical examination was repeated and a left sided testicular mass was found which also escaped the attention of the patient. A diagnosis of testicular tumor led to left inguinal orchiectomy.

In macroscopic examination of the surgical specimen there was a well circumscribed, yellow-orange colored, firm lobular tumor in the testis with a diameter of 2 cm. Microscopic examination of the tissue revealed neoplastic cells forming cords and alveolar structures in a stroma which was rich in blood vessels. Tumor cells had round nuclei with large eosinophilic cytoplasm. Some of these cells had double nuclei. There was no invasion at the surgical margins.

With these histologic findings a diagnosis of Leydig cell tumor was instituted.

After the operation the serum levels of estradiol, testosterone, AFP and Beta-HCG were all found in normal limits. Even though it has shown regression to some extent the gynecomastia of the patient had persisted. The chest X-ray, excretory urography, and abdominal ultrasonography of the patient revealed normal findings. Therefore this patient was also regarded as having localised disease and taken into the surveillance program.

#### DISCUSSION

Leydig cells, which are located between the seminiferous tubules develop embryologically from mesenchyme derived from the posterior urogenital ridge and possibly also from coelomic epithelial cells which do not become incorporated in to the tubules (7,8).

The tumors originating from Leydig cells are usually seen between the second and the sixth decade (4), and account for nearly 20% of childhood testis tumors (9).

The tumors are generally small, yellow to brown in color, and well circumscribed. They rarely exhibit hemorrhage and necrosis (4). Microscopically the tumor consists of relatively uniform polygonal cells, producing cords or sheets, with large amounts of eosinophilic granular cytoplasm and nuclei which often contain prominent nucleoli (6). There may be lipid vacuoles, brownish pigmentation and occasional Reinke crystals in the cytoplasm. None of these histologic features appear to be related to malignant potential. Large size, extensive necrosis, marked cellular pleomorphism with bizarre cell forms with atypical nuclei, numerous and atypical mitoses, invasion of vascular and lymphatic channels, extension of the tumor in to the spermatic cord and invasion of the capsule are the prominent features suggestive of malignancy (4, 6, 10-12). Yet there may be considerable overlap between the microscopic features in benign and malignant tumors. Consequently the presence of metastases remains to be the only reliable criteria for malignancy (6). Only 7% to 10% of Leydig cell tumors do metastasize and the metastatic form of this type of tumor occur exclusively in adults (3, 5, 13). Like other testicular tumors malignant lesions may involve retroperitoneal lymph nodes, lungs, bone, liver, kidney and other organs. The most important observation in case of malignancy is almost nonexistence in prepubertal age group (4). Bilateral tumors are also reported in the literature (14).

Leydig cell tumors may be either feminizing or virilizing functionally (15, 16).

When the androgen producing type of tumor occurs in a prepubertal boy, precocious development of penis, beard, and muscles occur along with accelerated linear growth (17). An increased testosterone production is usually demonstrable and urinary 17-ketosteroid output may or may not be elevated (4). Leydig cell tumors that produce feminization are found only

in adult males. Symptoms such as impotence and gynecomastia may occur. Elevation of urinary and plasma estrogens in this type of tumor is relatively common (4).

Evidences of endocrinologic abnormalities due to the tumor may be encountered before a lump in the testis is found.

The similar embryological origin of interstitial cells and adrenocortical cells, and also the occurrence of adrenal rests in the testis may complicate the differential diagnosis. Klinefelter's syndrome, and other feminizing testicular disorders and virilizing types of congenital adrenocortical hyperplasia must be ruled out accordingly in the diagnosis of Leydig cell tumors.

The treatment of this type of tumors is primarily surgical (18). These tumors, in case of malignancy are generally refractory to radiotherapy (11, 19-25) and conventional chemotherapy (3, 10, 12, 18-20, 25). Because of the histologic and biochemical similarities between Leydig cells and adrenal cortical cells, chemotherapy with o,p'DDD(mitotane), which is an adrenolytic agent, have been used for metastatic disease (16, 18, 21, 26). A variety of chemotherapeutic agents including Cis-platinum, vinblastine, bleomycin, cyclophosphamide, doxorubicin and vincristin have been utilised with unpromising results (4). Trials of endocrine therapy based on experimental evidence of estrogen receptors in mouse Leydig cell tumor lines, have been performed with some benefit (27). Inhibition of mitochondrial protein synthesis with arrest of in vivo growth of solid Leydig cell tumors in rats by oxytetracycline has also been reported (28). Lonidamine, a powerful antispermatogenic agent and selective inhibitor of aerobic glycolysis (29) has been suggested to suppress the Leydig cell function and reduce plasma testosterone levels. Yet very few patients had subjective improvement and no patient had any objective response to lonidamine (6). Retroperitoneal lymph node dissection has been recommended as routine in patients whose Leydig cell tumors appear histologically or biochemically malignant.

The prognosis of Leydig cell tumors is good because of their generally benign nature. The persistence of virilizing or feminizing features following orchiectomy is not necessarily an indication of malignancy, since these changes are irreversible to some extent. What seems to be the most important factor in this of particular group of tumors is the late occurrence met-

astasis, which may emerge after a long latent period, as much as 9 years (6). This calls for a close surveillance with great patient compliance for a long period. The average survival time in case of malignancy is about 2-3 years (4), where the patient is cured by radical orchiectomy in benign tumors.

## REFERENCES

1. Dixon FJ, Moore RA. Testicular tumors: A clinicopathological study. *Cancer* 1953; 6:427-440.
2. Mostofi FK, Price EB. Tumors of the male genital system. *Atlas of Tumor pathology. 2nd series fascicle 8*, Washington DC: Armed Forces Institute of Pathology, 1973; 86-99.
3. Mahon FB, Gosset F, Trinity RC, Madsen PO. Malignant interstitial cell tumor. *Cancer* 1973; 31: 1208-1212.
4. Morse MJ, Whitmore WF. Neoplasms of the testis. In: Walsh PC, Gittes RF, Perlmutter AD, Stamey TA, eds. *Campbell's Urology*, Philadelphia: WB Saunders Comp., 1986: 1535-1583.
5. Symington T, Cameron KM. Endocrine and genetic lesions. In: Pugh RCB, ed. *Pathology of the testis*. London: Blackwell, 1976: 265-303.
6. Grem JL, Robins HI, Wilson KS, Gilchrist K, Trump DL. Metastatic Leydig cell tumor of the testis. *Cancer* 1986; 58:2116-2119.
7. Langman J. *Medical embryology*. Baltimore: Williams and Wilkins, 1975:175-178.
8. Warwick R, Williams P. *Embryology*. In: Warwick R, Williams P, eds. *Gray's Anatomy*. Edinburgh: Longman, 1978: 183-192.
9. Holtz F, Abel MR. Testicular neoplasms in infants and children, II. Tumors of nongerminial origin. *Cancer* 1963; 16: 982.
10. Chen KTK, Spaulding RW, Flam MS, Brittin GM. Malignant interstitial cell tumor of the testis. *Cancer* 1982; 49:547-552.
11. Mikuz G, Schwarz S, Hopfel Kreiner I, Greber F. Leydig cell tumor of the testis. *Eur Urol*. 1980; 6:293-300.
12. Ober WB, Kabakow B, Hecht H. Malignant interstitial cell tumor of the testis: A problem in endocrine oncology. *Bull NY Acad Med*. 1976; 52:561-583.
13. Dalgaard JB, Hesselberg F. Interstitial cell tumors of the testes. *Acta Pathol Microbiol Scand*. 1957; 1:219-234.
14. Akdas A, Remzi D, Finci R. Bilateral interstitial cell tumor of the testis. *Br J Urol*. 1983; 55:123.
15. Rubin P. Cancer of the urogenital tract: Testicular tumors. *JAMA*. 1970; 213:89.
16. Savard K, Dorfman RI, et al. *Clinical morpho-*



- logical and biochemical studies of a virilizing tumor in the testis. *J Clin Invest.* 1960; 39:354.
17. Williams RH. The testes. In: Williams RH, ed. *Textbook of endocrinology.* Philadelphia: WB Saunders, 1980: 293-354.
  18. Azer PC, Braunstein GD. Malignant Leydig cell Tumor: Objective tumor response to o,p'-DDD. *Cancer* 1981; 47: 1251-1255.
  19. Feldman PS, Kovacs K, Horvath E, Adelson GL. Malignant Leydig cell tumor: Clinical, histologic and electron microscopic features. *Cancer* 1982; 49: 714-721.
  20. Davis S, DiMartino NA, Schneider G. Malignant interstitial cell carcinoma of the testis. *Cancer* 1981; 47:425-431.
  21. Tamoney HJ, Noriega A. Malignant interstitial cell tumor of the testis. *Cancer* 1969; 24:547-551.
  22. Ohlsen AS, Ronn G. Leydig cell carcinoma, report of a case. *Acta Chir Scand.* 1957; 112:411-414.
  23. Ward JA, Krantz S, Mendeloff J, Haltiwanger E. Interstitial cell tumor of the testis: Report of two cases. *J Clin Endocrinol.* 1960; 20:1622-1632.
  24. Short M, Coe JI. Malignant interstitial cell tumor of the testis: A case report. *J Urol.* 1963; 89: 851-855.
  25. Livesay JE, Branch HE, Eaton WL. Interstitial cell carcinoma of the testis. A case report. *AJR.* 1972; 115: 728-731.
  26. Abelson D, Bulaschenko IT, Trommer PR, Valdepena A. Malignant interstitial cell tumor of the testis treated with o,p'-DDD. *Metabolism* 1966; 15:242-256.
  27. Sato B, Huseby RA, Samuels LT. Characterization of estrogen receptors in various mouse Leydig cell tumor lines. *Cancer Res.* 1978; 38:2842.
  28. Van den Bogert C, Dontje BHJ, Kroon AM. Arrest in in-vivo growth of a solid Leydig cell tumor by prolonged inhibition of mitochondrial protein synthesis. *Cancer Res.* 1983; 43:2247.
  29. Corsi G, Palazzo G, Germani C, Scorza Barcelona P, Silvertrini B. 1-Halobenzyl-1 H-indazole-3 and carboxylic acids: A new class of anti-spermatogenic agents. *J Med Chem.* 1976; 19:778-783.



---

# MARMARA MEDICAL JOURNAL

## INSTRUCTIONS TO AUTHORS

1. Manuscripts, letters and editorial correspondence should be sent to "Editor, Marmara Medical Journal, Marmara University, Faculty of Medicine, İstanbul-Turkey" by first class mail (air-mail for overseas).
2. Submissions considered for publication are received with the understanding that no part of the submission has previously appeared elsewhere in any but abstract form.
3. Manuscripts should be typed double-spaced on standard-size typewriter paper with margins of at least 2.5 cm. This includes references, tables and figure-legends. The original typescript and two high-quality copies of the manuscripts should be submitted.
4. Number pages consecutively in order and place author (s) name, highest degree, institutional affiliations and address below the title.
5. Marmara Medical Journal invites papers on original research, case reports, reviews, short communications for practical applications, letters, editorials, book reviews and announcements. The number of typewritten pages should not exceed 10 for original articles, 12 for reviews, 4 for case reports and 1 for letters.
6. Original articles and research papers should normally be divided into following sections:
  - A. (1) An informative summary for not more than 200 words must be included and should appear at the beginning of the paper, (2) Key words, (3) Introduction, (4) Materials and Methods, (5) Results, (6) Discussion, and (7) References.
  - B. References must be typed in double spacing and numbered consecutively as they are cited. The style of references is that of the Index Medicus. List all authors when there are six or fewer, when there are seven or more, list the first three, then "et al". Sample references follow:
    1. Steward JH, Castaldi PA. Uremic bleeding: a reversible platelet defect corrected by dialysis. *OJ Med.* 1967; 36: 409 - 23.
    2. Beam AG. Wilson's Disease. In: Stanbury JB, Wyngaarden JB, Fredrickson DS, eds. *The metabolic basis of inherited disease.* New York: McGraw-Hill, 1972: 103-50.
7. Tables should be as few as possible and should include only essential data. Tables should be typed in double spacing on separate sheets and have a legend for each. Diagrams or illustrations should be drawn with black Indian ink on white paper. Each illustration should be accompanied by a legend clearly describing it: all legends should be grouped and typewritten (double spaced) on a separate sheet of paper. Photographs and photomicrographs should be unmounted high-contrast glossy black-on-white prints and should not be retouched. Each photograph or illustration should be marked on the back with the name (s) of the author (s), should bear an indication of sequence number and the top should be marked with an arrow. All measurements should be given in metric units.
8. Manuscripts are examined by the editorial board usually sent to out-side referees. The editor reserves the right to reject or to return the manuscript to the author(s) for additional changes if all the guidelines and requirements are not uniformly completed. Only two copies of the rejected papers are returned to the author (s).
9. Proofs will be submitted to the author responsible for proof correction and should be returned to the editor within 5 days. Major alterations from the text cannot be accented.
10. Correspondence and communications regarding manuscripts and editorial material subscriptions and payments should be sent to:

The Editor  
Marmara Medical Journal  
Marmara University, Faculty of Medicine  
Haydarpaşa - İstanbul.