

# High-Grade Serous Carcinoma Arising in Postmenopausal Ovarian Endometrioma: A Rare Case

Postmenopozal Ovarian Endometrioma Kaynaklı Yüksek Dereceli Over Seröz Karsinomu: Nadir Bir Olgu

Esra Keles<sup>1</sup>, Canan Kabaca<sup>1</sup>, Burak Giray<sup>2</sup>

<sup>1</sup> University of Health Sciences Turkey, Zeynep Kamil Training and Research Hospital, Department of Gynecologic Oncology, Istanbul, Turkey

<sup>2</sup> Department of Obstetrics and Gynecology, Division of Gynecologic Oncology, Koc University School of Medicine, Istanbul, Turkey

Yazışma Adresi / Correspondence:

Esra Keles

Zeynep Kamil Mahallesi, Dr. Burhanettin Ustunel Sokağı No:10, 34668 Uskudar, Istanbul, Turkey.

T: +90 531 667 45 92 E-mail : dresrakeles@hotmail.com

Geliş Tarihi / Received : 11.12.2021 Kabul Tarihi / Accepte: 18.08.2022

Orcid :

Esra Keles <https://orcid.org/0000-0001-8099-8883>

Canan Kabaca <https://orcid.org/0000-0002-7069-279X>

Burak Giray <https://orcid.org/0000-0002-3832-6634>

( Sakarya Tıp Dergisi / Sakarya Med J 2022, 12(3):577-580 ) DOI: 10.31832/smj.1035398

## Öz

Postmenopozal ovarian endometriomadan kaynaklanan yüksek dereceli seröz over kanseri vakasını sunmayı amaçladık. 64 yaş kadın hasta pelvik ağrı ve vajinal akıntı şikayeti ile kliniğimize başvurdu. Ultrason görüntülemesinde endometrial kalınlaşma ve sol adneksial alanda 37\*23 mm kistik kitle saptandı. Operasyon sırasında solid pelvik kitlenin cul-de-sac yerleşimli ve rektum ile sol overi infiltrate ettiği görüldü. Frozen incelemede rektosigmoid kolon ile uterus kökeni belirsiz adenokarsinoma ait morfolojik bulgular saptandı. Nihai patoloji sonucu iki mikroskopik odakta ovarian endometriomadan kaynaklı yüksek dereceli ovarian seröz kanser olarak geldi. Endometriomadan kaynaklanan epitelyal seröz over kanseri az görülen bir durumdur. Artmış tümör belirteçleri ile birlikte bulunan postmenopozal endometrioma ile karşılaşıldığında olası over kanserine malign dönüşüm olabileceği dikkate alınmalıdır.

## Anahtar Kelimeler

Endometrioma; over kanseri; postmenopozal; adneksiyal kitle.

## Abstract

Epithelial ovarian serous cancer arising in endometrioma is an uncommon phenomenon. Here, we present a case of postmenopausal ovarian high-grade serous carcinoma associated with ovarian endometrioma. A 64-year-old woman attended the clinic with pelvic pain and persistent vaginal discharge. Ultrasonography revealed an endometrial thickness and 37\*23 mm left cystic adnexal mass. During the operation, solid pelvic mass grossly located in the cul-de-sac infiltrating rectum and left ovarian cysts were observed. An intraoperative frozen section was performed with an interpretation of adenocarcinoma with an undetermined-site of the origin in the uterus and rectosigmoid colon. Final pathology revealed a high-grade ovarian serous carcinoma arising in ovarian endometrioma from two microscopic focuses. In sum, when we encounter postmenopausal endometrioma with increased biomarkers, it is crucial to consider the possibility of malignant transformation to ovarian cancer.

## Keywords

Endometrioma; ovarian cancer; postmenopausal; adnexal mass

## INTRODUCTION

Endometriosis is a common gynecologic disorder that affects 3-15% of premenopausal women and 3-5% of postmenopausal women.<sup>1</sup> Although endometriosis is considered as a benign disease, the incidence of the transformation to ovarian neoplasm is uncertain. Most epidemiological studies have consistently shown that endometriosis is associated with an increased risk of endometrioid and clear cell ovarian carcinoma compared to serous carcinoma.<sup>2</sup> Herein, we presented a case of unexpected ovarian serous carcinoma arising in endometrioma.

## CASE REPORT

A 64-year-old, gravida 2 para 2 woman was referred to our clinic with a complaint of pelvic pain and persistent discharge. She had hypertension, migraine, goiter, and congestive heart failure. The patient had experienced menarche and menopause at the ages of 14 and 51 years. She did neither smoke nor receive hormone replacement treatment. Written and verbal informed consent was obtained from the patient.

Ultrasonography revealed an endometrial thickness and 37\*23 mm left cystic adnexal mass. The patient's Pap smear resulted in a papillary structure paved with malignant epithelium. Human papillomavirus (HPV) status was negative. An endocervical curettage and endometrial biopsy were consistent with chronic cervicitis and an inactive endometrium comprising suspected malignant papillary structures. She had elevated serum levels of cancer antigen (CA) 125 level of 81 U/mL (<35), CA19-9 level of 133.6 U/mL (<37), and CA 15-3 level of 87 U/mL (<30). Colonoscopy and thorax X-ray were normal. Magnetic resonance imaging (MRI) revealed a 40\*33 mm malign solid mass with irregular borders in the region of the cervix extending through the rectum, infiltrating the anterior wall of the rectum. The lymphadenopathies with a diameter of 1 cm were present around the lesion. There was no marked infiltration in the inferior part of the ureter. A 29\*26 mm left adnexal cyst with proteinaceous content was reported.

During the operation, solid pelvic mass grossly located in the cul-de-sac infiltrating rectum and left ovarian cysts were observed (Fig 1). The excised left ovarian intraoperative frozen section resulted in benign. Next, a hysterectomy was performed. The frozen section of the uterus revealed adenocarcinoma with an undetermined primary focus. According to the pathology results and mass infiltrating the rectum, total abdominal hysterectomy, bilateral salpingo-oophorectomy, pelvic lymphadenectomy, rectosigmoid resection, and anastomosis were carried out during surgery.

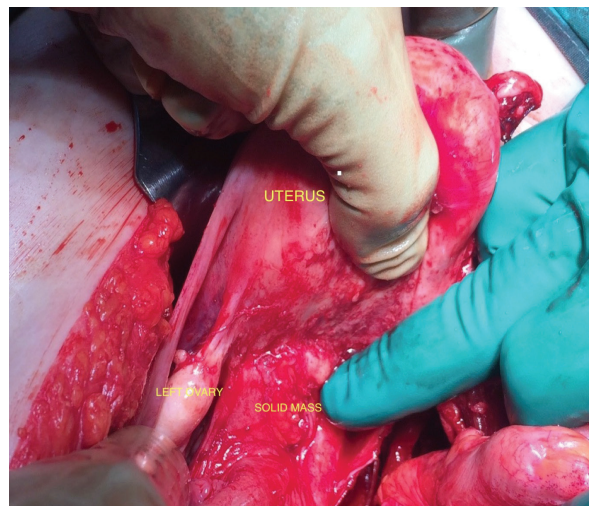


Fig 1. Pelvic mass located in the cul-de-sac.

The final histopathologic examination revealed the diagnosis of high-grade ovarian serous carcinoma arising in ovarian endometrioma from two microscopic foci. The patient was offered chemotherapy postoperatively. She received six cycles of paclitaxel and carboplatin and were followed up for one year with no recurrence of the disease.

## DISCUSSION

Malignant transformation of endometrioma is very rare. Malignant transformation of endometriosis first described by Sampson in 1925, pointed at 1% of cases.<sup>3</sup> Several studies indicated that endometriosis was related to the increased risk of endometrioid and clear cell carcinomas, a lower risk of serous adenocarcinoma, and no association with

mucinous carcinoma.<sup>2,4</sup> However, divergent results have also been reported by other authors. We present a rarely seen case of high-grade serous carcinoma that originates from millimetric foci of ovarian endometrioma.

In contrast to most studies, patients with endometriosis-associated epithelial ovarian cancer (EAOC) were frequently diagnosed at premenopausal age. The patient diagnosed during the postmenopausal period have rarely been reported.<sup>5-7</sup>

Consistent with the literature, there is conclusive evidence to support that endometrioma coexisting ovarian cancer are frequently diagnosed at an early stage and a lower grade of disease compared to non-EAOC, so as presented case diagnosed at Stage II.<sup>5</sup>

Regarding non-EAOC, the sites of extra-ovarian cancers associated with endometriosis have been reported such as; bowel (particularly rectum and colon) rectovaginal septum, vagina, bladder, parametrium and other pelvic ligaments, and cervix.<sup>8</sup> In this present case, pelvic mass is located extraordinarily at the Douglas pouch.

In conclusion, we presented a rare case of millimetric focus of high-grade ovarian serous carcinoma arising in ovarian endometrioma in the postmenopausal period. When we encounter postmenopausal endometrioma with increased biomarkers and a pelvic mass, it is important to consider the possibility of malignant transformation to ovarian cancer.

### **Acknowledgment**

#### **Declaration of patient consent**

The authors certify that they have obtained all appropriate patient consent forms. In the form, the patient has given her consent for her images and other clinical information to be reported in the Journal. The patient understands that her name and initials will not be published, and due efforts will be made to conceal her identity, but anonymity cannot

be guaranteed.

### **Acknowledgments**

None.

### **Conflict of interest**

The patients declare no conflict of interest.

### **Author Contributions**

All of the authors declare that they have all participated in the design, execution and analysis of the paper, that they have approved the final version.

#### Kaynaklar

1. Secosan C, Balulescu L, Brasoveanu S, Balint O, Pirtea P, Dorin G, et al. Endometriosis in Menopause-Renewed Attention on a Controversial Disease. *Diagnostics (Basel)*. 2020;10(3):134.
2. Samartzis EP, Labidi-Galy SI, Moschetta M, Uccello M, Kalaitzopoulos DR, Perez-Fidalgo JA, et al. Endometriosis-associated ovarian carcinomas: insights into pathogenesis, diagnostics, and therapeutic targets-a narrative review. *Ann Transl Med*. 2020;8(24):1712.
3. Sampson JA. Endometrial carcinoma of the ovary arising in endometrial tissue in that organ. *Arch Surg*. 1925;10:1-72.
4. Murakami K, Kotani Y, Nakai H, Matsumura N. Endometriosis-Associated Ovarian Cancer: The Origin and Targeted Therapy. *Cancers (Basel)*. 2020;12(6):1676.
5. Li Q, Sun Y, Zhang X, Wang L, Wu W, Wu M, et al. Endometriosis-associated ovarian cancer is a single entity with distinct clinicopathological characteristics. *Cancer Biol Ther*. 2019;20(7):1029-1034.
6. Torng PL. Clinical implication for endometriosis associated with ovarian cancer. *Gynecol Minim Invasive Ther*. 2017;6(4):152-156.
7. Thomsen LH, Schnack TH, Buchardi K, Hummelshoj L, Missmer SA, et al. Risk factors of epithelial ovarian carcinomas among women with endometriosis: a systematic review. *Acta Obstet Gynecol Scand*. 2017;96(6):761-778.
8. Chen M, Zhang Y, Xu M, Liu D, Yang Y, Yao S. Primary high-grade serous cancer arising from uterosacral ligament endometriosis: two case reports. *J Int Med Res*. 2022;50(7):3000605221109373.