

CASE REPORT

Thyroid metastasis from renal cell carcinoma eight years after radical nephrectomy: a case report

Radikal nefrektomiden sekiz yıl sonra renal hücreli karsinomdan tiroit metastazi: Olgu sunumu

Canan UZEL, M.D.,¹ Halil COŞKUN, M.D.,² Tarık TERZİOĞLU, M.D.,³ Necdet ARAS, M.D.⁴

A forty-five-year-old female patient presented with thyroid nodules eight years after radical nephrectomy for renal cell carcinoma (T₂N₀M₀, grade 2, clear cell subtype) in the right kidney. Ultrasonography of the neck showed multiple hypoechoic macronodules. There was no lymphadenomegaly. During total thyroidectomy following an initial diagnosis of multinodular goiter, frozen section analysis was made, which showed metastasis from renal cell carcinoma. Immunohistochemical studies demonstrated that the tumor cells were negative for thyroglobulin staining. No recurrences or other metastatic disease were seen during a follow-up period of 12 months. Although clinically the thyroid gland is a rare site for tumor metastasis, this possibility should be kept in mind in patients with a previous history of renal cell carcinoma.

Key Words: Carcinoma/secondary; carcinoma, renal cell/secondary/pathology; kidney neoplasms/pathology; thyroid neoplasms/secondary/surgery; thyroidectomy.

Sekiz yıl önce sağ renal hücreli karsinom tanısıyla radikal nefrektomi yapılan (T₂N₀M₀ grade 2, berrak hücreli subtip) 45 yaşında kadın hastada tiroitte nodül saptandı. Boyun ultrasonografisinde multipl hipoekoik makronodüler yapı görüldü, lenfadenomaliye rastlanmadı. Multinodüler guatr düşünülerek yapılan total tiroidektomi sırasında, frozen ile incelenen örnekte renal hücreli karsinom metastazi saptandı. İmmünohistokimyasal analizde, tiroit tümöründeki berrak hücreler tiroglobulin için boyama göstermedi. Ameliyat sonrasında hastanın 12 aylık izleminde nüks veya başka metastatik hastalığa rastlanmadı. Tiroit bezinde metastaz çok nadir olsa da, renal hücreli karsinom öyküsü olan hastalarda tiroide metastaz olabileceği göz önünde bulundurulmalıdır.

Anahtar Sözcükler: Karsinom/ikincil; karsinom, renal hücreli/ikincil/patoloji; böbrek neoplazileri/patoloji; tiroit neoplazileri/ikincil/cerrahi; tiroidektomi.

Solitary thyroid metastasis from a renal cell carcinoma (RCC) is uncommon. This paper presents a patient with RCC that metastasized to the thyroid gland eight years after nephrectomy of the right kidney.

CASE REPORT

A forty five-year old female patient presented with a swelling in her neck. She had a history of right radical nephrectomy for RCC, of clear cell subtype, in February 1995. The tumor was confined to the lower

◆ ¹Department of General Surgery, VKV American Hospital; ²Department of General Surgery, Şişli Etfal Training and Research Hospital; Departments of ³General Surgery, and ⁴Urology, Medicine Faculty of İstanbul University; İstanbul, all in Turkey.

◆ Received: February 26, 2003. Accepted for publication: July 27, 2003.

◆ Correspondence: Dr. Canan Uzel. Vehbi Koç Vakfı Amerikan Hastanesi Genel Cerrahi Kliniği, 34365 Nişantaşı, İstanbul, Turkey. Tel: +90 212 - 311 20 00 / 2760 Fax: +90 212 - 311 23 44 e-posta: cananuzel@hotmail.com

◆ ¹Vehbi Koç Vakfı Amerikan Hastanesi Genel Cerrahi Kliniği; ²Şişli Etfal Eğitim ve Araştırma Hastanesi Genel Cerrahi Kliniği; İstanbul Üniversitesi İstanbul Tıp Fakültesi, ³Genel Cerrahi Anabilim Dalı, ⁴Üroloji Anabilim Dalı, İstanbul.

◆ Dergiye geliş tarihi: 26 Şubat 2003. Yayın için kabul tarihi: 27 Temmuz 2003.

◆ İletişim adresi: Dr. Canan Uzel. Vehbi Koç Vakfı Amerikan Hastanesi Genel Cerrahi Kliniği, 34365 Nişantaşı, İstanbul. Tel: 0212 - 311 20 00 / 2760 Faks: 0212- 311 23 44 e-posta: cananuzel@hotmail.com

pole of the right kidney. There was no capsular invasion. Metastatic work-up at the time of diagnosis was negative. The tumor was staged as T₂N₀M₀ according to the UICC staging system (grade 2).

On physical examination, she was found to be in good general condition except for multiple nodules detected by palpation on both lobes of the thyroid gland. Laboratory findings showed normal thyroid function tests.

Ultrasonography of the neck showed six macronodules (Fig. 1a, b). The largest was an hypoechoic lesion in the left lobe and measured 19x17 mm. The size of the remaining nodules ranged from 8 mm to 19 mm. There were four other hypoechoic nodules, one of which was in the right lobe, and another in

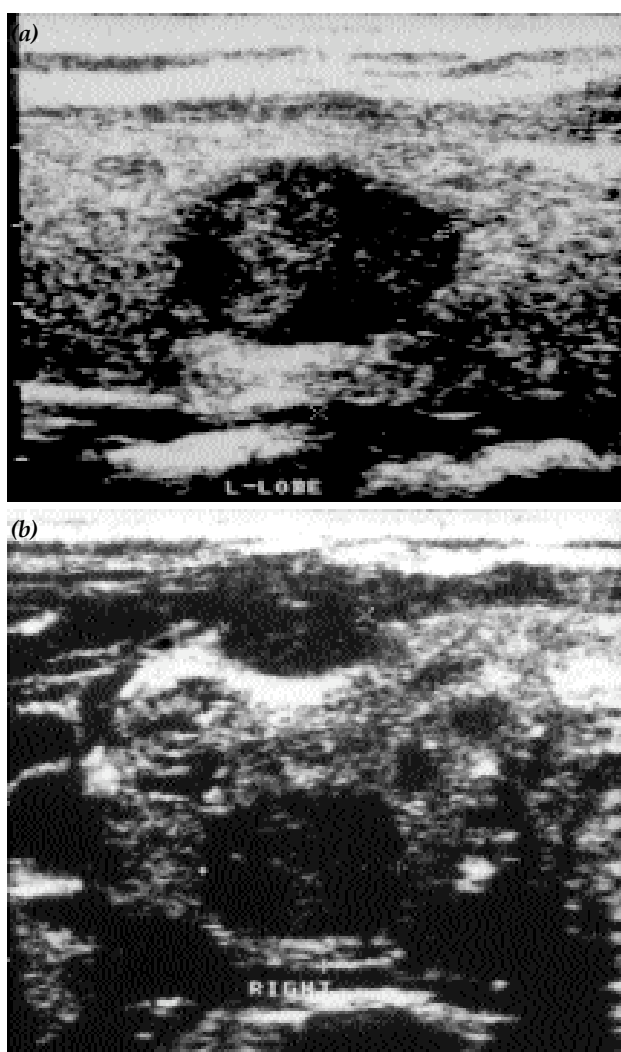


Fig. 1 - Ultrasonography of the thyroid. Multiple nodules (a) in the left and (b) right lobes.

the isthmus. One nodule appeared isoechoic and calcified. There was no lymphadenomegaly.

As the patient lived in an endemic region of Turkey for multinodular goitre she was thought to have a multinodular goitre. Therefore, no further investigation was made before the operation and total thyroidectomy was performed. At surgery, four well-circumscribed yellowish tumors were seen in both lobes. Frozen section revealed metastasis from RCC. There was no evidence for extrathyroidal extension, nor any lymphatic spread. The postoperative period was uneventful. No evidence for recurrence or other metastatic diseases was detected during a follow-period of 12 months.

Cut sections of the left total thyroidectomy specimen (4.5x4x3 cm) contained two solid tumoral nodules which were yellowish in colour, the largest being 1.5 cm in diameter (Fig. 2). Frozen section analysis revealed nests of atypical cells with clear and eosinophilic cytoplasm and hyperchromatic nuclei with mild pleomorphism. Taking the history of the patient into consideration, frozen section diagnosis was made as metastasis from RCC. The right total thyroidectomy specimen (4x3.5x2.5 cm) revealed three similar nodules, the largest measuring 2 cm. Hematoxylin-eosin staining of paraffin blocks of all the tumoral nodules showed the above-mentioned malignant characteristics (Fig. 3, 4). The remaining two nodules were histopathologically benign colloidal nodules. The tumor cells were negative for thyroglobulin (Neomarkers, Thyroglobulin Ab-3) (2H11+6E1) (Fig. 5), positive for vimentin (Neomarkers, Vimentin Ab-2, V9) (Fig. 6) and pancytokeratin (Neomarkers, Keratin Pan Ab-2, Cocktail) antibodies. Light microscopic and immunohistochemical features of the tumor were consistent with metastasis of RCC to the thyroid gland.

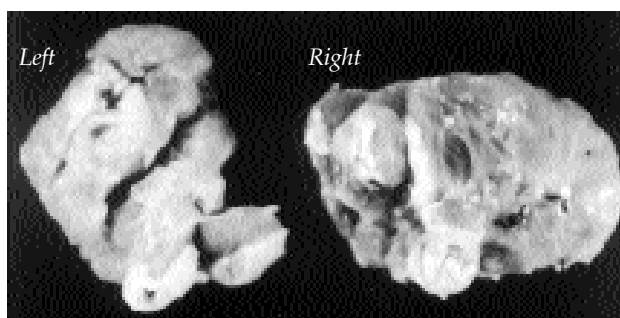


Fig. 2 - Macroscopic view of the thyroid lobes.

DISCUSSION

Metastatic tumors to the thyroid gland present as a solitary nodule or multiple nodules. They may be microscopically well-circumscribed or invasive. They may also show a diffuse interlobar infiltrative pattern with vascular invasion.^[1]

Carcinomas of the lung and breast have been enumerated in the literature as two of the most common primary tumors that metastasize to the thyroid. However, the incidence of clinically significant metastases from other sites has been documented in many studies.^[2,3] Chen et al.^[2] reported ten patients with thyroid metastases, which had

been isolated during an eight-year period, five of which had metastasis from renal cell carcinoma.

Hematological malignancies other than lymphomas may also invade the thyroid gland. In a report of patients with multiple myeloma, 2.6% had thyroid invasion.^[4]

Extramedullary plasmocytoma of the thyroid may be seen, although the majority of cases progress to multiple myeloma on longer follow up.^[5] Leukemic infiltrations to the thyroid and metastatic Kaposi's sarcoma associated with AIDS have also been reported.^[6]

Preoperative fine-needle aspiration cytology (FNAC) has been described as an effective proce-

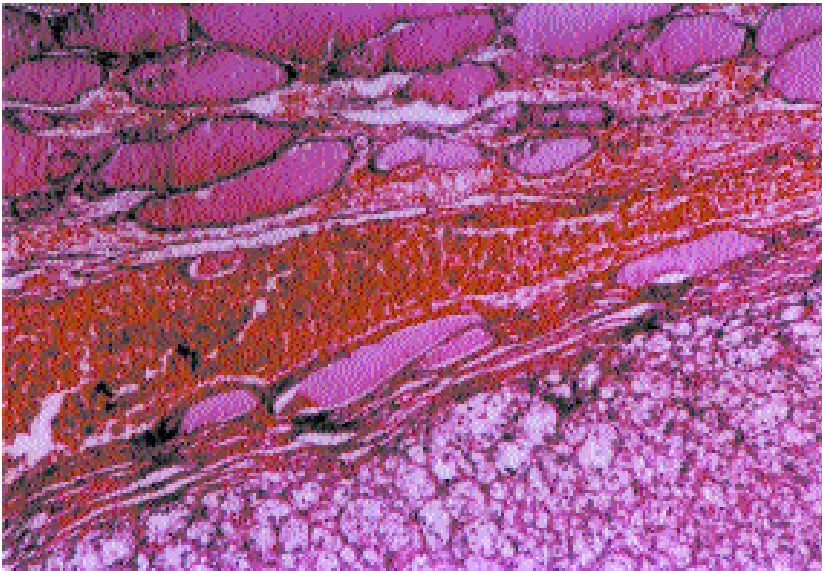


Fig. 3 - Malignant tumor separated from the thyroid tissue with a thin fibrous capsule (H-E x 40).

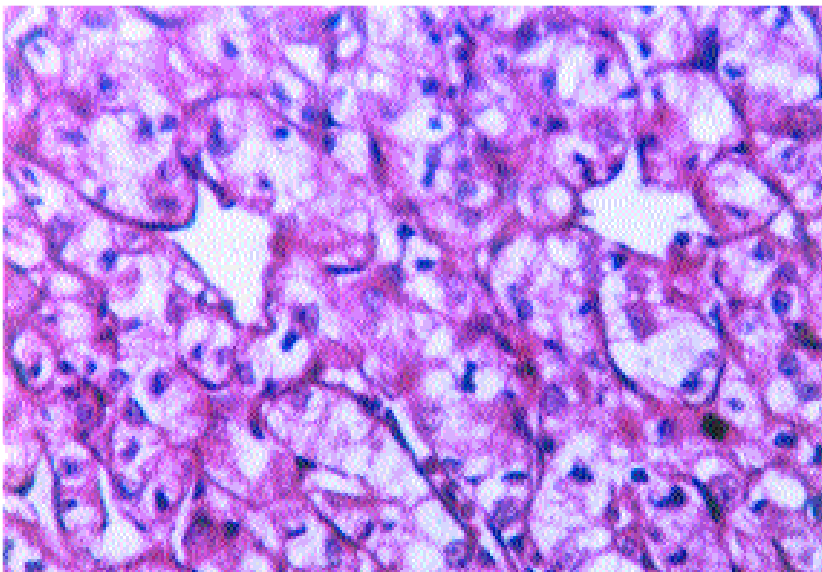


Fig. 4 - Tumor cells with hyperchromatic nuclei, clear and eosinophilic cytoplasm (H-E x 400).

cedure for the diagnosis of metastatic thyroid cancer.^[7,8] A more accurate incidence of clinically significant metastases to the thyroid came from clinical series that employed preoperative FNAC for thyroid masses, which was 5.7% and 7.5%.^[8,9] As frozen section analysis showed metastatic renal cell carcinoma in our case, total thyroidectomy was performed and surgical specimens were sent for further immunohistologic examination.

There is no clear consensus regarding the role of previous surgery in metastatic diseases to the thyroid.^[10] Most authors recommend thyroid lobectomy/isthmusectomy when the metastatic disease is confined to a single lobe of the thyroid gland,^[10,11] or

for palliation of airway obstruction.^[12] However, due to the limited number of patients, it is difficult to make definite recommendations. It seems clear that resection of all thyroid metastases should be attempted with at least thyroid lobectomy. In case of extensive metastasis or a large lesion, total or near-total thyroidectomy may be required. In the absence of randomized, prospective trials comparing surgical and nonsurgical therapies for the treatment of isolated metastases to the thyroid, the true benefit of thyroidectomy remains unclear. In the absence of locally recurrent and metastatic disease at other sites, resection may be beneficial and may prolong survival.

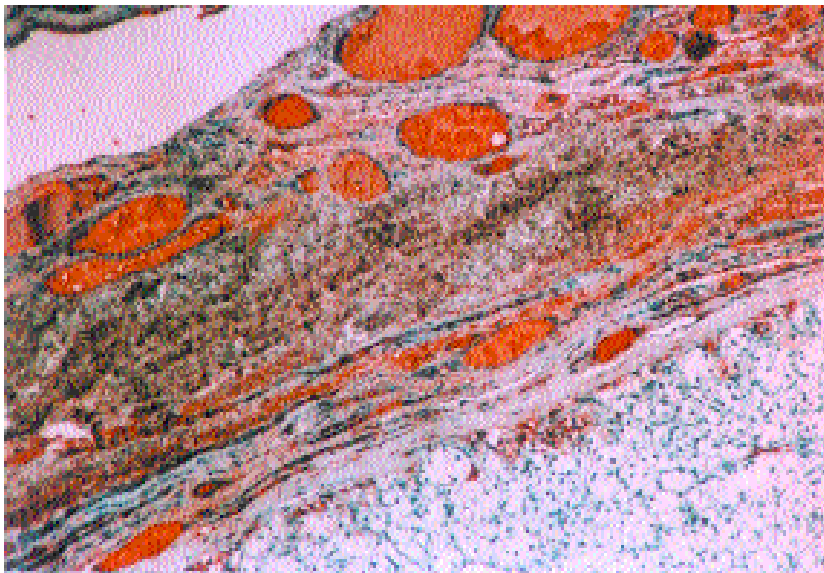


Fig. 5 - The tumor cells were negative for thyroglobulin staining (Thyroglobulin Ab-3 x 100).

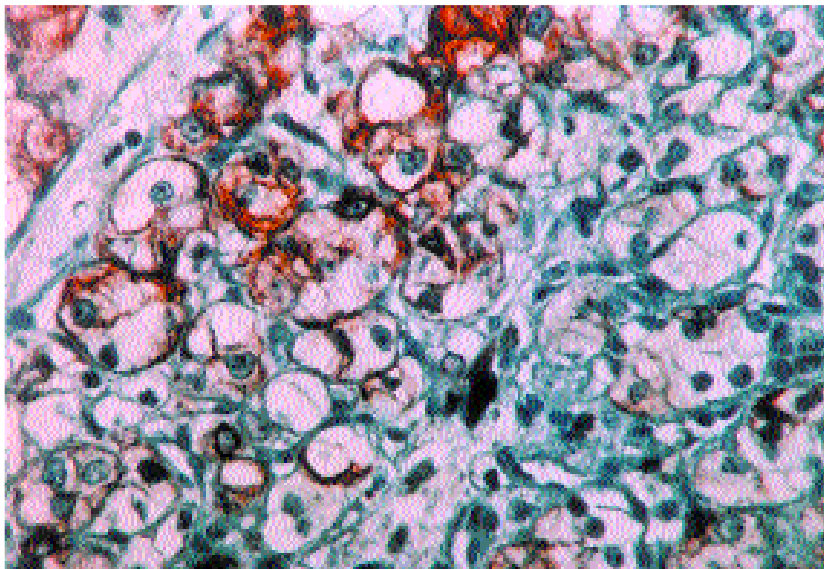


Fig. 6 - The tumor cells showing vimentin positivity (Vimentin x 400).

Renal cell carcinoma often tends to show a slow progression in its clinical course. The rate of survival after thyroidectomy was reported to be 60% for isolated thyroid metastases during a mean follow-up period of 5.2 years.^[2] No recurrences were encountered in the presented case during 12 months after thyroidectomy.

In conclusion, clinically significant metastasis to the thyroid gland is relatively infrequent. However, the possibility of a metastatic disease to the thyroid gland should always be kept in mind in patients with a previous history of cancer, especially renal cell carcinoma. Survival can be improved after resection of the metastatic tumor through thyroidectomy.

REFERENCES

1. Harach HR, Williams ED. Pathology of thyroid cancer. In: Wheeler MH, Lazarus JH, editors. Diseases of the thyroid: pathophysiology and management. 4th ed. London: Chapman & Hall; 1994. p. 341-8.
2. Chen H, Nicol TL, Udelsman R. Clinically significant, isolated metastatic disease to the thyroid gland. *World J Surg* 1999;23:177-80.
3. Ivy HK. Cancer metastatic to the thyroid: a diagnostic problem. *Mayo Clin Proc* 1984;59:856-9.
4. Li Volsi VA. Pathology of thyroid disease. In: Falk SE, editor. *Thyroid disease: endocrinology, surgery, nuclear medicine, and radiotherapy*. 2nd ed. Philadelphia: Lippincott Raven; 1997. p. 127-75.
5. Kocak S. Ender görülen primer tiroit tümörleri ve tiroide metastaz yapan kanserler. In: İşgör A, editör. *Tiroit hastalıkları ve cerrahisi*. 1. baskı. İstanbul: Avrupa Tıp Yayıncılık; 2000. s. 439-43.
6. Welch K, Finkbeiner W, Alpers CE, Blumenfeld W, Davis RL, Smuckler EA, et al. Autopsy findings in the acquired immune deficiency syndrome. *JAMA* 1984; 252:1152-9.
7. Lasser A, Rothman JG, Calamia VJ. Renal-cell carcinoma metastatic to the thyroid. Aspiration cytology and histologic findings. *Acta Cytol* 1985;29:856-8.
8. Watts NB. Carcinoma metastatic to the thyroid: prevalence and diagnosis by fine-needle aspiration cytology. *Am J Med Sci* 1987;293:13-7.
9. Michelow PM, Leiman G. Metastases to the thyroid gland: diagnosis by aspiration cytology. *Diagn Cytopathol* 1995;13:209-13.
10. McCabe DP, Farrar WB, Petkov TM, Finkelmeier W, O'Dwyer P, James A. Clinical and pathologic correlations in disease metastatic to the thyroid gland. *Am J Surg* 1985;150:519-23.
11. Ericsson M, Biorlund A, Cederquist E, Ingemansson S, Akerman M. Surgical treatment of metastatic disease in the thyroid gland. *J Surg Oncol* 1981;17:15-23.
12. Czech JM, Lichtor TR, Carney JA, van Heerden JA. Neoplasms metastatic to the thyroid gland. *Surg Gynecol Obstet* 1982;155:503-5.