

CASE REPORT

## A case of giant cholesteatoma extending to the posterior fossa

### Posterior fossaya uzanan dev kolesteatom: Olgu sunumu

Kemal UYGUR, M.D.,<sup>1</sup> Samet ÖZLÜGEDİK, M.D.,<sup>2</sup> Hasan YASAN, M.D.,<sup>1</sup> Gürsel DURSUN, M.D.<sup>2</sup>

We present a 43-year-old male patient who developed a giant cholesteatoma with lateral sinus obliteration and involvement of the posterior cranial fossa. The only complaints were left-sided aural discharges and total sensorineural hearing loss. Examination revealed a mass lesion consistent with cholesteatoma within the left middle ear. Computed tomography and magnetic resonance imaging showed an extensive acquired cholesteatoma in the left middle ear, invading the posterior cranial fossa and leading to lateral sinus obliteration. The patient underwent left radical mastoidectomy. He had an uneventful postoperative follow-up for 13 months. This case emphasizes the value of preoperative radiologic assessment of giant cholesteatomas that may present with relatively few or limited symptoms.

**Key Words:** Cerebellar diseases/surgery/radiography; cholesteatoma/surgery/radiography.

Kolesteatomun ameliyat öncesi radyolojik değerlendirilmesinin önemine dikkat çekmek için lateral sinüs obliterasyonu ve arka kafa çukuru tutulumu olan bir olgu sunuldu. Kırk üç yaşındaki erkek hastanın uzun yıllardır var olan kulak akıntısı ve sol kulakta tam işitme kaybı dışında başka şikayeti yoktu. Muayenede sol kulakta kolesteatom ile uyumlu kitle saptandı. Bilgisayarlı tomografi ve manyetik rezonans görüntüleme incelemelerinde, sol kulakta lateral sinüs obliterasyonu ve posterior kranyal fossa tutulumuna yol açan dev bir kolesteatom geliştiği belirlendi. Sol radikal mastoidektomi ile kolesteatom çıkarıldı. Kolesteatomun neden olduğu yaygın kafa içi patolojiye rağmen, ameliyatta ve ameliyat sonrasında 13 aylık izlem sırasında hastada herhangi bir komplikasyon ya da nüks gelişmedi.

**Anahtar Sözcükler:** Serebellar hastalıklar/cerrahi/radyografi; kolesteatom/cerrahi/radyografi.

Cholesteatoma is a troublesome epidermoid structure that exhibits an independent and deleterious growth, replaces the middle ear mucosa, resorbs underlying bones, and tends to recur after its removal.<sup>[1]</sup> Cholesteatoma of the middle ear cleft has long been recognized as having the potential to

cause serious complications, including involvement of the intracranial space, and fistulization of, and invasion to, the labyrinth. The most common intracranial complications are meningitis and abscess formation, the latter occurring most frequently in the temporal lobe.

◆ <sup>1</sup>Department of Otolaryngology, Medicine Faculty of Süleyman Demirel University, Isparta; <sup>2</sup>Department of Otolaryngology, Medicine Faculty of Ankara University, Ankara, all in Turkey.

◆ Received: December 25, 2002. Accepted for publication: April 18, 2003.

◆ Correspondence: Dr. Hasan Yasan. Modernevler Mah., 142. Cad., Çevreyolu Nurlu Apt., D: 17, 32200 Isparta, Turkey.  
Tel: +90 246 - 211 23 00 Fax: +90 246 - 237 17 62  
e-mail: alpyasan@hotmail.com

◆ <sup>1</sup>Süleyman Demirel Üniversitesi Tıp Fakültesi, KBB Hastalıkları Anabilim Dalı, Isparta; <sup>2</sup>Ankara Üniversitesi Tıp Fakültesi, KBB Hastalıkları Anabilim Dalı, Ankara.

◆ Dergiye geliş tarihi: 25 Aralık 2002. Yayın için kabul tarihi: 18 Nisan 2003.

◆ İletişim adresi: Dr. Hasan Yasan. Modernevler Mah., 142. Cad., Çevreyolu Nurlu Apt., D: 17, 32200 Isparta.  
Tel: 0246 - 211 23 00 Faks: 0246 - 237 17 62  
e-posta: alpyasan@hotmail.com

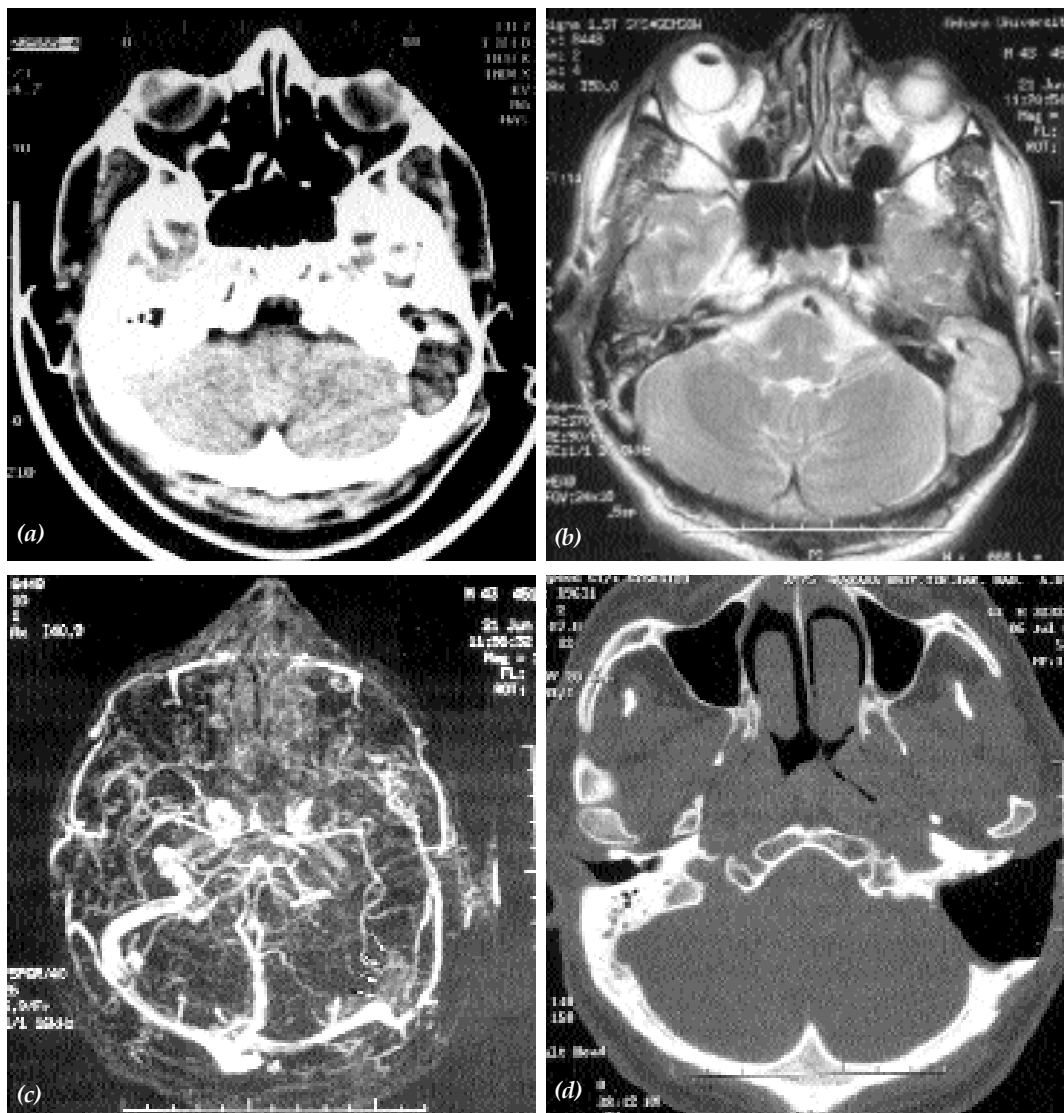
Primary cholesteatoma in the posterior fossa accounts for 5 to 6 percent of all cerebellopontine angle lesions.<sup>[2]</sup> Extension of an acquired aural cholesteatoma beyond the confines of the temporal bone is unusual, but has been reported in the middle fossa, neck, and the infratemporal fossa.<sup>[3,4]</sup>

We present a case of cholesteatoma that caused widespread involvement of the posterior cranial fossa, with lateral sinus obliteration and complete loss of audiologic function. Interestingly, despite its

huge size, there were no signs of dizziness, cerebrospinal fluid otorrhea, or facial palsy.

### CASE REPORT

A forty-three-year-old male patient was referred to the otolaryngology department of Medical School of Ankara University with hearing loss and discharge from the left ear. He had a history of aural discharges since childhood and total deafness in the affected ear, but with low level of bother because of his normal



**Fig. 1 -** (a) Computed tomography scan demonstrating an almost complete destruction of the mastoid bone with erosion into the posterior fossa. (b) T<sub>2</sub>-weighted magnetic resonance image showing a giant cholesteatoma extending from the mastoid into the posterior cranial fossa. (c) An MR venogram showed a filling defect consistent with left lateral sinus obliteration. (d) Postoperative CT view of the mastoid defect area (left side).

right ear, he had not sought medical advice until shortly before his admission. He gave no other history, in particular, of dizziness or cerebrospinal fluid otorrhea. There were no signs of nystagmus, and the fistula sign was negative. Neurological examination was normal. The tympanic membrane was normal on the right side, but a large polypoid mass was observed in the left ear filling the left external meatus. Pure-tone audiometry revealed normal hearing on the right and total hearing loss on the left. He did not recall any previous otologic surgery. Computed tomography demonstrated almost complete destruction of the mastoid bone with erosion into the posterior fossa. The lesion showed no contrast enhancement (Fig. 1a). T<sub>2</sub>-weighted magnetic resonance scans revealed an area of high-signal intensity in the left mastoid area, measuring 4.5x3.5 cm, and a slight protrusion into the posterior fossa (Fig. 1b). An MR venogram showed a filling defect consistent with left-sided lateral sinus obliteration (Fig. 1c).

The patient underwent left radical mastoidectomy. At surgery, a huge (4.5x3.5 cm), infected, pearly tumor was observed, involving the posterior fossa dura, and leading to medial displacement of the cerebellar parenchyma and obliteration of the lateral sinus. The facial nerve was found in its normal location, with its bony canal almost totally eroded from the stylomastoid foramen to the geniculate ganglion. There was no dural erosion or cerebrospinal fluid leakage. After the cholesteatoma was totally removed, the large defect was filled with nitrofurazone-impregnated gauze strips. The histopathologic diagnosis was cholesteatoma and inflammatory polyps. The postoperative follow-up period of 13 months was uneventful (Fig. 1d).

## DISCUSSION

Cholesteatoma is a non-malignant, slowly progressive, destructive middle ear disease.<sup>[5]</sup> Extension of aural cholesteatoma through the temporal bone cortex is unusual, but has been reported in the middle and posterior cranial fossae.<sup>[6,7]</sup>

Bone destruction, due mostly to the osteoclastic erosion, is known to be an important cause of complications in chronic otitis media.<sup>[8]</sup> Humeral factors, such as prostaglandin, cathepsin D, and a parathyroid hormone-like protein have been suggested as responsible for the activation of osteoclasts.<sup>[9]</sup>

Cholesteatomas, even small in size, may cause extra- and intratemporal complications. Cholesteatoma-

induced compromised flow through the lateral sinus forces the collateral sinus to handle the burden of venous drainage from the occluded side. This may probably lead to dural arteriovenous malformations by a mechanism described by Arnautovic et al.<sup>[10]</sup>

The presented case is a good example of cholesteatoma invasiveness beyond the confines of the temporal bone unless it is treated. The extensive erosion into the posterior fossa may lead to very serious intracranial complications. Fortunately, such a huge cholesteatoma did not lead to any complications other than one-sided total hearing loss. Even the facial nerve function was maintained despite the total erosion of its bony wall.

This case emphasizes the need for utmost awareness regarding the development of a giant cholesteatoma that presents with relatively few or limited symptoms. Radiologic imaging modalities should be integrated into findings obtained from clinical history and physical examination even in conditions that are not suggestive of a giant cholesteatoma.

## REFERENCES

1. McCabe BF, Sade J, Abramson M. Summary reports on National-International Conferences. First International Conference on Cholesteatoma. *Ann Otol Rhinol Laryngol* 1976;85:844-55.
2. Horn KL, House JW. Aural cholesteatoma extending into the posterior fossa. *Am J Otol* 1986;7:371-2.
3. Sheehy JL. Residual cholesteatoma in the middle cranial fossa. A case report. *Am J Otol* 1984;5:227-8.
4. Horn KL, Brackmann DE, Luxford WM, Shea JJ 3rd. The supratubal recess in cholesteatoma surgery. *Ann Otol Rhinol Laryngol* 1986;95(1 Pt 1):12-5.
5. Rapoport PB, Di Francesco RC, Mion O, Bento RF. Huge congenital cholesteatoma simulating an intracranial abscess. *Otolaryngol Head Neck Surg* 2000; 123(1 Pt 1):148-9.
6. Atlas MD, Moffat DA, Hardy DG. Petrous apex cholesteatoma: diagnostic and treatment dilemmas. *Laryngoscope* 1992;102(12 Pt 1):1363-8.
7. Arkin CF, Millard M, Medeiros LJ. Giant invasive cholesteatoma. Report of a case with cerebellar invasion. *Arch Pathol Lab Med* 1985;109:960-1.
8. Yoon TH, Lee SH, Park MH, Chung JW, Kim HJ. Inhibition of cholesteatomatous bone resorption with pamidronate disodium. *Acta Otolaryngol* 2001;121:178-81.
9. Youngs R. Chronic suppurative otitis media-cholesteatoma. In: Ludman H, Wright T, editors. *Diseases of the ear*. 6th ed. London: Arnold; 1988. p. 386-97.
10. Arnautovic KI, Al-Mefty O, Angtuaco E, Phares LJ. Dural arteriovenous malformations of the transverse/sigmoid sinus acquired from dominant sinus occlusion by a tumor: report of two cases. *Neurosurgery* 1998;42:383-8.