

CASE REPORT

Acquired and congenital internal carotid artery anomalies in two cases: an important threat for the otolaryngologist

İki olguda edinsel ve konjenital internal karotid arter anomalileri: Otolaringologlar için önemli bir tehdit

Devrim BEKTAŞ, M.D.,¹ MD, Refik ÇAYLAN, M.D.,¹ Ömer KORKMAZ, M.D.,¹ Fikriye Sakıncı SAVAŞ, M.D.²

Diseases of the extracranial portion of the internal carotid artery (ICA) are rarely seen in the otolaryngology practice. We report two different pathologies of the ICA, which presented with otolaryngological symptoms. The first case was a 70-year-old woman with symptoms of chronic pharyngitis. In her physical examination, a pulsatile mass at the right posterolateral oropharynx was identified. Magnetic Resonance Imaging revealed a tortuous ICA. No treatment was offered. The second case was a 75-year-old woman with a 2 month history of upper neck mass. She did not have any additional complaints and her physical examination was normal except the mass. Doppler ultrasonography showed a high fluid flow within the mass. Digital angiography demonstrated an ICA aneurysm. Because the patient refused any surgery, antiplatelet treatment was started.

Key Words: Carotid artery, internal/pathology; carotid artery diseases/diagnosis; carotid artery, Internal/radiology; carotid artery/anomalies.

Arteria Karotis İnterna'nın (AKİ) ekstrakraniyel kısmının hastalıkları KBB'de seyrek rastlanılan hastalıklar arasındadır. Bu olgu sunumundaki kulak burun boğaz şikayetleri ile polikliniğimize başvuran iki hasta sunuldu. İlk olguda 70 yaşında, kronik farenjit şikayetleri ile başvuran kadın hastanın muayenesinde sağ posterolateral orofarenkste pulsatil kitleye rastlandı. Manyetik rezonans görüntüleme ile bu lezyonun anormal seyirli AKİ olduğu görüldü. Hasta bu konuda bilgilendirildi ve herhangi bir tedavi önerilmedi. İkinci olgu 75 yaşında iki aylık boyunda kitle şikayeti olan bir kadın hastaydı. Kitle dışında herhangi bir şikayeti yoktu ve fizik muayenesinde başka bir patolojiye rastlanmadı. Doppler Ultrasonografide kitle içinde yüksek miktarda sıvı akımı olduğu izlendi. Dijital anjiyografi uygulandı ve kitlenin bir AKİ anevrizması olduğu görüldü. Hasta önerilen cerrahi tedaviyi reddetti ve bunun üzerine hastaya antiplatelet tedavisi önerildi.

Anahtar Sözcükler: Arteria karotis interna/patoloji; arteria karotis hastalıkları/tanı; arteria karotis interna/radyoloji; arteria karotis/anomaliler.

The major arteries supplying the head are the commonly carotid arteries and their internal and external branches. Although rare, carotid arteries

can present with such pathologies that imitate more commonly encountered lesions of the head and neck. Lack of anticipation and misdiagnosis can eas-

-
- ◆ Departments of ¹Otolaryngology and ²Radiology, Medicine Faculty of Karadeniz Teknik University, of Farabi Hospital (¹Karadeniz Teknik Üniversitesi Tıp Fakültesi Farabi Hastanesi Kulak Burun Boğaz Hastalıkları Anabilim Dalı, ²Radyoloji Anabilim Dalı), Trabzon, Turkey.
 - ◆ Received - February 19, 2003 (Dergiye geliş tarihi - 19 Şubat 2003). Accepted for publication - September 22, 2003 (Yayın için kabul tarihi - 22 Eylül 2003).
 - ◆ Correspondence (İletişim adresi): Dr. Refik Çaylan. Karadeniz Teknik Üniversitesi Tıp Fakültesi Farabi Hastanesi KBB Hastalıkları Anabilim Dalı, 61080 Trabzon, Turkey. Tel: +90 462 - 325 30 18 / 5548 Fax (Faks): +90 462 - 325 83 24 e-mail (e-posta): refikcaylan@yahoo.com

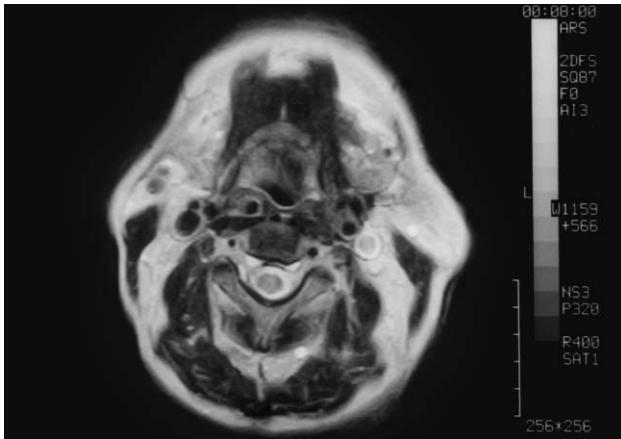


Fig. 1 - Axial MRI showing a tortuous internal carotid artery at the right side with an anterior displacement of retropharyngeal mucosa.

ily lead to catastrophic results as reported in the literature. We report two cases of internal carotid pathology with different presentation.

Case 1- A 70 year-old woman was admitted to our department because of symptoms of chronic pharyngitis of 3 year duration. Her personal history was insignificant. In her physical examination, a pulsatile mass at the right posterolateral oropharynx was identified. Magnetic resonance imaging (MRI) revealed a tortuous internal carotid artery at the right side of the oropharynx with an anterior mucosal projection (Fig. 1). MRI angiography showed the tortuosity of the artery in detail (Fig. 2a). Because there were no associated vascular or neurologic anomalies, no treatment was offered.

Case 2- A 75 year-old woman was referred to our department with 2 months history of a right sided upper neck mass. The mass was pulsatile and was not tender. She did not have any additional complaints such as neck pain and headache. Her neurological examination including the cranial nerves displayed normal findings. Because of the pulsatile character of the mass a Doppler USG was obtained that revealed a high fluid flow within the mass, suggestive of an internal carotid aneurysm. Digital angiography confirmed the diagnosis and demonstrated the saccular pattern of the lesion (Fig. 2b). The patient refused any surgery and an antiplatelet treatment was started.

DISCUSSION

The head and neck region can harbor many lesions originating from almost every kind of tissue. Misdiagnosis of carotid anomalies or unexpected injury during surgery may cause fatal complications.

The incidence of carotid aneurysms is extremely rare and they account for less than 0.05% of all aneurysms of all locations.^[1] They most frequently originate from common and internal carotid arteries. The most common causes are atherosclerosis and trauma but they can occur in patients with infectious (syphilis, tuberculosis, AIDS, mycosis) and systemic angiopathic diseases (fibromuscular dysplasia, cystic medial necrosis, Marfan's syndrome, Takayasu arteritis).

Classical presentation of an extracranial carotid aneurysm is a pulsatile superior cervical mass with

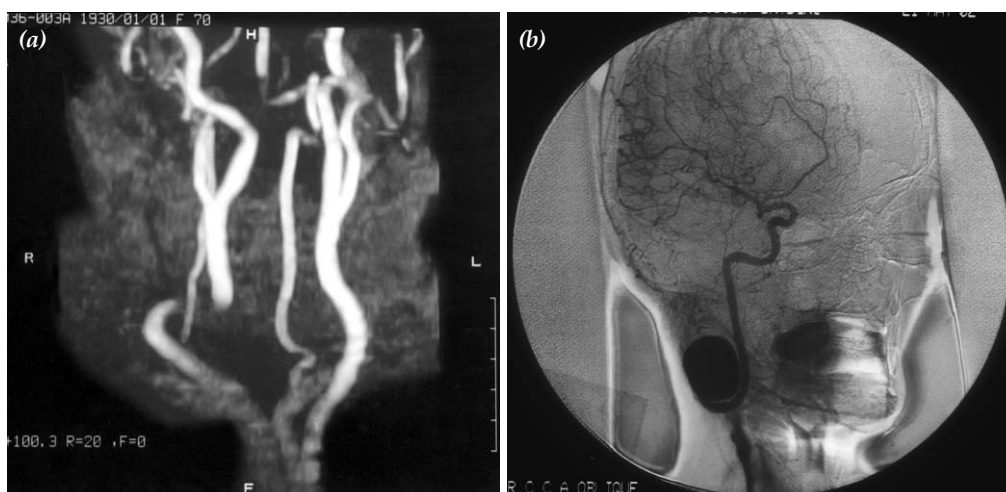


Fig. 2 - (a) MRI angiography demonstrating the medial displacement of tortuous internal carotid artery. (b) Digital angiography demonstrating the saccular aneurysm of right internal carotid artery.

unilateral headache and cephalad radiating neck pain.^[2] They can originate from nasopharynx,^[3] pharynx^[4] or can imitate a peritonsillar abscess.^[5] Neurological symptoms can occur secondary to emboli and thrombus formation or direct nerve compression by the expanding aneurysm.^[2] Differential diagnosis must be established with the other causes of neck and oropharyngeal masses, in the case of a pulsatile mass an aneurysm should be suspected, and aspiration or biopsy should be avoided.

Diagnosis of a carotid aneurysm may be made by noninvasive methods such as CT angiography and MR Angiography (MRA) but Digital Angiography is the gold standard and especially important when a surgery is planned.

In symptomatic aneurysms of the extracranial carotid aneurysms, surgery is indicated and, ligation, direct arterial repair by lateral suture for a small saccular aneurysm, transposition of external carotid artery to ICA, end-to-end anastomosis, vein grafting, and use of PTFE and Dacron prosthesis have been described.^[6] If surgery is not feasible, the patient should use anticoagulant or antiplatelet therapy for prevention of thromboembolic events.

Tortuosity of internal carotid artery is a relatively common abnormality^[7] and it may be congenital or caused by atherosclerosis. They may cause throbbing or sore throat, but they are usually asymptomatic.

Internal carotid artery tortuosity is especially important in routine oropharyngeal surgery. In a review of the literature, four cases of injury of the internal carotid artery during adenoidectomy were reported, two with a fatal outcome.^[8] In addition, bleeding from a tortuous internal carotid artery during tonsillectomy is believed to be more frequent.^[8] Furthermore, tortuous internal carotid artery can possess a risk especially when a concurrent oropharyngeal infection is present. Misdiagnosing a tortuous

internal carotid artery as a peritonsillar or retropharyngeal abscess is not so difficult and aspiration of the suspected abscess before a surgical attempt prevents a disaster.

The algorithm of diagnosis of a suspected internal carotid artery tortuosity is similar to aneurysms. However, their treatment is more conservative unless they have neurological complications. If a tortuous carotid is diagnosed during an oral examination or accidentally by radiology, the patient should be warned about this situation.

Internal carotid artery pathologies of the extracranial cavity are a threat for otolaryngologists. These entities must be kept in mind in the evaluation of oropharyngeal and neck masses and even in routine surgeries such as tonsillectomy and adenoidectomy.

REFERENCES

1. McCollum CH, Wheeler WG, Noon GP, DeBakey ME. Aneurysms of the extracranial carotid artery. Twenty-one years' experience. *Am J Surg* 1979;137:196-200.
2. Cunningham MJ, Rueger RG, Rothfus WE. Extracranial carotid artery aneurysm: an unusual neck mass in a young adult. *Ann Otol Rhinol Laryngol* 1989;98(5 Pt 1):396-9.
3. Hsu RF, Su CY, Chien CY, Liu CM. Internal carotid artery aneurysm presenting as an unusual nasopharyngeal mass. *Ann Otol Rhinol Laryngol* 1998;107:536-9.
4. Yoshizaki T, Teranishi S, Matsui O, Furukawa M. Internal carotid artery aneurysm presenting as a large pharyngeal mass. *Ann Otol Rhinol Laryngol* 2000;109:690-2.
5. Thomas JA, Ware TM, Counselman FL. Internal carotid artery pseudoaneurysm masquerading as a peritonsillar abscess. *J Emerg Med* 2002;22:257-61.
6. Nair R, Robbs JV, Naidoo NG. Spontaneous carotid artery aneurysms. *Br J Surg* 2000;87:186-90.
7. Okami K, Onuki J, Ishida K, Kido T, Takahashi M. Tortuosity of the internal carotid artery-report of three cases and MR-angiography imaging. *Auris Nasus Larynx* 2001;28:373-6.
8. Sichel JY, Chisin R. Tortuous internal carotid artery: a rare cause of oropharyngeal bulging diagnosed by magnetic resonance angiography. *Ann Otol Rhinol Laryngol* 1993;102:964-6.