

CASE REPORT

Bilateral hypoglossal schwannoma: a radiologic diagnosis

İki taraflı hipoglossal schwannom: Radyolojik tanı

Devrim BEKTAŞ, M.D., Refik ÇAYLAN, M.D.

A 53-year-old woman presented with a complaint of a sore throat. Examination showed a left-sided atrophy of the tongue. Upon protrusion, the tongue deviated to the left, suggestive of a unilateral hypoglossal nerve palsy. Computed tomography revealed enlarged hypoglossal canals. Magnetic resonance imaging (MRI) demonstrated bilateral hypoglossal canal masses, with enhancement following gadolinium administration. Magnetic resonance angiography and MRI with fat suppression revealed nonvascular masses in both hypoglossal canals. Radiological diagnosis of bilateral hypoglossal nerve schwannoma was made and the patient was scheduled for MRI monitoring with six-month intervals. The size of the masses and the clinical manifestations remained unchanged during a two-year follow-up period.

Key Words: Hypoglossal nerve/radiography; magnetic resonance imaging; neurilemmoma/radiography; tomography, x-ray computed.

Elli sekiz yaşındaki kadın hasta polikliniğimize boğaz ağrısı şikayetiyle başvurdu. Hastanın dilinin sol tarafında atrofi olduğu görüldü. Dilin protrüzyon sırasında sol tarafa kayma göstermesi tek taraflı hipoglossal sinir güçsüzlüğünü gösteriyordu. Bilgisayarlı tomografide her iki hipoglossal kanalın genişlemiş olduğu görüldü. Manyetik rezonans görüntülemesinde (MRG), kontrast madde tutan iki taraflı hipoglossal kanal kitleleri görüldü. Manyetik rezonans anjiyografi ve MRG yağ supresyon tekniklerinde hipoglossal kanallarda avasküler kitle görünümleri izlendi. Radyolojik olarak iki taraflı hipoglossal schwannom tanısı kondu ve hasta altı aylık aralıklarla MRG ile izlendi. İki yıllık izlem süresince kitle büyüklüklerinde ve hastanın şikayetlerinde bir değişme gözlenmedi.

Anahtar Sözcükler: Hipoglossal sinir/radyografi; manyetik rezonans görüntüleme; nörolemmoma/radyografi; bilgisayarlı tomografi.

The hypoglossal canal in the cranial base houses the twelfth cranial nerve and the lesions affecting this region generally originate from the nearby jugular foramen. The primary lesions of this area vary; however, neural tumors such as schwannomas originating from the hypoglossal nerve seem to predominate.^[1] Schwannomas are benign tumors arising from Schwann cells of nerve roots;

the most frequent sites being the eighth and fifth cranial nerves. They most commonly arise from the sensory division of cranial nerves; if the motor division is involved, there is often evidence for Recklinghausen's disease.^[2] To our knowledge, there has been no report of bilateral hypoglossal schwannoma in a patient with or without neurofibromatosis.

♦ Department of Otolaryngology, Medicine Faculty of Karadeniz Technical University Farabi Hospital (Karadeniz Teknik Üniversitesi Tıp Fakültesi Farabi Hastanesi Kulak Burun Boğaz Hastalıkları Anabilim Dalı), Trabzon, Turkey.

♦ Received - February 19, 2003 (Dergiye geliş tarihi - 19 Şubat 2003). Accepted for publication - June 6, 2003 (Yayın için kabul tarihi - 6 Haziran 2003).

♦ Correspondence (İletişim adresi): Dr. Refik Çaylan. Karadeniz Teknik Üniversitesi Tıp Fakültesi Farabi Hastanesi Kulak Burun Boğaz Hastalıkları Anabilim Dalı, 61080 Trabzon, Turkey. Tel: +90 462 - 325 30 18 / 5548 Fax (Faks): +90 462 - 325 83 24 e-mail (e-posta): refikcaylan@yahoo.com

* Presented at the 26th National Congress of Turkish Otorhinolaryngology Head and Neck Surgery, September 22-26, 2001(26. Ulusal Türk Otorinolarenoloji ve Baş-Boyun Cerrahisi Kongresi'nde sunulmuştur, 22-26 Eylül 2001) Antalya, Turkey.

CASE REPORT

A 53-year-old woman was admitted to our clinic with a sore throat of three-day history. Examination revealed exacerbation of chronic pharyngitis and atrophy of the left side of the tongue. The tongue deviated to the ipsilateral side during protrusion. She was aware of the atrophy, but she did not seek medical advice. Neurological examination of other cranial nerves and EEG were normal. Computed

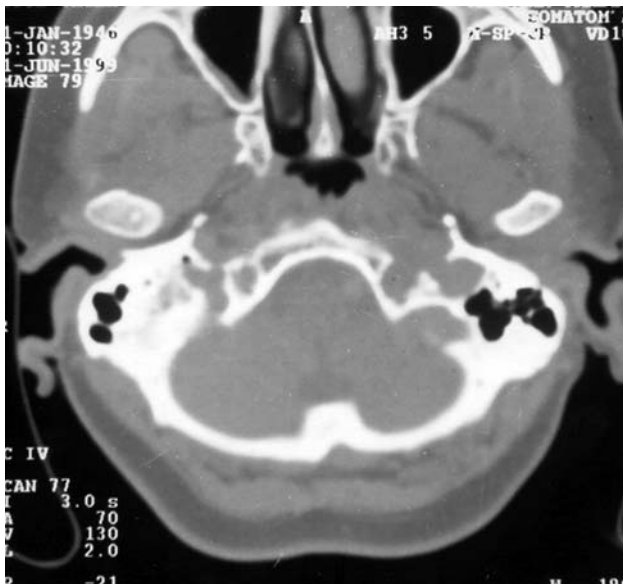


Fig. 1 - A computed tomography scan showing bilateral enlargement of the hypoglossal canals.

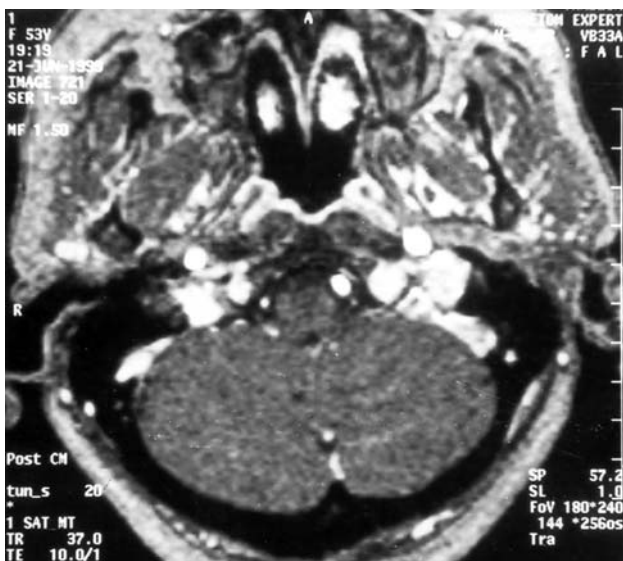

Fig. 2 - Magnetic resonance imaging with gadolinium shows bilateral enhancement of the hypoglossal canal lesions (1 x 0.8 cm on the left and 1 x 0.5 cm on the right).

tomography (CT) in bone window revealed expansion of both hypoglossal canals (Fig. 1). Magnetic resonance imaging (MRI) showed bilateral masses located at the area of hypoglossal canals. The masses were hypointense relative to the brain on T₁-weighted spin-echo scans and hyperintense on T₂-weighted scans. There was a homogeneous enhancement following gadolinium administration. Magnetic resonance angiography demonstrated nonvascular character of the masses (Fig. 2). Magnetic resonance imaging with fat suppression showed that both of the masses were intracanalicular and they were not related with the jugular foramina (Fig. 3). A diagnosis of bilateral hypoglossal schwannoma was established radiologically. Family history and systemic examination did not provide any evidence for neurofibromatosis. Genetic counseling was reported as insignificant. The patient refused any surgery or gamma-knife surgery and was, therefore, scheduled for follow-up MRI scans every six-months. During a two-year follow-up period, the size of the bilateral tumors and her clinical complaints remained unchanged.

DISCUSSION

Schwannomas (neurilemmoma, neurinoma, neuroma) are benign tumors arising from Schwann cells. They may originate from any of the cranial or spinal roots except for the olfactory and optic nerves. Approximately 30% to 50% of all schwannomas arise

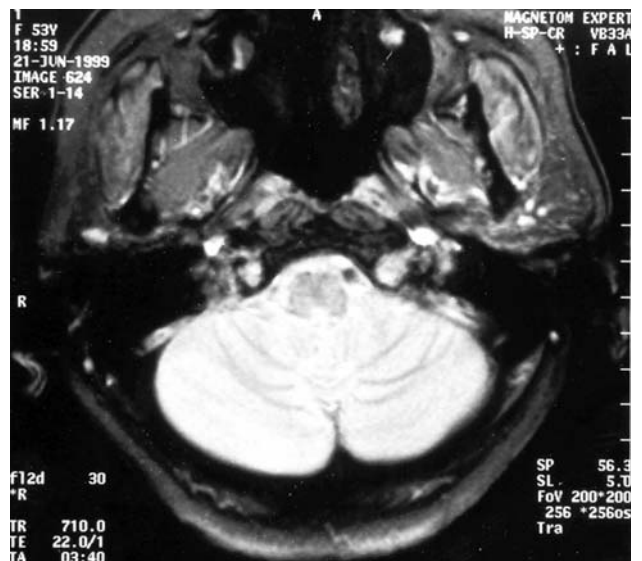

Fig. 3 - Magnetic resonance imaging with fat suppression provided a more detailed appearance of the hypoglossal canal masses.

in the head and neck region. Intracranial schwannomas account for 8% of intracranial neoplasms.^[2] Schwannomas of the vestibulocochlear nerve are by far the most common intracranial schwannomas, followed by trigeminal and facial nerve involvement. Multiple schwannomas are characteristic in central neurofibromatosis.

In a review in 1996, Sato et al.^[1] reported only 35 hypoglossal schwannomas in the literature. They are more often seen in middle-aged women, but they may occur at any age. The median age at diagnosis was found as 43 years.^[2] Hypoglossal schwannomas may be intracranial or extracranial or be "dumbbell"-shaped, extending into both spaces. Due to their slow-growing nature, the onset of the symptoms may take a long time, as long as 10 years.^[3] Although ipsilateral hemiatrophy and weakness of the tongue is almost invariable, the patients usually neglect this symptom. In hypoglossal schwannoma, the most common complaint is localized or diffuse pain in the neck or head region.^[2,3] When they grow enough to compress adjacent structures, they may cause quite a diverse number of symptoms. They may cause compression on other caudal cranial nerves, intracranial blood vessels, the cerebellum and medulla. The vagus nerve is the most commonly affected cranial nerve. Symptoms due to dysfunction of other lower cranial nerves such as the 6th, 7th, 8th, 9th and 11th cranial nerves occur less often.^[3] Disturbances of gait, dysphagia, vertigo, hoarseness, ataxia, nystagmus, hyperreflexia are some of the associated symptoms.

Although in almost every case ipsilateral hemiatrophy and weakness of the tongue is reported, patients rarely complain about this condition because unilateral dysfunction of the hypoglossal nerve does not significantly impair the function of the tongue. Our patient was aware of the problem in her tongue, but did not consider it important. In our case, also was there a right-sided mass filling the hypoglossal canal. However, this did not lead to any symptoms or signs. Mariniello et al.^[4] also reported a similar case without symptoms of hypoglossal nerve palsy.

The differential diagnosis of the lesion was made radiologically with consideration given to the typical lesions of this region including chemodectoma, chordoma, hemangiopericytoma, hemangioblastoma, meningioma, glomus tumors, myxofibrosarcoma, metastatic diseases, lymphoma, epidermoid cysts, aneurysms of the internal carotid artery, and primary bone diseases.^[2,5,6] The radiologic diagnosis of intracranial hypoglossal schwannoma is based on the finding of widening or erosion of the hypoglossal canal, that may extend to the occipital condyle. The typical character of the mass on CT or MRI scans can provide radiologic diagnosis.^[5,7] They are frequently solid. Areas of cystic changes may be seen in large lesions. In our case, the masses presented as typical, low-signal lesions on T₁-weighted images and high-signal on T₂-weighted images. Enhancement was avid and homogeneous. Magnetic resonance imaging with fat suppression and CT scans clearly defined that the masses were not related to the jugular foramina and that they were obviously intracanalicular.

REFERENCES

1. Sato M, Kanai N, Fukushima Y, Matsumoto S, Tatsumi C, Kitamura K, et al. Hypoglossal neurinoma extending intra- and extracranially: case report. *Surg Neurol* 1996;45:172-5.
2. Berger MS, Edwards MS, Bingham WG. Hypoglossal neurilemmoma: case report and review of the literature. *Neurosurgery* 1982;10:617-20.
3. Tuck RR, Mokri B, Cilluffo JM. Intracranial schwannoma of the hypoglossal nerve. *Arch Neurol* 1984;41:502-5.
4. Mariniello G, Horvat A, Popovic M, Dolenc VV. Cellular dumbbell schwannoma of the hypoglossal nerve presenting without hypoglossal nerve palsy. *Clin Neurol Neurosurg* 2000;102:40-3.
5. Bettoni L, Baldi P, Bertolino G. CT diagnosis of intracranial neurinoma of the hypoglossal nerve. *J Comput Assist Tomogr* 1985;9:827-8.
6. Myatt HM, Holland NJ, Cheesman AD. A skull base extradural hypoglossal neurilemmoma resected via an extended posterolateral approach. *J Laryngol Otol* 1998;112:1052-7.
7. Okura A, Shigemori M, Abe T, Yamashita M, Kojima K, Noguchi S. Hemiatrophy of the tongue due to hypoglossal schwannoma shown by MRI. *Neuroradiology* 1994;36:239-40.