

CASE REPORT

Hemangioma of the nasal bone: a case report

Nazal kemik hemanjiomu: Olgu sunumu

Eksal KARGI, M.D., Orhan BABUCCU, M.D., Mubin HOŞNUTER, M.D., Berfu BABUCCU, M.D.

Hemangiomas of the bone account for 0.7% of all bone tumors. The craniofacial region is a rare site of involvement, with the mandible, zygoma, and maxilla being the most frequently affected areas. Hemangioma of the nasal bone is very rare. A 60-year-old male patient presented with complaints of difficult breathing through the nasal airway and a slowly growing hard mass at the nasion with a history of 10 years. Computed tomography demonstrated a round mass involving the left nasal bone with submucosal extension. An *en bloc* excision of the mass and its extension was performed. Histopathological examination showed two neighboring tumors, cavernous hemangioma of the bone and arteriovenous malformation of the nasal mucosa. During a-year follow-up, the patient had no complaints and the functional and cosmetic results were excellent.

Key Words: Hemangioma, cavernous/surgery; nasal bone/pathology; nose neoplasms/surgery.

Kemik hemanjiomları tüm kemik tümörlerinin %0.7'sini oluşturmaktadır. Yüz kemiklerinde bulunan hemanjiomlar nadir olmakla birlikte, en sık maksilla, mandibula ve zigomada görülür. Nazal kemikte hemanjiom çok nadir görülmektedir. Altmış yaşındaki erkek hasta burun sırtında kitle ve burundan nefes alma sorunları ile kliniğimize başvurdu. Kitlenin 10 yıldır var olduğu ve bu süre içinde boyutlarının giderek arttığı öğrenildi. Bilgisayarlı tomografide submukozal uzanım gösteren nazal kemik kaynaklı kitle saptandı. Sol nazal kemiği kaplayan kitle ve mukozal uzanımı tamamen çıkarıldı. Patolojik incelemede nazal kemikte kavernöz hemanjiom ve nazal mukozada arteriyovenöz malformasyon olmak üzere komşu iki tümöral yapı saptandı. Hastanın bir yıllık izleminde şikayeti olmadı, ameliyat sonrası fonksiyonel ve kozmetik sonuçlar mükemmeldi.

Anahtar Sözcükler: Hemanjiom, kavernöz/cerrahi; nazal kemik/patoloji; burun neoplazileri/cerrahi.

Hemangioma of bone comprises 0.7% of all bone tumors.^[1,2] Bone hemangiomas most frequently involve vertebrae and skull.^[2] Hemangioma of facial bones are uncommon. The mandible, zygoma, maxilla and frontal bone are the most frequent areas of localization in the craniofacial region.^[3,4] The etiology of nasal bone hemangioma is not clear, but trau-

ma can be a predisposing factor.^[1,2,5] Hormonal factors have been implicated, however their role is unclear.^[1,2] The female to male ratio is approximately 2:1.^[1,5] Hemangioma is frequently seen in early decades of life.^[6] Our patient was a male and older with nasal bone involvement, contradictory to the data given above.

- ◆ Department of Plastic and Reconstructive Surgery, Medicine Faculty of Zonguldak Karaelmas University (Zonguldak Karaelmas Üniversitesi Tıp Fakültesi Plastik ve Rekonstrüktif Cerrahi Anabilim Dalı), Zonguldak, Turkey.
- ◆ Received - November 19, 2003 (Dergiye geliş tarihi - 19 Kasım 2003). Request for revision - July 22, 2004 (Düzeltilme isteği - 22 Temmuz 2004). Accepted for publication - September 17, 2004 (Yayın için kabul tarihi - 17 Eylül 2004).
- ◆ Correspondence (İletişim adresi): Dr. Eksal Kargı, Zonguldak Karaelmas Üniversitesi Tıp Fakültesi Plastik ve Rekonstrüktif Cerrahi Anabilim Dalı, 67600 Kozlu, Zonguldak, Turkey. Tel: +90 372 - 261 01 69 Fax (Faks): +90 372 - 261 01 55 e-mail (e-posta): eksalk@superonline.com

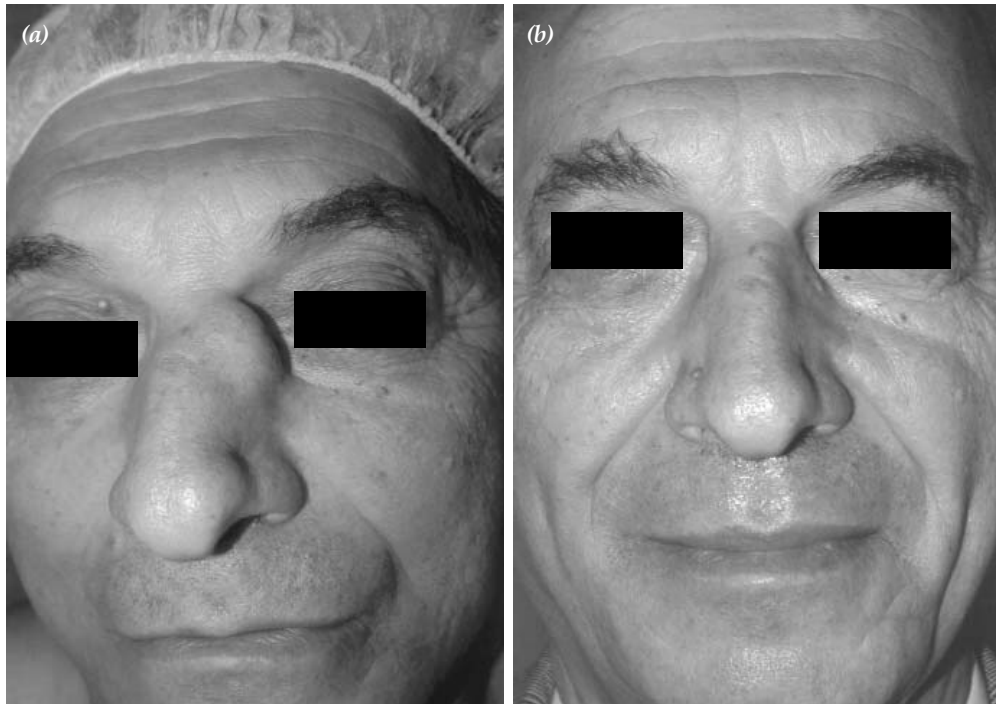


Fig. 1 - (a) Appearance of the lesion preoperatively. (b) Appearance of the patient postoperatively.

CASE REPORT

A 60-year-old male patient presented with a slowly growing hard mass for over 10 years at the nasion (Fig. 1a). There was no history of trauma, epistaxis and pain. His major complaints were respiratory problems and cosmetic appearance. Physical examination revealed a firm lesion, which was fixed to the underlying bone, 3x2x2 cm in size. The mass was covered with normal skin and no tenderness was recorded with palpation. Intranasal examination revealed an extension of the purple-red mass into the left nasal cavity causing airway obstruction. CT scan demonstrated a round mass expanding left nasal bone with submucosal extension and (Fig. 2). The other cross-sections of the scan showed that destruction of the left nasal bone. The nasal septum was deviated to the right side. Under general anesthesia, the tumor was approached through a vertical nasal incision at the nasal dorsum. The solid mass expanding the left nasal bone and its extension into the nasal cavity was excised en bloc. A nasal lining was provided with local turnover flaps and a bone graft from iliac crest was used for reconstruction of the bone defect. Histopathological examination showed two neighboring tumors; cavernous hemangioma of the bone

and arteriovenous malformation of the nasal mucosa. The patient has had no complaints for one year postoperatively and has been satisfied with the cosmetic end result (Fig. 1b).

DISCUSSION

Nasal bone hemangioma clinically presents as slowly enlarging firm mass at the nasion and are usually 1-2 cm in diameter.^[1,2,5] Characteristic fea-

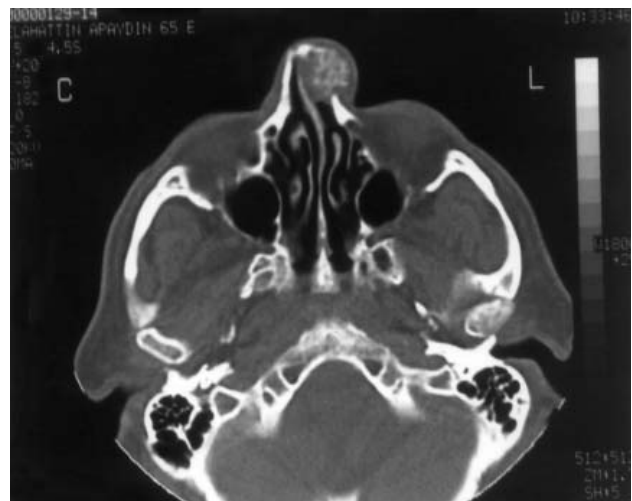

Fig. 2 - The preoperative CT scan of the lesion.

tures of the nasal bone hemangioma in plain roentgenograms are “soap bubble” pattern with spicules of bone radiating in a “sunburst” fashion.^[1,5] However, plain films are generally not helpful for diagnosis due to complex anatomic locations of facial bones. Axial and coronal sections of CT scans are more reliable for easy and precise diagnosis.^[1,2,4] Most of the nasal bone hemangiomas are cavernous type with histological features of endothelial-lined vascular spaces interspersed with bone spicules and collagenous connective tissue and the intact overlying periosteum.^[5] The nasal mucosa is generally normal although intranasal submucosal extension of the tumor is described.^[2] There are many therapeutic approaches to bony hemangioma; including the use of steroids, radiotherapy, and curettage, embolization of the main afferent vessels, complete surgical excision, and immediate reconstruction.^[1,3,4,6] Reconstructive methods include autologous bone or cartilage grafts including iliac, costal, cranial bones and tibia.^[3,5,6] Embolization of the afferent vessel of the hemangioma is a treatment of choice for patients who have a contraindication for surgery.^[3,7-9] Differential diagnosis for nasal bone hemangiomas include nasal dermoids, malignant osteogenic sarcoma, fibrous dysplasia, and osteolytic malignancies.^[1,2,6]

We performed en bloc excision of the tumorous mass and its extension; after the removal, bone graft of iliac crest was carved to fit into nasal bony defect for reconstruction. In our patient, the mucosal involvement was thought to be an extension of the

tumor preoperatively. Microscopically, it was shown to be an arteriovenous malformation of the nasal mucosa. In our extensive literature research, we were not able to find reported case of the neighboring of two entities, namely nasal bone hemangioma and arteriovenous malformation of the nasal mucosa.

REFERENCES

1. Bridger MW. Haemangioma of the nasal bones. *J Laryngol Otol* 1976;90:191-200.
2. Karacaoglan N, Akbas H, Eroglu L, Turan N, Demir A, Yavuz I. Hemangioma of the nasal bones. *Ann Plast Surg* 1997;39:218-9.
3. de Ponte FS, Bottini DJ, Valentini V. Surgical treatment of hemangioma of bones of the orbito-zygomatic region *Minerva Stomatol* 1994;43:365-72. [Abstract]
4. Sary A, Yavuzer R, Latfoglu O, Celebi MC. Intraosseous zygomatic hemangioma. *Ann Plast Surg* 2001;46:659-60.
5. Bise RN, Jackson IT, Fukuta K, Smit R. Nasal bone haemangiomas: rare entities treatable by craniofacial approach. *Br J Plast Surg* 1991;44:206-9.
6. Adanali G, Ayhan M, Gorgu M, Erdogan B. Nasal bone destruction by a cavernous hemangioma in an elderly patient. *Ann Plast Surg* 2001;47:216-7.
7. Krastinova-Lolov D, Roddi R. An intracranial/extracranial approach for the surgical management of haemangiomas of the orbit and eyelid. *J Craniomaxillofac Surg* 1989;17:197-205.
8. Guibert-Tranier F, Piton J, Riche MC, Merland JJ, Caille JM. Vascular malformations of the mandible (intraosseous haemangiomas). The importance of preoperative embolization. A study of 9 cases. *Eur J Radiol* 1982;2:257-72.
9. Webb CJ, Porter G, Spencer MG, Sissons GR. Cavernous haemangioma of the nasal bones: an alternative management option. *J Laryngol Otol* 2000;114:287-9.