

# Cartilage tympanoplasty with island technique for reconstruction of tympanic membrane perforation: anatomic and audiologic results

## Kulak zarı perforasyonu onarımında ada tekniği ile kartilaj timpanoplastisi: Anatomik ve işitsel sonuçlar

Çağatay Han Ülkü, M.D.

*Department of Otolaryngology, Medicine Faculty of Selçuk University, Konya, Turkey*

**Objectives:** The aim of this study was to evaluate anatomic/audiologic outcomes of cartilage tympanoplasty with island technique and compare the results with the results of temporalis fascia tympanoplasty.

**Patients and Methods:** The charts of 40 patients who underwent surgery for primary type 1 tympanoplasty either with perichondrium-cartilage (12 males, 11 females; mean age 29.7 years; range 12 to 58 years) or fascia graft (9 males, 8 females; mean age 32.4 years; range 13 to 61 years) between January 2006 and January 2008 were retrospectively reviewed. Patients in whom the only pathology was subtotal tympanic membrane perforation with intact ossicular chain were included in the study. Pre- and postoperative audiograms, postoperative otoscopy findings and follow-up time were obtained from the patient's chart in both groups. Reviewed parameters were the complete closure rates of the tympanic membrane perforation and the change in air bone gap at each of four frequencies (0.5, 1, 2, 4 kHz). Audiologic evaluation was made among the patients in whom complete ear drum closure was achieved in both groups.

**Results:** Anatomic closure rates of the tympanic membrane perforation for perichondrium-cartilage and fascia group were 91.3% and 88.2%, respectively. Pre- and postoperative pure tone average air bone gap obtained at four frequencies for the perichondrium-cartilage and fascia group were 21.3±6.7 dB, 9.0±3.9 dB, and 21.2±6.9 dB, 8.5±4.4 dB, respectively. These findings revealed the overall gains of 12.3 dB for the cartilage-perichondrium group and 12.7 dB for the fascia group ( $p>0.05$ ).

**Conclusion:** The anatomic and audiologic results after cartilage tympanoplasty with island technique are comparable to those after temporalis fascia tympanoplasty. Furthermore, the cartilage is more resistant than the fascia to the anatomic deformation and necrosis. Therefore, we advise its use as a routine tympanic membrane reconstruction material without concern about effecting audiometric results.

**Key Words:** Cartilage; perforation; tympanic membrane; tympanoplasty.

**Amaç:** Ada tekniği ile yapılan kartilaj timpanoplastisinin anatomik/işitsel verileri değerlendirildi ve sonuçlar temporal fasya timpanoplastisi sonuçları ile kıyaslandı.

**Hastalar ve Yöntemler:** Ocak 2006 - Ocak 2008 tarihleri arasında kliniğimizde perikondriyum kartilaj (12 erkek, 11 kadın; ort. yaş 29.7 yıl; dağılım 12-58 yıl) ya da temporal fasya grefti (9 erkek, 8 kadın; ort. yaş 32.4 yıl; dağılım 13-61 yıl) ile primer tip 1 timpanoplasti ameliyatı uygulanan 40 hastanın dosyası geriye dönük olarak incelendi. Çalışmaya, tek patolojisi sağlam kemikcik zinciri ile birlikte subtotal kulak zarı perforasyonu olan hastalar dahil edildi. Hasta dosyalarından, her iki grup için ameliyat öncesi ve sonrası odyogramlar, ameliyat sonrası otoskopi bulguları ve takip süreleri elde edildi. Değerlendirilen parametreler, kulak zarı perforasyonu kapanma yüzdeleri ve her dört frekans (0.5, 1, 2, 4 kHz) için kemik hava yolu açıklığındaki değişikliklerdi. İşitsel değerlendirme, her iki grup için kulak zarında tam kapanma olan hastalar arasında yapıldı.

**Bulgular:** Kulak zarı perforasyonunun anatomik kapanma oranları, perikondriyum kartilaj ve fasya gruplarında sırası ile %91.3 ve %88.2 idi. Dört frekans için ameliyat öncesi ve sonrası elde edilen pür ton ortalama hava kemik aralığı ise perikondriyum kartilaj ve fasya grupları için sırası ile 21.3±6.7 dB, 9.0±3.9 dB ve 21.2±6.9 dB, 8.5±4.4 dB olarak belirlendi. Bu sonuçlar, ortalama kazancın perikondriyum kartilaj grubunda 12.3 dB ve fasya grubunda ise 12.7 dB olduğunu gösterdi ( $p>0.05$ ).

**Sonuç:** Ada tekniği ile yapılan primer tip 1 kartilaj timpanoplastisi sonrası elde edilen anatomik ve işitsel sonuçları, primer tip 1 temporal kas fasya timpanoplastisi sonuçları ile kıyaslanabilir. Ayrıca kartilaj anatomik deformasyon ve nekroza karşı fasyadan daha dirençlidir. Bu nedenle işitsel sonuçları etkileme kaygısı olmadan kulak zarı onarımında rutin kullanımını öneriyoruz.

**Anahtar Sözcükler:** Kartilaj; perforasyon; timpanik membran; timpanoplasti.

Received / *Geliş tarihi:* July 3, 2009 Accepted / *Kabul tarihi:* December 31, 2009

*Correspondence / İletişim adresi:* Çağatay Han Ülkü, M.D. Selçuk Üniversitesi Meram Tıp Fakültesi Kulak Burun Boğaz Hastalıkları Anabilim Dalı, 42100 Meram, Konya, Turkey.

Tel: +90 332 - 223 72 50 Fax (Faks): +90 332 - 323 26 43 e-mail (e-posta): chanulku@yahoo.com

Presented at the 8<sup>th</sup> International Conference on Cholesteatoma and Ear Surgery (oral presentation), June 15-20, 2008, Antalya, Turkey.  
8. Uluslararası Kolesteatom ve Kulak Cerrahisi Konferansı'nda sözlü bildiri olarak sunulmuştur, 15-20 Haziran 2008, Antalya, Türkiye.

Different techniques and materials have been used in tympanoplasty since 1952.<sup>[1,2]</sup> Temporalis fascia is the most frequently used material.<sup>[3]</sup> Reconstruction of the tympanic membrane with the tragal or conchal cartilage grafts is called cartilage tympanoplasty. It became increasingly popular during last two decades.<sup>[4]</sup> In general, indications for cartilage use in tympanoplasty have been reserved for retraction pockets, atelectatic ears and posterior canal wall reconstruction.<sup>[5]</sup> There are many described techniques for cartilage tympanoplasty such as cartilage palisade tympanoplasty, composite auto graft shield, perichondrium island graft, cartilage butterfly inlay graft, cartilage mosaic tympanoplasty and cartilage reinforcement tympanoplasty.<sup>[4,6]</sup>

The aim of this study is to evaluate the anatomic and audiologic results in cases of primary type 1 cartilage tympanoplasty with island technique, and compare those with results after primary type 1 temporalis fascia tympanoplasty.

#### PATIENTS AND METHODS

The charts of 40 patients who underwent surgery for type 1 tympanoplasty either with perichondrium-cartilage (12 males, 11 females; mean age 29.7 years; range, 12 to 58 years) or fascia (9 males and 8 females; mean age 32.4 years; range, 13 to 61 years) graft from January 2006 to January 2008 were retrospectively reviewed. Because of preoperative disease severity of the middle ear has a significant influence on prognosis, patients in whom only pathology was subtotal tympanic membrane perforation with intact ossicular chain were included in the study. All of the procedures were performed by the same surgeon. Age, sex, indications for the surgery, pre- and postoperative audiograms (at least 6 months), postoperative findings and follow-up time were obtained from the

patient's chart in both groups. Reviewed parameters were the complete closure rates of the tympanic membrane perforation and the change in air bone gap (ABG) at each of four frequencies (0.5, 1, 2, 4 kHz). Audiologic evaluation was made among the patients whom complete tympanic membrane closure was achieved in both groups. Statistical comparisons of the anatomic and audiometric data between the perichondrium-cartilage and fascia groups were performed using Student-t, Mann-Whitney U and Wilcoxon signed ranks tests.

Tragal cartilage was used in all cases. An incision through skin and cartilage was made on the medial side of the tragus. In the dome of the tragus, 2 mm cartilage strip was left intact for cosmetic purpose. The cartilage was then exposed on both surfaces and then harvested with perichondrium (Figure 1). The perichondrium-cartilage graft was prepared by elevating the perichondrium from the convex side of the cartilage. Using a round knife, cartilage was removed to produce a disc of cartilage about 6 to 9 mm in diameter for subtotal tympanic membrane (TM) reconstruction. A notch can be made on the cartilage for manibrium mallei (Figure 2). A rim of tissue was removed from the perforation edge and posterior tympanomeatal flap was then elevated. The long process of the malleus was cleaned from epithelial remnants. The cartilage island graft was placed over the malleus and under the annulus (under-overlay technique). A flap of perichondrium was draped over the posterior canal wall. The middle ear and external auditory canal were packed with gelfoam.

Under-overlay placement of the graft was also used for the temporalis fascia group.

#### RESULTS

The mean follow-up periods for the perichondrium-cartilage group and the fascia group were 14.2 months (range, 6-20 months) and 21.6 months (range 13-28 months), respectively. There was no statistically significant difference in preoperative ABG between perichondrium-cartilage and fascia groups ( $p > 0.05$ ; Student t-test; Table 1).

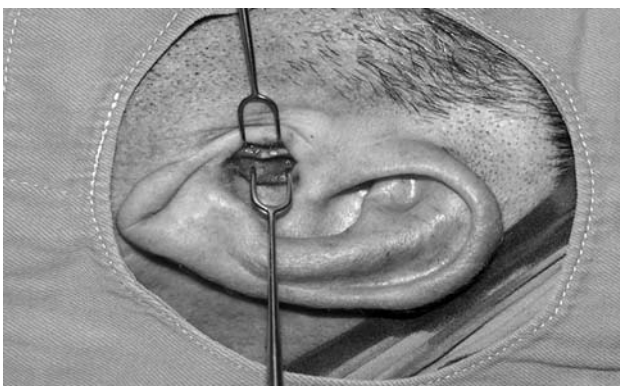


Figure 1. Tragal incision (2 mm cartilage strip was left intact).

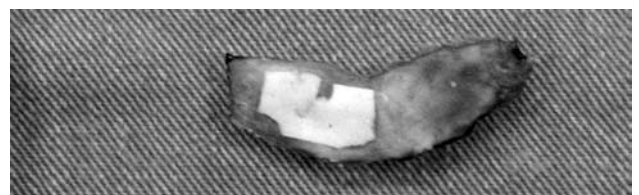

Figure 2. Perichondrium-cartilage graft.

**Table 1.** Preoperative ABG for cartilage-perichondrium and fascia groups ( $p>0.05$ ). (Student t-test) and postoperative gains of ABG for each group ( $p>0.05$ ), (Mann Whitney U-test)

	Preoperative ABG perich-cartilage	Preoperative ABG fascia	Postoperative gain in ABG perich-cartilage	Postoperative gain in ABG/fascia
500 Hz	25.0±7.8 dB	21.0±6.9 dB	16.1±7.2 dB	12.7±8.2 dB
1000 Hz	20.8±7.3 dB	22.8±6.8 dB	11.3±4.8 dB	14.8±6.5 dB
2000 Hz	19.9±7.4 dB	18.9±7.6 dB	11.8±7.4 dB	10.1±5.0 dB
4000 Hz	19.4±4.3 dB	22.1±6.2 dB	9.9±4.3 dB	13.2±5.2 dB

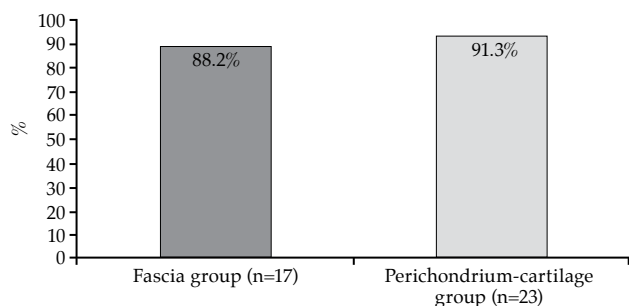
ABG: Air bone gap; Perich: Perichondrium.

Anatomic complete closure rates for the perichondrium-cartilage and the fascia group were 91.3% (21/23) and 88.2% (15/17), (Figure 3). The pre- and postoperative pure tone average (PTA)-ABG obtained at four frequencies for the perichondrium-cartilage and fascia group were 21.3±6.7 dB, 9.0±3.9 dB ( $p<0.001$ ), and 21.2±6.9 dB, 8.5±4.4 dB ( $p<0.001$ ) respectively (Wilcoxon signed ranks test; Figure 4, 5). Thus, these findings revealed the overall gains of 12.3 dB for the perichondrium-cartilage group and 12.7 dB for the fascia group ( $p>0.05$ ; Mann-Whitney U-test; Table 1; Figure 6). Closure of ABG to within 10 dB was achieved in 85.7% of the perichondrium-cartilage group and 86.7% of the fascia group whereas; closure of ABG to within 20 dB was achieved in 100% of the cases in both groups (Table 2).

### DISCUSSION

The use of cartilage for tympanic membrane or ossicular chain reconstruction, particularly in cases of advanced middle ear pathology is not a new concept.<sup>[6,7]</sup> Cartilage tympanoplasty has been well described for patients with high risk perforations such as bilateral and/or subtotal perforations, discharging ears, revision tympanoplasty, coexisting craniofacial abnormalities, atelectatic ears and cholesteatoma with excellent anatomic results.<sup>[6,8,9]</sup>

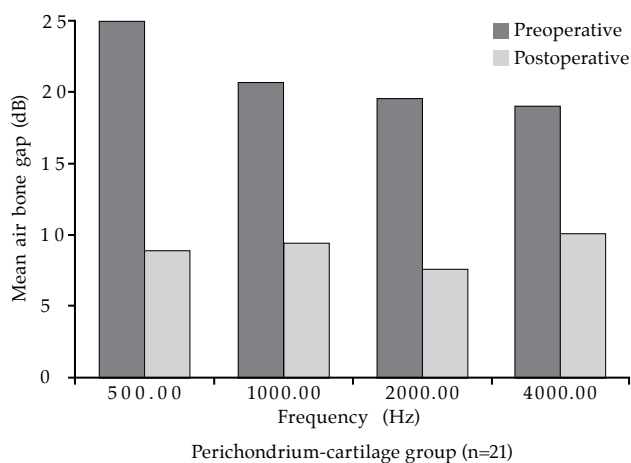
Cartilage graft harvested from concha or tragus is easy to obtain, thick, resistant to negative



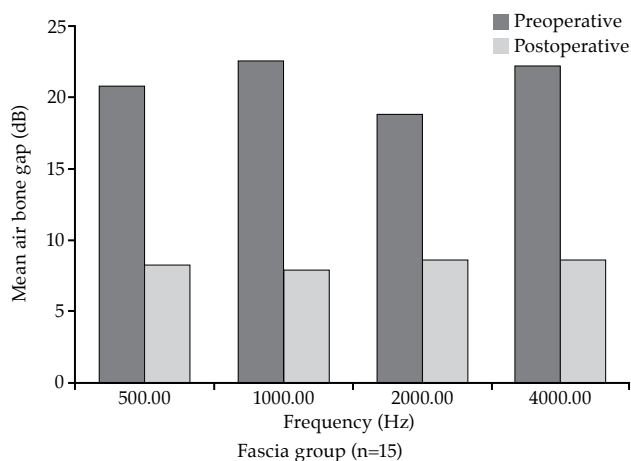
**Figure 3.** Rates of the complete tympanic membrane closure.

middle ear pressures, stable, sufficiently elastic for good sound conduction, well tolerated, resistant to resorption and convenient for shaping according to the size of the perforation.<sup>[6,7]</sup>

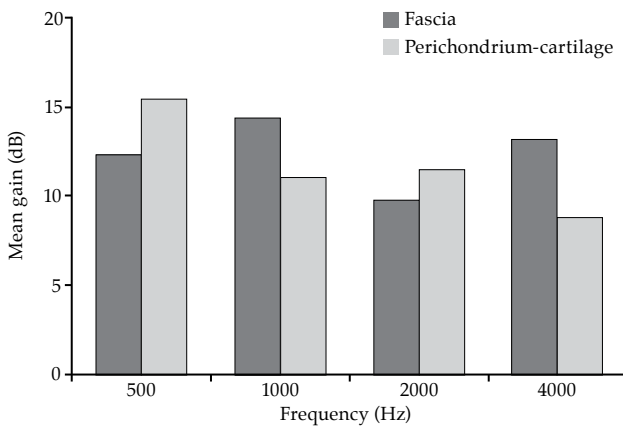
The rigid nature of the cartilage might adversely affect its acoustic transfer characteristics



**Figure 4.** Pre- and postoperative ABG for perichondrium-cartilage group ( $p<0.001$ ), (Wilcoxon signed ranks test).



**Figure 5.** Pre- and postoperative ABG for fascia group ( $p<0.001$ ), (Wilcoxon signed ranks test).



**Figure 6.** Postoperative gains of ABG for each group ( $p>0.05$ ), (Mann Whitney U-test).

theoretically. Because of that reason, cartilage graft has not been accepted widely as a routine TM reconstruction material.<sup>[7-9]</sup> However, there exist studies, demonstrating that audiologic outcomes of cartilage tympanoplasty are pretty good.<sup>[8-13]</sup>

Although absolute hearing levels were not reported, Glasscock et al.<sup>[10]</sup> notified that hearing did not appear to be adversely affected in cases with recurrent retraction pockets after cartilage tympanoplasty. Amedee et al.<sup>[11]</sup> reported complete closure of the perforation in 100% of cases, with an average postoperative ABG of 4 dB. Adkins<sup>[12]</sup> pointed out that grafting the entire posterior TM with cartilage caused in a 5 to 10 dB ABG. Levinson<sup>[13]</sup> stated that, closure of ABG to within 10 dB in 65% of cases, and to within 20 dB in 86% of cases.

Mürbe et al.<sup>[14]</sup> reported that cartilage island grafts are suitable for improving the acoustic transmission characteristics of the reconstructed TM in the experimental study. They have recommended this technique for patients who have TM perforations with adequate surrounding membrane remnants. Its acoustic properties comparable to those of fascia.<sup>[7]</sup> Because of its rigid quality, cartilage tends not to lateralize.<sup>[15]</sup>

There are a few clinical studies that compare cartilage with perichondrium or fascia with audiologic outcomes.<sup>[8,9,16,17]</sup> Dornhoffer<sup>[8,9]</sup> retrospectively reviewed the hearing results of patients after perichondrium-cartilage and perichondrium grafting. The mean postoperative improvement in average ABG of 6.8 for the perichondrium-cartilage group was comparable to that of 7.7 dB for the perichondrium group. In this study,

**Table 2.** Postoperative air bone gap levels for each group

	Postoperative ABG in Perich.-cartilage group		Postoperative ABG in fascia group	
	n	%	n	%
0-10 dB	18/21	85.7	13/15	86.7
10-20 dB	3/21	14.3	2/15	13.3

ABG: Air bone gap; Perich: Perichondrium.

perichondrium-cartilage was used in large, recurrent perforations or atelectatic tympanic membranes whereas, perichondrium was used in primary type 1 tympanoplasties or in smaller recurrent perforations.<sup>[8,9]</sup> Gerber et al.<sup>[16]</sup> reported similar outcomes in overall gain in average ABG after cartilage tympanoplasty, which is comparable to that after fascia tympanoplasty. Cartilage was used in retraction pockets, and fascia was used in simple perforation in this study.

Kirazlı et al.<sup>[17]</sup> has reviewed the audiologic results of patients after perichondrium-cartilage grafting and fascia grafting. In this study, patients who had similar middle ear pathology and similar preoperative hearing levels were selected on both groups. It was pointed out that in that way to compare the audiologic outcomes of the perichondrium-cartilage to that of fascia in identical cases would be more appropriate. An overall gain in average ABG of 11.9 dB for the perichondrium-cartilage group was comparable to that of 11.5 dB for the fascia group.<sup>[17]</sup>

Karaman et al.<sup>[18]</sup> reported the postoperative perforation closure rate as 92.85% for primary type 1 cartilage tympanoplasty with island technique in 14 patients. This rate was reported as 90% for type 1 cartilage reinforcement tympanoplasty in 30 patients by Uslu et al.<sup>[6]</sup> Cavaliere et al.<sup>[7]</sup> presented a 100% success rate for 236 primary cartilage shield tympanoplasty patients.

In our study, patients whose only pathology was subtotal tympanic membrane perforation with intact ossicular chain were selected and over-underlay technique was used for grafting in both groups. Preparation of the perichondrium cartilage graft is very easy and prolongs the operation time only to five to eight minutes. Since 2 mm cartilage strip was left intact in the dome of the tragus, we have not observed any cosmetic problems related to tragal cartilage harvesting.

Over-underlay technique's advantages are minimal risk of lateralization, no reduction of middle ear space, simple technique, very high success rate, suitable for perforations of all sizes and locations, no blunting, and superior exposure of entire middle ear. Disadvantages are slightly more complex than overlay. Moreover, there are need for malleus manipulation and theoretical risk of lateralization.<sup>[19]</sup> A potential drawback of cartilage tympanoplasty is the graft opacity and detection of the residual or recurrent cholesteatoma may be more difficult. However, the fascia is often not transparent.<sup>[7]</sup>

In this study, complete closure of the perforation was achieved in 91.3% of the perichondrium-cartilage group and 88.2% of the fascia group, where the difference was not statistically significant.

In our practice, the grafting failure for the fascia group was mainly observed at the anterior edge. Similarly, most of the failures in fascia tympanoplasty were reported as a result of detachment of graft from the anterior region in literature. This problem was rarely detected by perichondrium cartilage grafting with its rigid quality. It prevents medial detachment of the tympanic membrane. Furthermore, perichondrium-cartilage graft is more resistant than the fascia for necrosis.<sup>[6]</sup>

Pre- and postoperative PTA-ABG for type 1 cartilage shield tympanoplasty (n=100) was reported by Cavalliere et al.<sup>[7]</sup> as 38.8±1.9 and 6.4±2.2. Karaman et al.<sup>[18]</sup> reported pre- and postoperative PTA-ABG for type 1 cartilage tympanoplasty with island technique (n=14) as 35.84 and 11.66. Pre- and postoperative PTA-ABG for type 1 cartilage reinforcement tympanoplasty (n=30) was reported by Uslu et al.<sup>[6]</sup> as 38.8±11.2 and 25.4±10.6

In this study, differences between pre- and postoperative ABG at 0.5, 1, 2, 4 kHz were statistically significant for both groups. Pre- and postoperative PTA-ABG for primary type 1 cartilage tympanoplasty with island technique and temporalis fascia tympanoplasty were found as 21.3±6.7 dB, 9.0±3.9 dB, and 21.2±6.9 dB, 8.5±4.4 dB respectively. An overall gain in average ABG of 12.3 dB for the perichondrium-cartilage group was comparable to that of 12.7 dB for the fascia group. Closure of ABG to within 10 dB was achieved in 85.7% (18/21) of the perichondrium-cartilage group and 86.7% (13/15) of the fascia group whereas; closure of ABG to within 20 dB was achieved in 100% of the cases in both groups. This study represents a short-term

follow-up period and audiologic outcomes may change with time.

In conclusion, this study reveals that cartilage tympanoplasty with island technique is a reliable alternative with high rate of tympanic membrane closure and satisfying hearing results which are comparable to those after temporalis fascia tympanoplasty. Furthermore, the cartilage is more resistant than the fascia to the anatomic deformation and necrosis with long-term integrity. Therefore, we advise its use as an alternative routine TM reconstruction material without any concern of effecting audiologic results.

## REFERENCES

1. Wullstein HL. Funktionelle operationen im Mittelohr mit. Hilfe des freien Spaltlappentransplantates. Arch Otorhinolaryngol 1952;161:422-35.
2. Zollner F. The principles of plastic surgery of the sound-conducting apparatus. J Laryngol Otol 1955;69:637-52.
3. Sheehy JL, Glasscock ME 3rd. Tympanic membrane grafting with temporalis fascia. Arch Otolaryngol 1967;86:391-402.
4. Tos M. Need for clinical research in cartilage tympanoplasty. Trakya Univ Tip Fak Derg 2007;24:179-89.
5. Dornhoffer J. Cartilage tympanoplasty: indications, techniques, and outcomes in a 1,000-patient series. Laryngoscope 2003;113:1844-56.
6. Uslu C, Tek A, Tatlipinar A, Kilicarslan Y, Durmus R, Ay Oğredik E, et al. Cartilage reinforcement tympanoplasty: otological and audiological results. Acta Otolaryngol. 2009;1-9. [Epub ahead of print]
7. Cavaliere M, Mottola G, Rondinelli M, Iemma M. Tragal cartilage in tympanoplasty: anatomic and functional results in 306 cases. Acta Otorhinolaryngol Ital 2009;29:27-32.
8. Dornhoffer JL. Cartilage tympanoplasty. Otolaryngol Clin North Am 2006;39:1161-76.
9. Dornhoffer JL. Hearing results with cartilage tympanoplasty. Laryngoscope 1997;107:1094-9.
10. Glasscock ME 3rd, Jackson CG, Nissen AJ, Schwaber MK. Postauricular undersurface tympanic membrane grafting: a follow-up report. Laryngoscope 1982; 92:718-27.
11. Amedee RG, Mann WJ, Riechelmann H. Cartilage palisade tympanoplasty. Am J Otol 1989;10:447-50.
12. Adkins WY. Composite autograft for tympanoplasty and tympanomastoid surgery. Laryngoscope 1990; 100:244-7.
13. Levinson RM. Cartilage-perichondrial composite graft tympanoplasty in the treatment of posterior marginal and attic retraction pockets. Laryngoscope 1987; 97:1069-74.
14. Mürbe D, Zahnert T, Bornitz M, Hüttenbrink KB. Acoustic properties of different cartilage reconstruction techniques of the tympanic membrane. Laryngoscope 2002;112:1769-76.
15. Milewski C. Composite graft tympanoplasty in the treatment of ears with advanced middle ear pathology. Laryngoscope 1993;103:1352-6.

16. Gerber MJ, Mason JC, Lambert PR. Hearing results after primary cartilage tympanoplasty. *Laryngoscope* 2000;110:1994-9.
17. Kirazli T, Bilgen C, Midilli R, Ogüt F. Hearing results after primary cartilage tympanoplasty with island technique. *Otolaryngol Head Neck Surg* 2005; 132:933-7.
18. Karaman E, Yılmaz S, Öğreden Ş, Acioğlu E, Enver Ö. Tragal kıkırdak timpanoplasti sonuçlarımız. *Cerrahpaşa Tıp Dergisi* 2007;38:43-5.
19. Kartush JM, Michaelides EM, Becvarovski Z, LaRouere MJ. Over-under tympanoplasty. *Laryngoscope* 2002; 112:802-7.