



# Is there any relationship between the frontal cell and the Agger nasi cell and the localization of the anterior ethmoid artery?

## Frontal hücre ve Agger nasi hücresi ile anterior etmoid arter yerleşim yeri arasında ilişki var mıdır?

Filiz Aydoğan, M.D.,<sup>1</sup> Selda Demir, M.D.,<sup>2</sup> Emine Aydın, M.D.,<sup>1</sup> Eren Taştan, M.D.,<sup>1</sup> Ali Kavuzlu, M.D.<sup>3</sup>

*Department of Otolaryngology, Ankara Training and Research Hospital, Ankara, Turkey;*

*<sup>2</sup>Department of Radiology, Türkiye Yüksek İhtisas Training and Research Hospital, Ankara, Turkey;*

*<sup>3</sup>Department of Otorhinolaryngology, Polatlı State Hospital, Ankara, Turkey*

**Objectives:** In this article, we examined the effect of the presence or absence of a frontal cell or an Agger nasi cell on the localization of the anterior ethmoid artery.

**Patients and Methods:** Coronal paranasal sinus computed tomography scans on 110 sides of 61 patients (35 males, 26 females; mean age 35.6±12.7 years; range 15 to 72 years) who underwent surgery for septal deviation, concha bullosa, antrochoanal polyp between September 2006 and February 2008 were retrospectively evaluated and the anterior ethmoid foramen localization was measured according to the anterior nasal spine. The correlations of these measurements with the presence and absence of a frontal cell and an Agger nasi cell were investigated.

**Results:** The measurement of the anterior ethmoidal foramen according to anterior nasal spine was 18.2±8.8 mm in the absence of an Agger nasi cell and was 20.3±6.6 mm in the presence of an Agger nasi cell. This distance was measured as 20.0±7.3 mm when the frontal cell was not determined. This measurement was 20.2±6.5 mm in the presence of a frontal cell. According to the frontal cell types the results of the measurements were 20.5±5.9 mm, 18.9±8 mm, 20.6±7.3 mm, for type 1, type 2 and type 3, respectively. Our results revealed that there were no significant relationship between the presence or absence of a frontal cell and an Agger nasi cell and the localization of the anterior ethmoidal foramen.

**Conclusion:** The results of this study showed that the presence or absence of these cells does not affect localization of the anterior ethmoid artery.

**Key Words:** Anatomy; arteries; ethmoid sinus; paranasal sinuses; tomography.

**Amaç:** Bu çalışmada frontal hücre ya da Agger nasi hücresi varlığı veya yokluğunun anterior etmoid arterin lokalizasyonu üzerine etkisi incelendi.

**Hastalar ve Yöntemler:** Eylül 2006 - Şubat 2008 tarihleri arasında kliniğimizde septal deviyasyon, konka bulloza ya da antrokoanal polip nedeni ile ameliyat edilen 61 hastanın (35 erkek, 26 kadın; ort. yaş 35.6±12.7 yıl; dağılım 15-72 yıl), 110 tarafında koronal planda çekilen paranasal sinüs tomografileri geriye dönük olarak değerlendirildi ve anterior etmoid foramen lokalizasyonu anterior nazal spine'a göre ölçüldü. Frontal hücre ve Agger nasi hücresinin varlığı veya yokluğu ile bu ölçümler arasındaki ilişkiler araştırıldı.

**Bulgular:** Anterior nazal spine'a göre anterior etmoid foramenin ölçümü Agger nasi hücresi yokluğunda 18.2±8.8 mm ve Agger nasi hücresi varlığında 20.3±6.6 mm idi. Bu uzaklık frontal hücre belirlenmediğinde 20.0±7.3 mm olarak ölçüldü. Frontal hücrenin varlığında bu ölçüm 20.2±6.5 mm idi. Frontal hücre tiplerine göre ölçüm sonuçları tip 1, tip 2 ve tip 3 için sırasıyla 20.5±5.9 mm, 18.9±8.0 mm, 20.6±7.3 mm idi. Sonuçlarımız frontal hücre ve Agger nasi hücresi varlığı veya yokluğu ile anterior etmoid foramen lokalizasyonu arasında anlamlı bir ilişki olmadığını ortaya çıkardı.

**Sonuç:** Bu çalışmanın sonuçları bu hücrelerin varlığı ya da yokluğunun anterior etmoid arter lokalizasyonunu etkilemediğini göstermiştir.

**Anahtar Sözcükler:** Anatomi; arterler; etmoid sinus; paranasal sinüsler; tomografi.

The anterior ethmoidal artery (AEA) is regarded as an important structure in endoscopic sinus surgery. Preoperative knowledge of the course of the artery is essential for recognizing structures of difficult access (frontal sinus) and to define the skull base and avoid complications in surgery.<sup>[1]</sup>

Computed tomography (CT) is the preferred technique for evaluating the anatomy and possible lesions before endoscopic and surgical intervention.<sup>[2]</sup> The coronal plane correlates with the surgical approach used during endoscopic surgery,<sup>[3]</sup> and is therefore considered in mapping the anatomy.<sup>[1]</sup>

The degree of pneumatization in frontal and ethmoidal areas may affect other structures. The limit, shape and width of the frontal recess are largely determined by neighboring structures.<sup>[4]</sup> Pneumatization of agger nasi cells and frontal ethmoidal cells vary with the size of the frontal beak, and the pneumatization of the agger nasi cells with or without frontal ethmoidal cells affect the superior attachment of the uncinata process.<sup>[5]</sup> The presence of supraorbital pneumatization influences artery position vis a vis the ethmoidal roof.<sup>[1,6]</sup> It has been reported that when the ethmoidal cells are well pneumatized, the anterior ethmoid canal (AEC) is identified as a separate canal; when the ethmoidal cells are poorly pneumatized, the canal is usually embedded in the ethmoid roof.<sup>[7]</sup>

A method which could alert the endoscopic sinus surgeon about the position of the artery prior to surgery would be useful. Thus, we thought that evaluation of frontal cell and agger nasi cell in routine preoperative coronal paranasal CT could give us valuable information in localizing the AEA.

Could pneumatization in the anterior area of the anterior ethmoidal artery change the localization of the anterior ethmoidal artery from an anterior to a posterior direction? Could the presence or absence of frontal or agger nasi cells affect anterior ethmoidal artery localization? The aim of this study was to determine if the presence or absence of frontal cells or agger nasi cells change the localization of the anterior ethmoidal artery. To our knowledge, there is no study investigating whether the presence or absence of the frontal cells or agger nasi cells affect localization of the anterior ethmoid artery or not.

## PATIENTS AND METHODS

This retrospective study was carried out between September 2006 and February 2008 in a tertiary center in Ankara, Turkey. The coronal paranasal CT scans (3 mm coronal sections) of 127 patients who were candidates for septoplasty, concha surgery or antrochoanal polyp were evaluated. Two ear nose throat surgeons and one radiologist studied each CT scan jointly. Exclusion criteria were as follows; patients aged below 14 years, a history of surgery or trauma in the paranasal sinuses or the skull base, paranasal sinus malignancies and sinus diseases that opacified the frontal cell and/or the anterior ethmoidal cells. The CT scans in which the most anterior part of the nasal spine did not appear were excluded. Each side of the patients was evaluated separately. In the study, 110 sides of 61 patients (35 males, 26 females; mean age 35.6±12.7 years; range 15 to 72 years) met the inclusion criteria.

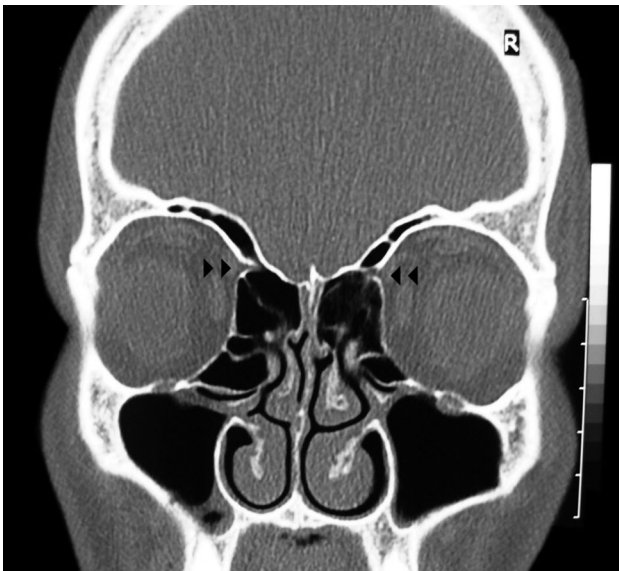
Frontal cells, agger nasi cells and anterior ethmoidal foramen (AEF) were evaluated. In this study, frontal cells were categorized according to the classification of Bent et al.<sup>[8]</sup> (Table 1). We differentiated type 1 frontal sinus cells from type 3 cells by determining whether the cell crossed the plane of the frontal isthmus. If the cell was entirely below this plane it was determined as a type 1 cell, whereas if it extended superior to this plane it was defined as a type 3 cell.<sup>[9]</sup>

The bony notch in the medial wall of the orbit, which corresponds to the anterior ethmoidal foramen (AEF) was used as landmark for the AEA (Figure 1).<sup>[1,10]</sup> The nasal spine was determined to be a reference point for the AEF measurements. The distance from the nasal spine to the AEF was measured and the presence or absence of frontal cells and frontal cell types and agger nasi cells were noted for each side. In 3 mm thick sections, the distance between the structures seen in consecutive images were calculated as 3 mm on the coronal CT.

In this retrospective study, the distance of the AEF from the nasal spine and the correlation

**Table 1.** Bent classification<sup>[8]</sup> of frontal cell types

Type 1	Single frontal recess cell above agger nasi cell
Type 2	Tier of cells in frontal recess above agger nasi cell.
Type 3	Single massive cell pneumatizing cephalad into frontal sinus
Type 4	Single isolated cell within the frontal sinus



**Figure 1.** Bony notch on the medial wall of the orbits, corresponding to the anterior ethmoidal foramina (between superior oblique and medial rectus orbital muscles) (double arrow head).

between the presence or absence of frontal cells and agger nasi cells were assessed.

Statistical analysis was performed using Statistical Package for Social Sciences (SPSS) 11.5 software (SPSS Inc., Chicago, IL, USA). Whether the continuous variables were normally distributed or not was determined by using Shapiro Wilks test. Data was shown as mean  $\pm$  standard deviation (minimum - maximum) for continuous variables. Categorical variables were presented as number of cases and (%). The Mann-Whitney U-test was used to compare AEF measures when the number of

independent groups was two. Differences between more than two groups were evaluated by using the Kruskal Wallis test. A  $p$  value less than 0.05 was considered statistically significant.

## RESULTS

### Agger nasi cell

The agger nasi cell was present in 97 (88.2%) of the 110 sides and absent in 13 (11.8%). The distance of the AEF from the anterior nasal spine with the agger nasi cell absent was  $18.2\pm 8.8$  mm (range 0-30 mm) and with the agger nasi cell present was  $20.3\pm 6.6$  mm (range 0-33 mm). There were no statistically significant differences between the presence or absence of the agger nasi cell and the distance of the AEF ( $p=0.509$ ). Statistical findings are showed in table 2.

### Frontal cell

The frontal cell was present in 58 (52.7%) of the 110 sides and absent in 52 (47.3%) of the 110 sides. The distance of the AEF from the nasal spine was  $20.0\pm 7.3$  mm (range 0-33 mm) in the absence of frontal cells. This measure was  $20.2\pm 6.5$  mm (range 0-33 mm) in the presence of frontal cells. There were no statistical significance between the presence or absence of frontal cells and the distance of the AEF ( $p=0.799$ ).

The prevalences of frontal cell type 1 (Figure 2) and frontal cell type 2 (Figure 3), and frontal cell type 3 (Figure 4) were 37 (33.6%), 13 (11.8%), eight (7.3%), respectively. No frontal cell type 4 was identified. According to frontal cell type, measures were  $20.5\pm 5.9$  mm (range 0-33 mm),  $18.9\pm 8.0$  mm

**Table 2.** The measurement of the anterior ethmoidal foramen according to agger nasi cell and frontal cell

Variables	n	%	Mean $\pm$ SD	Range mm	$p$
Agger nasi					
Absent	13	11.8	$18.2\pm 8.8$	0-30	0.509
Present	97	88.2	$20.3\pm 6.6$	0-33	
Frontal cell					
Absent	52	47.3	$20.0\pm 7.3$	0-33	0.799
Present	58	52.7	$20.2\pm 6.5$	0-33	
Type of frontal cell					
Absent	52		$20.0\pm 7.3$	0-33	0.928
Type 1	37	33.6	$20.5\pm 5.9$	0-33	
Type 2	13	11.8	$18.9\pm 8.0$	0-30	
Type 3	8	7.3	$20.6\pm 7.3$	6-30	

SD: Standard deviation.

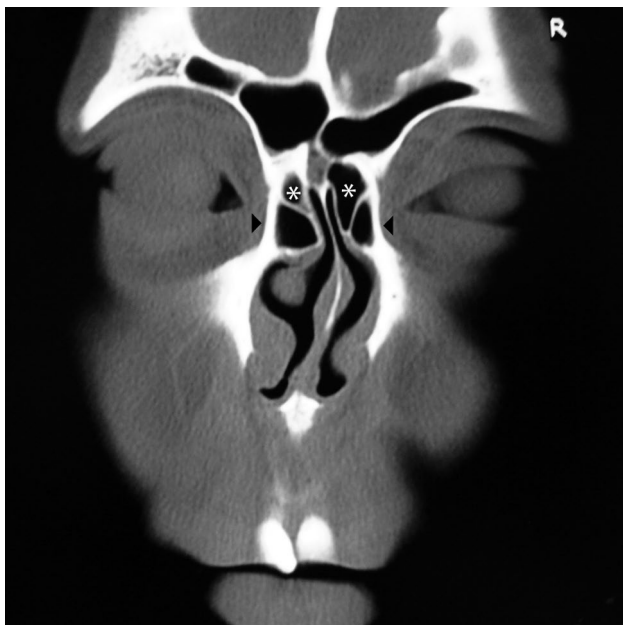


Figure 2. Bilateral frontal type 1 cells (stars) and bilateral agger nasi cells (arrow heads).

(range 0-30 mm) and  $20.6 \pm 7.3$  mm (range 6-30 mm), respectively.

There were no associations between localization of the AEF and frontal cell types ( $p=0.928$ ). Table 2 shows the statistical results.

There was no association between joint effects of agger nasi cells and frontal cells to distance of the AEF. Statistical findings are shown in table 3.

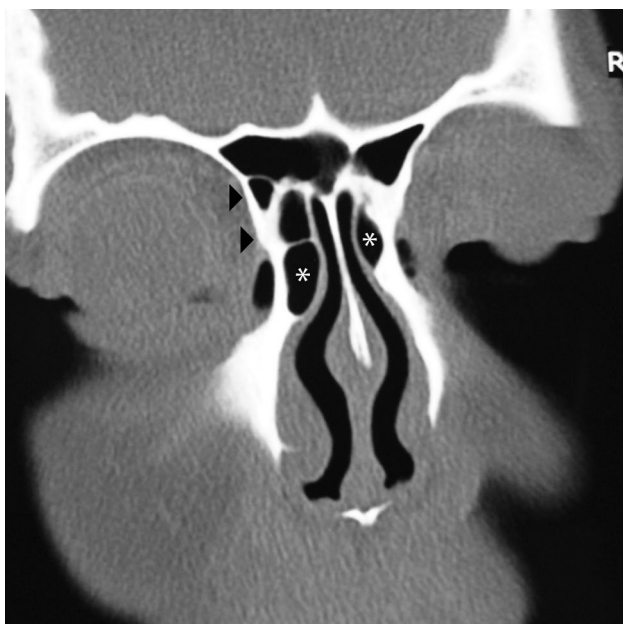


Figure 3. Frontal cell type 2 on the left side (arrow heads), bilateral agger nasi cells (stars).

Statistical findings according to gender are presented in tables 4 and 5.

### DISCUSSION

The AEA traverses three cavities: the orbit, ethmoid labyrinth and anterior cranial fossa.<sup>[3]</sup> Originating from the ophthalmic artery, the AEA continues between superior oblique and medial rectus orbital muscles.<sup>[10]</sup> It passes through the AEF into the anterior ethmoids and crosses this structure surrounded by a thin-walled bony canal.<sup>[11]</sup> The anterior ethmoid canal (AEC) courses anteriorly and medially in a horizontal plane and the artery passes through the cribroethmoid foramen toward the anterior wall of the nasal cavity.<sup>[10]</sup>

The AEA is a crucial structure for endoscopic sinus surgery. It is used as a guide to identify the frontal recess and skull base in the ethmoidal roof.<sup>[2,12]</sup> The AEA is one of the most easily injured vascular structures during paranasal sinus surgery.<sup>[2]</sup> Damage to the artery during surgery can cause devastating bleeding and could cause a hematoma due to artery retraction toward the infraorbital region, and even cerebral infections.<sup>[7,12,13]</sup>

In the literature, research concerning anatomical features of the AEA has been reported using cadavers or radiology.<sup>[12-15]</sup> Its course in the ethmoid labyrinth and its location relative to the ethmoidal roof are very variable.<sup>[1,2,6,7]</sup>

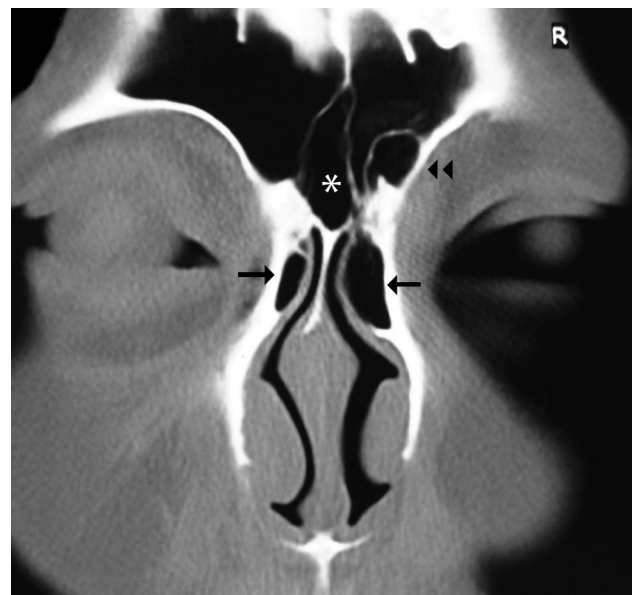


Figure 4. Frontal cell type 3 on the right side (double arrow head), intersinus septal cell (star), agger nasi cells (arrows).

**Table 3.** Joint effects of agger nasi cell and frontal cell to distance of the anterior ethmoidal foramen

Variables	Frontal (-)		Frontal (+)		p
	Mean±SD	mm	Mean±SD	mm	
Agger nasi (-)	18.6±9.0	0-30	17.0±9.6	6-24	0.937
Agger nasi (+)	20.3±6.9	0-33	20.3±6.3	0-33	0.842
p	0.734		0.594		

The AEA can often be visualized in the posterior region of the frontal recess where the bulla lamella joins the skull base.<sup>[5]</sup> Stammberger suggested that the AEA would be located at 1 to 2 mm posterior to the highest point of the ethmoidal bulla anterior face.<sup>[11]</sup> Simmen et al.<sup>[6]</sup> reported that the commonest location of the artery was in the suprabullar recess (85.3%). Cankal et al.<sup>[2]</sup> identified the AEC in 68% of coronal images using 3 mm thick sections and reported that it can be seen from the beginning of the anterior ethmoidal cells at the 4<sup>th</sup> to 10<sup>th</sup> section on coronal images.

In a cadaveric study, Erdoğan et al.<sup>[14]</sup> reported that the AEC was positioned between the second and third lamella in 29 cases (76.32%), in the third lamella in five cases (18.32%), and in the second lamella in two cases (5.26%). They found that the AEA varies between forward (n=15) or backward (n=23) positions according to the anterior septum

insertion of the bulla. However, Yang et al.<sup>[7]</sup> reported higher rates in their cadaveric study<sup>[7]</sup> It was seen between the second and third lamella in 85.7% of the cases. They found that other locations were over the roof of the frontal recess cells (10.7%) and the roof of the posterior ethmoid sinus (3.6%).

The literature provides data on the artery's identification from radiological studies. Takahashi et al.<sup>[12]</sup> reported that the AEA presented in 75.4% at section widths of 3 mm by using multidetector row CT. In some studies, it was proposed that anterior indentation in the medial orbital wall allows identification of the localization of the artery on coronal scans and this anatomical finding was a good reference for identifying the position and orientation of the AEA within the ethmoid sinus.<sup>[1,10,15]</sup> While Gotwald et al.<sup>[10]</sup> found that the anterior indentation in the medial orbital wall was identified on 95% of all CT images obtained using

**Table 4.** The measure of the anterior ethmoidal foramen according to agger nasi cell and frontal cell within gender groups

Variables	Male		Female	
	Mean±SD	mm	Mean±SD	mm
Agger nasi				
Absent	18.7±10.9	0-30	17.4±4.9	9-21
Present	20.3±7.5	0-33	20.3±5.2	12-30
p	0.967		0.283	
Frontal cell				
Absent	20.1±8.4	0-33	19.8±5.9	9-30
Present	20.1±7.6	0-33	20.2±3.5	12-27
p	0.935		0.858	
Type of frontal cell				
Absent	20.1±8.4	0-33	19.8±5.9	9-30
Type 1	20.4±6.8	0-33	20.6±4.4	12-27
Type 2	18.4±10.3	0-30	19.5±4.9	12-27
Type 3	21.0±8.1	6-30	19.5±6.4	15-24
p	0.978		0.965	

SD: Standard deviation.

**Table 5.** Joint effects of agger nasi cell and frontal cell to distance of the anterior ethmoidal foramen within gender groups

Variables	Frontal (-)		Frontal (+)		p
	Mean±SD	mm	Mean±SD	mm	
Male					
Agger nasi (-)	19.8±12.5	0-30	17.0±9.6	6-24	0.571
Agger nasi (+)	20.1±7.4	0-33	20.4±7.5	0-33	0.769
p	0.758		0.518		
Female					
Agger nasi (-)	17.4±4.9	9-21	-	-	-
Agger nasi (+)	20.5±6.1	12-30	20.2±4.5	12-27	0.821
p	0.290		-		

SD: Standard deviation.

3 mm slice thickness, Souza et al.<sup>[1]</sup> reported that it was seen in 100% of CT exams with same section thickness. We also used this parameter for the AEA location.

Some cadaveric studies reported significant information on the measurement of the distance from the AEA to some reference points.<sup>[13,14,16]</sup> Araujo Filho et al.<sup>[13]</sup> observed that the average distance of the artery middle point to the anterior nasal spine was 61.72 mm. In our study this measure varied between 0-33 mm. This significant difference may be related to differences between angular measures in cadaver study and measures of linear plane in CT scans.

However, contrary to these studies, few studies have investigated the association between ethmoidal cell pneumatization and localization of the AEA.<sup>[1,6]</sup>

Simmen et al.<sup>[6]</sup> reported that the degree of pneumatization of the suprabullar recess/supraorbital cells correlates with the distance between the AEA and the skull base in their study using cadavers and tomography. Souza et al.<sup>[1]</sup> found similar results in their CT study with 3 mm section thickness. Yang et al.<sup>[7]</sup> emphasized that the AEA extended via the posterior ethmoid sinus in one case in a cadaver study. In this case, the posterior ethmoid sinus was highly pneumatized and the middle turbinate lamella was located anteriorly.

Frontal cells have been reported in 20 to 41% of sinus specimens. A study using multiplanar CT identified frontal cells in 33% of cases.<sup>[9]</sup> We found frontal cells in 52.7%. This high rate may be related to racial differences and/or inclusion criteria. In the

Korean group, it was observed that the prevalence of frontal cell types was 22.8%, 14.0%, 7.9% and 0%, respectively.<sup>[17]</sup> On the other hand, Lee et al.<sup>[18]</sup> reported that frontal cell prevalence was frontal cell type 1 (37%), frontal cell type 2 (19%), frontal cell type 3 (8%) and frontal cell type 4 (0%). These were evaluated on both coronal and sagittal image CT at 1 mm section thickness. We found that the prevalence of frontal cell type 1, frontal cell type 2 and frontal cell type 3 were 37 (33.6%), 13 (11.8%) and eight (7.3%), respectively. Our rates are somewhat lower than the aforementioned study.

Some investigators also used the nasal spine as a reference point on coronal CT<sup>[19]</sup> and lateral radiography of the paranasal sinuses.<sup>[20]</sup> They measured the distance from the nasal spine to the mid-fovea ethmoidalis, maxillary sinus ostium, ethmoidal roof and sphenoid sinus.<sup>[19,20]</sup>

The weakness of this study is the negligible error range that is less than 3 mm in measuring the most anterior portion of the nasal spine. In order to minimize this error range, we only evaluated CT scans where the most anterior portion of the nasal spine could be seen.

None of previous studies investigated the association of presence or absence of frontal cells or agger nasi cells with localization of the AEA.

In conclusion, our results revealed that there is no significant relationship between the presence or absence of frontal and agger nasi cells and localization of the AEF. This data has provided the surgeon with valuable information regarding the anterior ethmoid artery. We believe that concerning this topic, further cadaveric studies may be beneficial.

## REFERENCES

1. Souza SA, Souza MM, Gregório LC, Ajzen S. Anterior ethmoidal artery evaluation on coronal CT scans. *Braz J Otorhinolaryngol* 2009;75:101-6.
2. Cankal F, Apaydin N, Acar HI, Elhan A, Tekdemir I, Yurdakul M, et al. Evaluation of the anterior and posterior ethmoidal canal by computed tomography. *Clin Radiol* 2004;59:1034-40.
3. Bayram M, Sirikci A, Bayazit YA. Important anatomic variations of the sinonasal anatomy in light of endoscopic surgery: a pictorial review. *Eur Radiol* 2001;11:1991-7.
4. Landsberg R, Friedman M. A computer-assisted anatomical study of the nasofrontal region. *Laryngoscope* 2001;111:2125-30.
5. Wormald PJ. The agger nasi cell: the key to understanding the anatomy of the frontal recess. *Otolaryngol Head Neck Surg* 2003;129:497-507.
6. Simmen D, Raghavan U, Briner HR, Manestar M, Schuknecht B, Groscurth P, et al. The surgeon's view of the anterior ethmoid artery. *Clin Otolaryngol* 2006;31:187-91.
7. Yang YX, Lu QK, Liao JC, Dang RS. Morphological characteristics of the anterior ethmoidal artery in ethmoid roof and endoscopic localization. *Skull Base* 2009;19:311-7.
8. Bent JP, Cuijly-Siller C, Kuhn FA. The frontal cell as a cause of frontal sinus obstruction. *Am J Rhinol* 1994;8:185-91.
9. DelGaudio JM, Hudgins PA, Venkatraman G, Beningfield A. Multiplanar computed tomographic analysis of frontal recess cells: effect on frontal isthmus size and frontal sinusitis. *Arch Otolaryngol Head Neck Surg* 2005;131:230-5.
10. Gotwald TF, Menzler A, Beauchamp NJ, zur Nedden D, Zinreich SJ. Paranasal and orbital anatomy revisited: identification of the ethmoid arteries on coronal CT scans. *Crit Rev Comput Tomogr* 2003;44:263-78.
11. Stammberger H. *Functional endoscopic sinus surgery: the Messerklinger technique*. Philadelphia: BC Decker Publishers; 1991. p. 49-89.
12. Takahashi N, Ohkubo M, Higuchi T, Maeda H. Identification of the anterior ethmoid arteries on thin-section axial images and coronal reformatted orbit images by means of multidetector row CT. *Clin Radiol* 2007;62:376-81.
13. Araujo Filho BC, Weber R, Pinheiro Neto CD, Lessa MM, Voegels RL, Butugan O. Endoscopic anatomy of the anterior ethmoidal artery: a cadaveric dissection study. *Braz J Otorhinolaryngol* 2006;72:303-8.
14. Erdogmus S, Govsa F. The anatomic landmarks of ethmoidal arteries for the surgical approaches. *J Craniofac Surg* 2006;17:280-5.
15. Pandolfo I, Vinci S, Salamone I, Granata F, Mazziotti S. Evaluation of the anterior ethmoidal artery by 3D dual volume rotational digital subtraction angiography and native multidetector CT with multiplanar reformations. Initial findings. *Eur Radiol* 2007;17:1584-90.
16. Lee WC, Ming Ku PK, van Hasselt CA. New guidelines for endoscopic localization of the anterior ethmoidal artery: a cadaveric study. *Laryngoscope* 2000;110:1173-8.
17. Cho JH, Citardi MJ, Lee WT, Sautter NB, Lee HM, Yoon JH, et al. Comparison of frontal pneumatization patterns between Koreans and Caucasians. *Otolaryngol Head Neck Surg* 2006;135:780-6.
18. Lee WT, Kuhn FA, Citardi MJ. 3D computed tomographic analysis of frontal recess anatomy in patients without frontal sinusitis. *Otolaryngol Head Neck Surg* 2004;131:164-73.
19. Medina J, Hernandez H, Tom LW, Bilaniuk L. Development of the paranasal sinuses in children. *Am J Rhinol* 1997;11:203-9.
20. May M, Mester SJ, O'Daniel TG, Curtin HD. Decreasing the risks of endonasal endoscopic sinus surgery by imaging techniques. *Operative Techniques Otolaryngol Head Neck Surg* 1990;1:89-91.