



# Complications of chronic suppurative otitis media: challenge for a developing country

## Süpüratif otitis media komplikasyonları: Gelişen bir ülke için zorluk

Fazal I Wahid, M.D., (FCPS), Adil Khan, M.D., (FCPS), Iftikhar Ahmad Khan, M.D., (FCPS)

Department of ENT, Head & Neck Surgery, Postgraduate Medical Institute (PGMI), Lady Reading Hospital (LRH) Peshawar, Khyber Pakhtunkhwa, Pakistan

**Objectives:** This study aims to investigate the frequency and management of complications of chronic suppurative otitis media (CSOM).

**Patients and Methods:** Out of 376 patients with CSOM, 44 patients (25 males, 19 females; mean age 48.5±3.5 years; range 21 to 76 years) meeting study criteria were enrolled in this descriptive cross sectional study which was conducted at the Department of Ear Nose and Throat, Head and Neck Surgery, Postgraduate Medical Institute, Lady Reading Hospital Peshawar. All newly diagnosed patients having CSOM with complications were enrolled. The complications were treated first. Intracranial abscesses were evacuated by neurosurgeons. Radical and modified radical mastoidectomy were performed.

**Results:** Majority of the patients presented in the second and third decade of life (21-30 years: 27.27%, 31-40 years: 18.18%). Most of the patients (59.1%) had lower socioeconomic status. Canal wall down mastoidectomy was the most common (79.5%) procedure performed. Cholesteatoma was the most common operative finding (100%). Among extracranial complications, subperiosteal abscess was the most common finding (38.63%), while extradural abscess outnumbered (22.72%) in intracranial complications.

**Conclusion:** Complications of CSOM commonly affect younger people with low socioeconomic status. Collaborating with neurosurgeons may assist in the successful management of this infection.

**Keywords:** Extracranial complications; intracranial complications; suppurative otitis media.

**Amaç:** Bu çalışmada kronik süpüratif otitis media (KSOM) komplikasyonlarının sıklığı ve yönetimi araştırıldı.

**Hastalar ve Yöntemler:** Lady Reading Hastanesi Peşaver, Lisansüstü Tıp Enstitüsü, Kulak Burun ve Boğaz, Baş ve Boyun Cerrahisi Bölümünde yapılan bu tanımlayıcı kesitsel çalışmaya KSOM'lu 376 hastadan çalışma kriterlerini karşılayan 44 hasta (25 erkek, 19 kadın; ort. yaş 48.5±3.5 yıl; dağılım 21-76 yıl) dahil edildi. Tanısı yeni konulmuş KSOM'u ve komplikasyonları olan tüm hastalar dahil edildi. Önce komplikasyonlar tedavi edildi. İntrakraniyal apseler beyin cerrahları tarafından boşaltıldı. Radikal ve modifiye radikal mastoidektomi uygulandı.

**Bulgular:** Hastaların çoğu yaşamlarının ikinci ve üçüncü on yılında başvurdu (21-30 yaş: %27.27, 31-40 yaş: %18.18). Hastaların çoğunun sosyoekonomik durumu düşüktü (%59.1). Açık mastoidektomi en yaygın uygulanan işlemi (%79.5). Kolesteatom en yaygın ameliyat bulgusu oldu (%100). Ekstrakraniyal komplikasyonlar içinde subperiosteal apse en yaygın bulgu iken (%38.63) intrakraniyal komplikasyonlarda ekstradural apse daha çoktu (%22.72).

**Sonuç:** Kronik süpüratif otitis media komplikasyonları yaygın olarak düşük sosyoekonomik durumu olan daha genç insanları etkiler. Beyin cerrahlarıyla işbirliği yapılması bu enfeksiyonun başarıyla yönetilmesinde yardımcı olabilir.

**Anahtar Sözcükler:** Ekstrakraniyal komplikasyonlar; intrakraniyal komplikasyonlar; süpüratif otitis media.



Chronic suppurative otitis media (CSOM) is a chronic inflammation (>3 month duration) of the mucoperiosteal lining of the middle ear cleft. The prevalence of CSOM depends on age, poor socioeconomic condition, poor housing, overcrowding and lack of access to medical care.<sup>[1]</sup> Chronic suppurative otitis media is classified into two main categories, tubotympanic and atticointral disease. The former is considered 'safe' from the point of view of complications while the latter has been considered a 'dangerous' form of disease in view of the risks of otogenic complications.<sup>[2]</sup> Central perforations in the pars tensa of varying size and position are seen in this disease. In this condition the risk of developing complications such as brain abscess are very rare but some minor complications may develop like otitis externa, granulation tissue and mucosal polyp.<sup>[3]</sup> Atticoantral disease most commonly involves the epitympanum. The typical feature of atticointral disease is the presence of cholesteatoma. The relevant pathophysiology of cholesteatoma is negative middle ear pressure, invasion of squamous epithelium and squamous metaplasia of middle ear mucosa. Marginal and attic perforations are commonly found in this disease which expose the anatomical structures of the attic, antrum and mastoid air cells system.<sup>[2,4]</sup> In atticointral disease various extracranial complications like mastoiditis, subperiosteal abscess, facial nerve paralysis, labyrinthitis and petrositis with bone destruction may occur. The various intracranial complications are extradural abscess, subdural abscess, meningitis, encephalitis, brain abscess, lateral sinus thrombosis and otitic hydrocephalus.<sup>[3,5]</sup> The most common bacterial pathogens of otitis media are *Streptococcus pneumoniae*, *Hemophilus influenza* and *Moraxella catarrhalis*. Other pathogens responsible for otitis media are *Staphylococcus aureus*, *Escherichia coli*, *Klebsiella species*, *Pseudomonas aeruginosa* and *Proteus species*. However mixed type (aerobic and anaerobic) pathogens are commonly isolated from chronic suppurative otitis media.<sup>[5]</sup> Different routes of spread of infection to the cranial cavity are direct erosion of bone, hematological, through anatomical pathways and previous surgical or non surgical trauma.<sup>[3,6]</sup> After the introduction of antimicrobial agents in 1930, there has been a reduction in the incidence of otogenic complications from 2.3% to 0.04%.<sup>[4,7]</sup> Complications of chronic suppurative

otitis media can be medically treated first followed by surgical treatment of the CSOM.<sup>[8]</sup> In developing countries like Pakistan the complications are comparatively higher leading to disability or even death. The reasons may include illiteracy, poverty, overcrowding, and lack of health facilities. As a reasonable number of patients with complications of CSOM are presenting to our department, this study was designed to determine the frequency and management of complications of CSOM in a developing country like Pakistan.

### PATIENTS AND METHODS

This descriptive cross sectional study was conducted at the department of Ear, Nose, Throat, Head (ENT) and Neck Surgery, Postgraduate Medical Institute, Lady Reading Hospital Peshawar between January 2009 and December 2011 (3 years). Out of 376 patients with CSOM who visited our department during the study, only 44 patients (25 males and 19 females; mean age 48.5±3.5 years; range 21 to 76 years) were enrolled in the study after fulfilling inclusion criteria. All newly-diagnosed patients with chronic suppurative otitis media and complications of any age, race and gender were included in this study. Patients having complications due to acute otitis media and those where no surgical intervention was carried out were excluded from the study. Patients diagnosed with CSOM with complications were admitted into the ENT department. An intravenous (i.v.) line was maintained and all the patients were given intravenous antibiotics while critically ill patients were subjected to a quadruple antibiotic regimen consisting of benzyl penicillin (200,000 to 500,000 units i.v. 6-hourly), chloramphenicol (50 mg/kg body weight 8-hourly), metronidazole (7.5 mg/kg body weight i.v. 8-hourly), and gentamycin (1.5 mg/kg body weight i.v. 12-hourly). This medical treatment was given to patients for at least 2-3 weeks depending upon the severity of the disease. After the complications of CSOM were properly treated, the disease of the ear was then dealt with surgically. Radical and modified radical mastoidectomy was carried out depending upon the extent and severity of the disease. A detailed history regarding ear discharge, onset, duration, frequency and associated illness was taken from patients or parents. Thorough examination of ears, nose and throat specifically focusing on ears and otogenic complications was performed. Besides

routine investigations, pure tone audiometry (if possible), computed tomography scan, and magnetic resonance imaging (in cases where CT scan was not informative) were obtained to determine the site and extent of the complication and its management. In cases of otogenic abscess urgent evacuation was arranged. Intracranial abscesses were drained by neurosurgical colleagues while extracranial abscess was treated by ENT surgeons. Intracranial abscess were urgently treated by neurosurgeon with procedures like bur-hole aspiration, craniotomy and transmastoid excision depending upon the location of the abscess. In case of intracranial complications, primary disease in the ear was treated 3-4 weeks after overcoming the complications. The complications were treated conservatively/surgically before embarking on the treatment of the primary focus in the ears. Informed consent was obtained from patients/parents after explaining the procedure, its risks, benefits and associated complications. The study was approved by the hospital ethical committee. All patients were followed up to one year to look for any recurrence of complications. The data was collected on a preformed pro forma and statistical analysis was performed using SPSS version 17.0 (SPSS Inc., Chicago, IL, USA) software program. Frequency and percentage were calculated for qualitative data and mean and standard deviation were calculated for quantitative data.

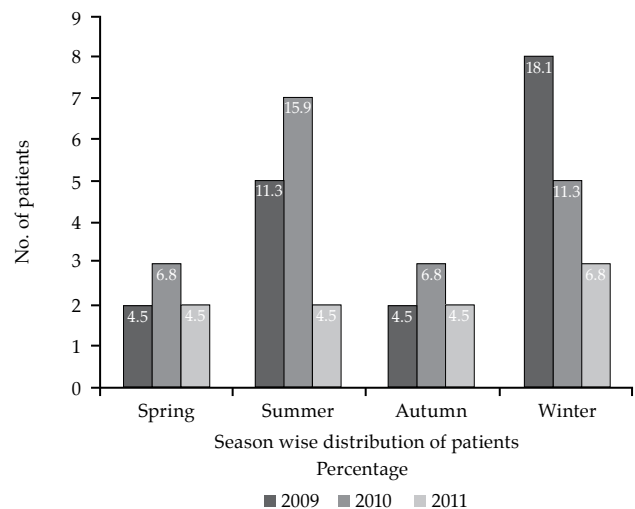
## RESULTS

Majority of the patients presented in the second and third decade of life (21-30 years, 27.27%, 31-40 years, 18.18%) (Table 1). Among these patients 26 (59.1%) had lower socioeconomic status while 11 (25%) and seven (15.9%) were from middle and high socioeconomic classes respectively. Most of these patients were received in summer and autumn seasons of the year (Figure 1). Mild

**Table 1.** Age distribution of patients with mean ( $\pm$ SD)

Age in years	Patients (n)	Percentage	Mean $\pm$ SD
21-30	12	27.27	25.33 $\pm$ 2.57
31-40	8	18.18	35.12 $\pm$ 2.79
41-50	7	15.90	45.71 $\pm$ 3.25
51-60	7	15.90	49.85 $\pm$ 9.02
61-70	6	13.63	63.33 $\pm$ 1.86
>70	4	9.09	71.75 $\pm$ 1.25

SD: Standard deviation.



**Figure 1.** Seasonal frequency of patients in study period (2009-2011) (n=44).

to moderate hearing loss was observed in 36 patients (77.27%), while severe to profound hearing loss was recorded in eight patients (18.18%). The main presentation of these patients was discharging ears in all cases (100%) and the most common otoscopic finding was atticotral perforation in the drum (93.18%) (Table 2). Canal wall down mastoidectomy was carried out in

**Table 2.** Clinical symptoms and signs of chronic suppurative otitis media with complications (n=44)

	No. of cases	Percentage
<b>Symptoms</b>		
Discharging ear	44	100
Headache	32	72.72
Impaired hearing	26	59.0
Vomiting	23	52.27
Vertigo	18	40.90
Ataxia	9	20.45
<b>Signs</b>		
Atticotral perforation in drum	41	93.18
Tubotympanic perforation in drum	3	6.81
Granulation tissue/cholesteatoma	38	86.36
Papilloedema	15	34.09
Nystagmus	9	20.45
Facial nerve palsy	6	13.63
Swelling in neck	4	9.09
Tenderness in neck	2	4.54
Neck stiffness	2	4.54

35 patients (79.5%), modified radical mastoidectomy in seven (15.9%) and tympanoplasty in two (4.5%). Intracranial abscesses were primarily evacuated by neurosurgeons via bur-hole aspiration (45.4%) and craniotomy (25%). Operative findings in this study were cholesteatoma (100%), granulation tissues in 37 (84.1%), and ossicular erosion in 21 (47.7%) (Table 3).

Extracranial complications were observed in 31 patients (70.45%). Among these subperiosteal abscess was the most common finding (38.63%), followed by facial nerve palsy (13.63%). Intracranial complications were present in 34 patients (77.27%). Among these, extradural abscess was prominent (22.72%). Meningitis and subdural abscess were recorded in 18.18% and 11.36% respectively (Table 4). Two patients died due to complications, hence the mortality was 4.5%.

### DISCUSSION

Complication rates related to CSOM have been dramatically reduced since the emergence of the antibiotic era. The rapid increase in welfare and the development of health care systems in industrialized countries have made it possible to offer proper medical treatment to patients.<sup>[8,9]</sup> However, these infections remain major challenges with respect to the diagnosis and management of CSOM in developing

countries. Chronic suppurative otitis media may result in complications among individuals irrespective of gender.<sup>[10]</sup> In this study males were affected more than females with male:female ratio of 1.3:1 in accordance with the study of Baig with male predominance (56.72%), but differs from the results of Memon where females were dominant with a female-male ratio of 1.2:1.<sup>[11,12]</sup> The explanation for male predominance in our set up could be that females have less access to health care facilities due to social taboo. We studied patients with otogenic complications having age ranges from 21-76 years with mean age of  $48.5 \pm 3.5$  years, which is not in agreement with the report of Yagizy where patients ages ranged from 9-74 years with mean age of 31.3 years.<sup>[13]</sup> In this study the majority of patients (45.45%) presented in the second and third decade of life which is comparable to the study of Vikram who found the majority of patients were younger with male predominance.<sup>[14]</sup> The complications of CSOM have a predilection for younger-aged people probably due to their immature immune system and these people are more negligent about self care. In this study 26 patients (59.1%) had lower socio-economic status which simulates the finding of Islam where complications of CSOM were common in rural populations with low socio-economic status, poor nutrition and bathe in river or pond water.<sup>[15]</sup> Similarly Vikram

**Table 3.** Surgical procedures and operative findings in this study (n=44)

Surgical procedures	No. of cases	Percentage
Otological procedures		
Canal wall down mastoidectomy	35	79.5
Modified radical mastoidectomy	7	15.9
Tympanoplasty	2	4.5
Trans-mastoid excision of abscess	3	6.8
Neurosurgical procedures		
Bur-hole aspiration	20	45.4
Craniotomy	11	25
Operative findings		
Cholesteatoma	44	100
Granulation tissues	37	84.1
Ossicular erosion	21	47.7
Exposed dura	9	20.4
Dehiscence facial nerve	7	15.9
Post aural fistula	5	11.3

**Table 4.** Complications of chronic suppurative otitis media observed in this study (n=44)

Complications	Frequency	Percentage
Extracranial		
Subperiosteal abscess	17	38.63
Facial nerve palsy	6	13.63
Bezold's abscess	4	9.09
Labyrinthitis	3	6.81
Trapezius abscess	1	2.27
<i>Total</i>	31	70.45
Intracranial		
Extradural abscess	10	22.72
Meningitis	8	18.18
Subdural abscess	5	11.36
Brain abscess	4	9.09
Lateral sinus thrombophlebitis	2	4.54
Multiple complications	5	11.36
<i>Total</i>	34	77.27

also experienced that rural and illiterate patients had a higher risk of developing complications.<sup>[14]</sup> In the current study there was mild to moderate hearing loss in 36 patients (77.27%), while severe to profound hearing loss was recorded in eight patients (18.18%), in accordance with the study of Magsi who observed that six patients (10%) had a severe degree of hearing impairment, while 45 patients (75%) and nine patients (15%) had moderate and mild degrees of hearing impairment respectively.<sup>[16]</sup> The presentations of these patients were discharging ears in all cases (100%) and the commonest otoscopic finding was atticofacial perforation in the drum (93.18%). Similarly Matanda et al.<sup>[17]</sup> found that otorrhea and hearing loss were the major presenting symptoms. However clinical features of this study are at variance with Ceylan's study having otorrhea 44.3%, headache 20.6% and postauricular swelling 10.3%.<sup>[18]</sup> The complications of CSOM can be managed by treating the complication first followed by treating the primary source of infection surgically. In the current study a post-aural approach was adopted in all patients (100%) and mainly canal wall down mastoidectomy (79.5%) was carried out while in seven patients (15.9%) modified radical mastoidectomy and in two patients (4.5%) tympanoplasty was performed, simulating the results of Magsi who performed canal wall down mastoidectomy in 45 (75%) cases.<sup>[16]</sup> Likewise Khan carried out canal wall down mastoidectomy in 23 patients (65.71%), modified radical mastoidectomy in seven patients (20%) and atticotomy in three patients (8.57%).<sup>[19]</sup> Our results regarding surgical procedures for CSOM differ from those of Sangupta who performed canal wall down mastoidectomy in 25 patients (62.5%), atticotomy in five cases (12.5%) and tympanoplasty in seven cases (17.5%).<sup>[20]</sup> The explanation may be that Sangupta studied cases with limited disease. Otogenic intracranial abscess was primarily treated by neurosurgeons with procedures like bur-hole aspiration (45.4%) and craniotomy (25%). Similarly Sarmast conducted a study on 47 patients with intracranial abscess and 29 patients (61.7%) were treated with bur-hole aspiration, wherein seven patients needed second aspiration while 18 patients (38.3%) were treated with craniotomy. The treatment procedures for intracranial abscess in this study were also similar to those of Tan, who performed craniotomy in 28 patients (54.9%)

and bur-hole aspiration in 23 patients (45.1%) for intracranial abscess.<sup>[21]</sup> The neurosurgical techniques adopted in this study differ from Gadgil who treated a total of 33 patients with intracranial abscess-- 22 patients (67%) with craniotomy, nine patients (27%) with open aspiration and two (6%) with bur-hole aspiration, and six patients (18%) with repeat surgical procedures for abscess recurrence.<sup>[22]</sup> Operative findings in this study were cholesteatoma in 44 patients (100%), granulation tissue in 37 patients (84.1%), ossicular damage in 21 patients (47.7%) and dehiscent facial nerve in seven patients (15.9%). Similarly operative findings of this study are also consistent with results of Magsi.<sup>[16]</sup> The operative findings of this study are also consistent with results of Islam who found cholesteatoma in 76% and granulation tissue in 23% cases.<sup>[15]</sup> However our operative findings were not in accordance with Memon's where cholesteatoma was found in 45 patients (11.5%), ossicular damage in 45 patients (11.5%), and exposed facial nerve in six patients (1.53%).<sup>[12]</sup> Chronic suppurative otitis media can give rise to intracranial and extracranial complications depending upon the severity of infection. We observed that the most common extracranial complication was subperiosteal abscesses (38.63%) while the most common intracranial complication was extradural abscess (22.72%). Our findings are in agreement with Dubey's study that revealed commonly encountered intracranial complications were otitic meningitis, lateral sinus thrombosis, and cerebellar abscess, which were seen in 13 (19%), 10 (14%), and six (9%) cases, respectively.<sup>[23]</sup> The extracranial complications were mastoid abscess, postauricular fistula, and facial palsy 37%, 24% and 14% respectively. Likewise Yagizy reported that meningitis was the most common (n=15, 35.7%) intracranial complication of CSOM followed by brain abscess (n=14, 33.3%) and lateral sinus thrombosis (n=10, 23.8%).<sup>[13]</sup> Our results vary from findings of Ceylan who noted that labyrinthitis was the most common extracranial complication (44.3%) followed by facial palsy (35%), mastoid abscess (11.3%), postauricular fistula (7.3%), and Bezold's abscess (2.1%).<sup>[18]</sup> The complications of CSOM in this study also differ from those of Adoga where complications of CSOM were mastoid abscess (6.8%), subperiosteal abscess (1.4%), meningitis (1.4%) and facial nerve paralysis (1.4%).<sup>[24]</sup>

However we cannot establish the explanation for this difference. Our overall mortality of 4.5% is higher than Mostafa's and Yagizy's mortality of 1.42% and 2.4% respectively.<sup>[13,25]</sup>

### Conclusion

Complications of CSOM commonly affect the younger age group with low socioeconomic status. Both intracranial and extracranial complications are frequently encountered in our setting. Complications can be prevented if CSOM is treated in time with appropriate medications or meticulous surgery. These complications can be managed successfully with the collaboration of a neurosurgeon if diagnosed promptly and appropriately.

### Declaration of conflicting interests

The author declared no conflicts of interest with respect to the authorship and/or publication of this article.

### Funding

The author received no financial support for the research and/or authorship of this article.

### REFERENCES

1. Aldakhail AA. Chronic suppurative otitis media with intracranial complication. *Neurosciences* 2006;11:322-5.
2. Lin YS, Lin LC, Lee FP and Lee KJ. The prevalence of chronic otitis media and its complication rates in teenagers and adult patients. *Otolaryngol-Head Neck Surg* 2009;140:165-70.
3. Singh M, Jain S, Rajput R, Khatua RK, Sharma D. Retrospective and prospective study of Singapore swing method on healing of mastoid cavity. *Indian J Otolaryngol Head Neck Surg* 2010;62:365-71.
4. Lasisi AO, Olaniyan FA, Muibi SA, Azeez IA, Abdulwasiu KG, Lasisi TJ, et al. Clinical and demographic risk factors associated with chronic suppurative otitis media. *Int J Paediatr Otorhinolaryngol* 2007;71:1549-54.
5. O'Connor TE, Perry CF, Lannigan FJ. Complications of otitis media in Indigenous and non-Indigenous children. *Med J Aust* 2009;191:60-4.
6. Skotnicka B. Complications of otitis media in children in the era of antibioticotherapy. *Otolaryngol Pol* 2007;61:779-83.
7. Yorgancılar E, Yildirim M, Gun R, Bakir S, Tekin R, Gocmez C, et al. Complications of chronic suppurative otitis media: a retrospective review. *Eur Arch Otorhinolaryngol* 2013;270:69-76.
8. Hossain MM, Kundu SC, Haque MR, Shamsuzzaman AK, Khan MK, Halder KK. Extracranial complications of chronic suppurative otitis media. *Mymensingh Med J* 2006;15:4-9.
9. Wu JF, Jin Z, Yang JM, Liu YH, Duan M. Extracranial and intracranial complications of otitis media: 22-year clinical experience and analysis. *Acta Otolaryngol* 2012;132:261-5.
10. Morris PS, Richmond P, Lehmann D, Leach AJ, Gunasekera H, Coates HL. New horizons: otitis media research in Australia. *Med J Aust* 2009;191:S73-7.
11. Baig MM, Ajmal M, Saeed I, Fatima S. Prevalence of cholesteatoma and its complications in patients of chronic suppurative otitis media. *J Rawalpindi Med Coll* 2011;15:16-17.
12. Memon MA, Thaheem K, Marfani MS. Frequency and complications of cholesteatoma in cases of chronic suppurative otitis media. *Pak J Otolaryngol* 2005;21:48-9.
13. Yagizy R, Adali MK, Abdullah TAS, Uzun C, Koten M, Karasalihoglu A. Intracranial complications of chronic suppurative otitis media. *Trakya Univ Tip Fak Derg* 2008;25:196-203.
14. Vikram BK, Khaja N, Udayashankar SG. Clinico-epidemiological study of complicated and uncomplicated chronic suppurative otitis media. *J Laryngol Otol* 2008;122:442-6.
15. Islam MR, Taous A, Hossain MM, Ekramuddaula AFM, Islam MS. Comparative study of tubotympanic and atticointral variety of Chronic suppurative otitis media. *Bangladesh J Otorhinolaryngol* 2010;16:113-9.
16. Magsi PB, Jamro B, Sangi HA. Clinical presentation and outcome of mastoidectomy in chronic suppurative otitis media (CSOM) at tertiary care hospital, Sukkur, Pakistan. *Rawal Med J* 2012;37:50-3.
17. Matanda RN, Muyunga KC, Sabue MJ, Creten W, Van de Heyning P. Chronic suppurative otitis media and related complications at the University Clinic of Kinshasa. *B-ENT* 2005;1:57-62.
18. Ceylan A, Bayazit Y, Yilmaz M, Celenk F, Bayramoglu I, Uygur K, et al. Extracranial complications of chronic otitis media. *Int Adv Otol* 2009;5:51-5.
19. Khan A, Khan MI, Muhammad. Intracranial complications of chronic suppurative otitis media: clinical presentation and outcome of surgical procedures. *Gomal J Med Sci* 2012;10:186-9.
20. Sengupta A, Anwar T, Ghosh D, Basak B. A study of surgical management of chronic suppurative otitis media with cholesteatoma and its outcome. *Indian J Otolaryngol Head Neck Surg* 2010;62:171-6.
21. Miranda HA, Leones SMC, Elzain MA, Salazar LRM. Brain abscess: Current management. *J Neurosci Rural Pract* 2013;4:67-81.
22. Gadgil N, Patel AJ, Gopinath SP. Open craniotomy for brain abscess: A forgotten experience? *Surg Neurol Int* 2013;4:34.
23. Dubey SP, Larawin V. Complications of chronic suppurative otitis media and their management. *The Laryngoscope* 2007;117:264-7.
24. Adoga A, Nimkur T, Silas O. Chronic suppurative otitis media: Socio-economic implications in a tertiary hospital in Northern Nigeria. *Pan Afr Med J* 2010;4:3.
25. Mostafa BE, El Fiky LM, El Sharnouby MM. Complications of suppurative otitis media: still a problem in the 21st century. *ORL J Otorhinolaryngol Relat Spec* 2009;71:87-92.