



Lymphangioma of the tongue: report of four cases with dental aspects

Dil lenfanjiyomu: Diş sorunu olan dört olgu sunumu

Kıvanç Bektaş-Kayhan, MD,¹ Yaren Keskin, MD,¹ Mustafa Caner Kesimli, MD,²
Murat Uluşan, MD,² Meral Ünür, MD.¹

¹Department of Oral Surgery, İstanbul University, Faculty of Dentistry, İstanbul, Turkey

²Department of Otolaryngology, Medical Faculty of İstanbul University, İstanbul, Turkey

Lymphangiomas are rare congenital malformations which are commonly seen in the head and neck region. The disease can be histologically differentiated from other vascular disorders such as cavernous or capillary hemangioma with the lymphatic endothelium-lined cystic spaces. The onset of lymphangiomas are either at birth (60 to 70%) or up to two years of age (90%). It is rare in adults. The therapeutic strategy is mainly based on the surgical removal of the lesion. The risk of recurrence is high in incomplete removal of the lesion. In this article, we discuss the major clinical manifestations, disease-related impairments and dental problems which patients may face as well as treatment options for lymphangioma of the tongue. Within this context, we present four cases of lymphangioma of tongue, including two with a giant macroglossia leading problems in dentition and related dental problems.

Key Words: Dental care; lymphangioma; macroglossia; tongue.

Lenfanjiyomlar, genellikle baş ve boyun bölgesini tutan nadir doğuştan malformasyonlardır. Hastalık, lenfatik endotelium hattı olan kistik boşluklar ile kavernöz veya kapiller hemanjiyom gibi diğer vasküler bozukluklardan histolojik olarak ayırt edilebilir. Lenfanjiyomlar doğuştan olabilir (%60-70) veya iki yaşına kadar gelişebilir (%90). Erişkinlerde nadir görülür. Tedavi stratejisi, esas olarak lezyonun cerrahi olarak çıkarılmasını kapsar. Lezyonun tamamen çıkarılmaması durumunda nüks riski yüksektir. Bu yazıda, hastalığın majör klinik belirtileri, hastaların karşılaşılabileceği hastalık ile ilişkili bozukluklar ve diş sorunlarının yanı sıra dil lenfanjiyomunun tedavi seçenekleri irdelendi. Bu bağlamda, ikisi diş yapısı ve ilgili diş sorunlarına yol açan dev makroglossi olmak üzere, dört dil lenfanjiyom olgusu sunuldu.

Anahtar Sözcükler: Diş sağlığı; lenfanjiyom; makroglossi; dil.

Lymphangiomas are uncommon benign hamartomatous tumors of the lymphatic channels and their clinical presentation is mostly a developmental lesion rather than a true neoplasia.^[1] About 50% of the cases are present at birth and 90% develop by two years of age.^[2] Lymphangiomas have a marked predilection for the head-neck

region but are rare in the oral cavity.^[3] When these tumors occur in the oral cavity, the tongue is the most affected site.^[4] Tongue lymphangiomas typically show multiple blister-like nodules on the enlarged dorsal surface of the tongue. These lesions may also be diffuse, involving large portions of the tongue, causing macroglossia.^[5]



Macroglossia may lead to a dry tongue and secondary infections, difficulty in speech and mastication and numerous dental problems in children.^[6] In this paper we aimed to discuss dental aspects of lymphangioma of the tongue and share our clinical experience with four lymphangioma patients.

CASE REPORT

Case 1- A seven-year-old girl diagnosed with lymphangioma was referred to the Oral Surgery and Medicine Clinics of Dental Faculty with dental carries and occlusion problems. The patient's mother stated that the patient had raised bubbled lesions all over the tongue that grew extensively since she was born. The patient had been operated on many times for macroglossia since she was five years old. These operations consisted of three unsuccessful laser intervention and two more surgical operations including partial glossectomy. According to histopathological examination the diagnosis for the patient was lymphangioma circumscriptum. On clinical examination, the patient presented anterior open-bite due to prolonged macroglossia, discoloration of maxillary incisors and carious deciduous teeth (Figure 1). The patient also presented speech disturbances due to restricted movement of the tongue. After the surgical operation the patient was able to keep her tongue inside and the results were cosmetically good. The patient's prior complaint was pain in the teeth which caused eating problems. Both right and left maxillary first deciduous molars were responsible for the pain. Panoramic radiography showed that the patient had root resorption due to chronic inflammation. The other problem for the patient was gingival

bleeding upon brushing her teeth, keeping her away from regular oral hygiene habits. Oral hygiene instructions and removal of the carious deciduous teeth was planned as a treatment since the patient refused to have orthodontic treatment. The patient had no more pain and gingival bleeding after treatment. The patient is on regular follow-ups (Figure 2).

Case 2- A 12-year-old girl was presented to the Oral Surgery and Medicine Clinics of Dental Faculty with a complaint of recurrent swelling in her tongue. The patient's family was aware of the condition since she was three years old. However no biopsy had been performed before. On anamnesis the patient's mother described that this swelling occurred mostly after an episode of tonsillitis along with fever. No remarkable items were detected in the patient's medical history. In our intraoral examination a lesion, consisting of multiple raised blisters was seen on the left side of the tongue invading both the dorsum and the ventral side. The patient did not have problems with either dentition or occlusion since the tumor was not so big that the tongue was located inside the arches. The intraoral examination revealed caries especially in the left premolars and molars in both maxillary and mandibular arches (maxillary and mandibular first molars and mandibular first premolar teeth were carious), and also the gum inflammation was remarkable. A biopsy was performed, after which the carious teeth were restored along with periodontal treatment. Oral hygiene instructions were given and the patient was taught how to brush her teeth properly. A smaller and softer toothbrush was recommended, especially for the left side with the lesion. After dental treatment, the complaints were gone. According to the

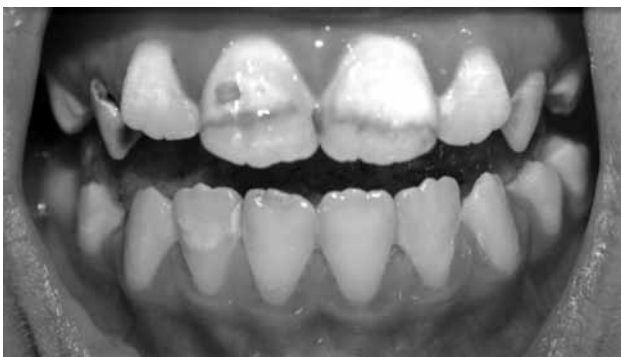

Figure 1. Discoloration of maxillary incisors and carious deciduous teeth.

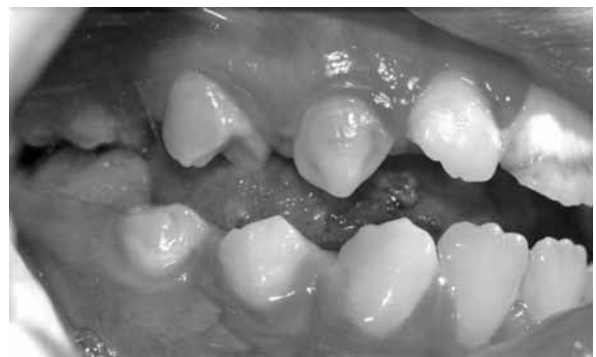

Figure 2. After treatment comprised oral hygiene instruction and removal of the carious deciduous teeth.

biopsy results the diagnosis for the patient was a microcystic lymphangioma. Since the lesion was asymptomatic and there was also no pain, the patient refused to have an operation. The patient's family decided to watch the lesion carefully and keep coming for regular follow-ups. The patient has been on regular follow-ups for three years and eight months with no progression of enlargement in this period.

Case 3- A 29-year-old women was referred to Oral Surgery and Medicine Clinics of Dental Faculty with an acute diffuse enlargement of the tongue. The patient was aware of the lesion for 18 years. She complained of recurrent bleeding from her tongue and moderate pain from time to time especially after episodes of fever (Figure 3). The swelling was usually asymptomatic except for difficulty in eating and sleeping which occurred during episodes of bleeding. The patient stated that the swelling was much bigger and bled more for this time. The medical history of the patient was unremarkable. According to the tongue biopsy the diagnosis for the patient was microcystic lymphangioma. The patient's teeth and gums were not affected since she had a relatively small lesion that allowed the patient to perform regular oral health care. After diagnosis the patient refused to have an operation and has not been on regular follow-ups as well.

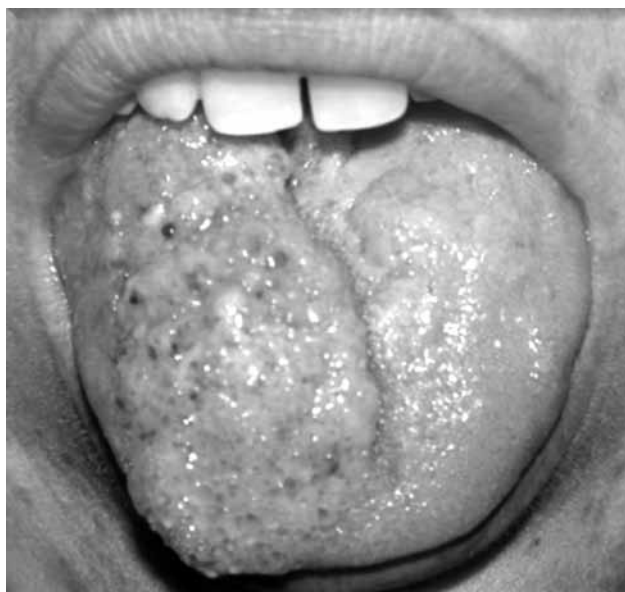


Figure 3. Bubbled lesions on the right side of tongue with macroglossia.

Case 4- A 10-year-old boy previously diagnosed with microcystic lymphangioma was referred to the Oral Surgery and Medicine Clinics of Dental Faculty with pain and bleeding gums. According to the anamnesis the patient was born with lymphangioma in the dorsum of the tongue and the size of the tumor increased with time. The intraoral examination revealed dental caries and abscess in the right maxillary first molar where tenderness was detected (Figure 4). The patient had been operated on three times for massive lymphangioma of the tongue when he was six years old. Since the patient had surgery before eruption of permanent dentition, occlusion was compromised with a cross-bite on the upper lateral incisor. Postoperatively, the patient's tongue was located completely inside with a good cosmetic result. However, there wasn't any progress in his speech. Macroglossia prevented regular oral hygiene activity as well as dental interventions. The patient had caries in both maxillary first molars and in all of deciduous molars. There were no special features in the patient's medical records. Planned therapy included root canal treatment of the right maxillary first molar tooth and restoration of carious deciduous molars. The patient was on regular follow-ups every three months for two years. Since the patient's family decided to move to another province we have not seen the patient anymore.

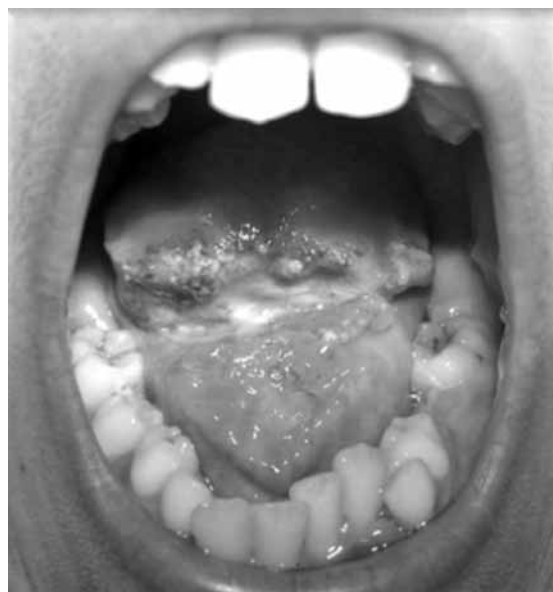

Figure 4. Dental caries and abscess in the right maxillary first molar.

DISCUSSION

Lymphangiomas are rare benign neoplasms that are believed to develop as a result of abnormal development of the lymphatic system.^[7] The precise etiology is still unknown.^[8] The classical classification is based on histological appearance and divided into three as follows; lymphangioma simplex (capillary lymphangioma or lymphangioma circumscriptum), cavernous lymphangiomas and cystic lymphangiomas (cystic hygroma).^[3] However, histologic classes do not correlate with therapeutic response or clinical behavior. Recently, a classification based on morphologic aspects has been more commonly used. According to this, lymphangiomas are classified based on response to sclerotherapy, under three headings; macrocystic, microcystic and mixed type.^[9] Three of our patients had the microcystic type and the other was diagnosed as lymphangioma circumscriptum with no other information available about the classification. Lymphangioma simplex of the tongue is a rare site of occurrence and in the literature only isolated case reports were noticed.^[10,11] The other three cases were evaluated according to the new classification and the type was unique: microcystic.

Many of these lesions are congenital and the majority are diagnosed before two years of age.^[12] Two of our cases (a boy and a girl) were born with lymphangioma in the tongue. The other two manifested the lesion at three and nine years old respectively. Lymphangiomas are thought to have a female tendency which fits our group with three girls and a boy.^[7,13] On the other hand Bonet-Coloma et al.^[12] reported 14 orofacial lymphangiomas in eight boys and six girls and in the series of Wiegand et al.^[14] 29 patients of head-neck lymphangiomas in 16 boys and 13 girls were reported. No larger series of orofacial or oral lymphangiomas are available to discuss.

The mainstay of treatment for tongue lymphangioma is surgery^[15,16] on the other hand sclerotherapy, simple electrocautery, vaporization with CO₂ laser, radiotherapy, pulse-dye laser and radiofrequency could be used as a treatment.^[7,11,17-20] The aim of the treatment for tongue lymphangioma is minimizing the side effects like macroglossia cases as well as difficulty in swallowing and mastication, speech disturbances, exclusive nasal breathing, airway

obstruction, mandibular prognathism and other possible deformities of maxillofacial structures.^[8]

All of the patients were recommended surgery as a treatment since the microcystic type was not responding to sclerotherapy.^[7] Two patients did not want to have surgery so there was no option but continuous follow-ups.^[21] The other two had already had operations. They had been seriously affected because of severe macroglossia and they had partial glossectomy operations at the age of five and six years old. Unfortunately, both of the patients have recurrent disease and they have also experienced numerous surgical interventions. In the literature, recurrence after removing lymphangiomas is seen in 41% of cases.^[6] For huge lymphangiomas of any type, total resection is not a proper treatment because tumors may include vital structures. The aim of the surgery is only reduction of the size of the tongue in order to eliminate the problems ranked above.^[8,22] Thus, residual tumor may be expected as is probable in both cases of partial glossectomies, resulting in recurrence.

Symptoms are related to the location, size and the extent of the lymphangioma. For dentists, the disease can be classified as associated with dentition and not associated with dentition. In most cases the negative relation relies on tongue tumors that create macroglossia in particular when appropriate treatment is not available in time.

Dental preventive programs must be performed especially for children with macroglossia until surgery is possible. The inability to perform normal dental hygiene activities increases the risk of caries and gingivitis.^[8] Adequate surgery helps patients to keep the tongue inside as a good cosmetic result and they also have less orthognathic deformities. Pediatric dentists are not only focusing on hard tissues but also soft tissues during intraoral examinations. In describing cases two of them were diagnosed in the Oral Surgery and Medicine Clinics of Dental Faculty. The other two had dental problems due to macroglossia. Many lesions of tongue lymphangiomas are recognized and diagnosed by dentists.^[23]

Tongue lymphangioma causes macroglossia among children in common leading to a dry and cracked tongue with ulcerating secondary infections, difficulty in swallowing

and mastication, speech disturbances, exclusive nasal breathing, airway obstruction, mandibular prognathism and other possible deformities of maxillofacial structures.

The patients must be treated by preventive dentistry since these cases do not require any special skills to be treated. The differential diagnosis of early lesions must be taken into consideration to get better treatment results.

Declaration of conflicting interests

The authors declared no conflicts of interest with respect to the authorship and/or publication of this article.

Funding

The authors received no financial support for the research and/or authorship of this article.

REFERENCES

- Neville BW, Damn DD, Allen CM, Bouquot JE. Soft Tissue Tumors. In: Oral and Maxillofacial Pathology. 3rd ed. Philadelphia: W.B. Saunders; 1995. p. 547-9.
- Khurana S, Vij A, Singal A, Pandhi D. Lymphangioma of the tongue: response to intralesional steroids. *J Dermatolog Treat* 2006;17:124-6.
- Rathan JJ, Vardhan BG, Muthu MS, Venkatachalapathy, Saraswathy K, Sivakumar N. Oral lymphangioma: a case report. *J Indian Soc Pedod Prev Dent* 2005;23:185-9.
- Hudson JW, Meszaros EJ. Submucosal lymphangioma of the maxillary sinus. *J Oral Maxillofac Surg* 2003;61:390-2.
- Yaita T, Onodera K, Xu H, Ooya K. Histomorphometrical study in cavernous lymphangioma of the tongue. *Oral Dis* 2007;13:99-104.
- Guelmann M, Katz J. Macroglossia combined with lymphangioma: a case report. *J Clin Pediatr Dent* 2003;27:167-9.
- Leboulanger N, Roger G, Caze A, Enjolras O, Denoyelle F, Garabedian EN. Utility of radiofrequency ablation for haemorrhagic lingual lymphangioma. *Int J Pediatr Otorhinolaryngol* 2008;72:953-8.
- de Queiroz AM, Silva RA, Margato LC, Nelson-Filho P. Dental care management of a young patient with extensive lymphangioma of the tongue: a case report. *Spec Care Dentist* 2006;26:20-4.
- Bloom DC, Perkins JA, Manning SC. Management of lymphatic malformations. *Curr Opin Otolaryngol Head Neck Surg* 2004;12:500-4.
- Bansal A. Lymphangioma circumscriptum of the tongue. *Indian Pediatr* 2006;43:650-1.
- Kataria P, Passey JC, Agarwal AK. Lymphangioma circumscriptum of the tongue: successful treatment using intralesional bleomycin. *J Laryngol Otol* 2009;123:1390-2.
- Bonet-Coloma C, Minguez-Martínez I, Aloy-Prósper A, Rubio-Serrano M, Peñarrocha-Diago MA, Peñarrocha-Diago M. Clinical characteristics, treatment, and evolution in 14 cases of pediatric orofacial lymphangioma. *J Oral Maxillofac Surg* 2011;69:e96-9.
- Brennan TD, Miller AS, Chen SY. Lymphangiomas of the oral cavity: a clinicopathologic, immunohistochemical, and electron-microscopic study. *J Oral Maxillofac Surg* 1997;55:932-5.
- Wiegand S, Eivazi B, Zimmermann AP, Sesterhenn AM, Werner JA. Evaluation of children with lymphatic malformations of the head and neck using the Cologne Disease Score. *Int J Pediatr Otorhinolaryngol* 2009;73:955-8.
- Jian XC. Surgical management of lymphangiomatous or lymphangiohemangiomatous macroglossia. *J Oral Maxillofac Surg* 2005;63:15-9.
- Chen WL, Zhang B, Wang JG, Ye HS, Zhang DM, Huang ZQ. Surgical excision of cervicofacial giant macrocystic lymphatic malformations in infants and children. *Int J Pediatr Otorhinolaryngol* 2009;73:833-7.
- Bozkaya S, Uğar D, Karaca I, Ceylan A, Uslu S, Barış E, et al. The treatment of lymphangioma in the buccal mucosa by radiofrequency ablation: a case report. *Oral Surg Oral Med Oral Pathol Oral Radiol Endod* 2006;102:e28-31.
- Wiegand S, Eivazi B, Zimmermann AP, Sesterhenn AM, Werner JA. Sclerotherapy of lymphangiomas of the head and neck. *Head Neck* 2011;33:1649-55.
- Wang LC, Krunic AL, Medenica MM, Soltani K, Busbey S. Treatment of hemorrhagic lymphatic malformation of the tongue with a pulsed-dye laser. *J Am Acad Dermatol* 2005;52:1088-90.
- Demir E, İsen K, Büyükbayram H. Lymphangioma circumscriptum of the glans penis treated with advanced fluorescence technology pulsed light therapy: case report. *Türkiye Klinikleri J Med Sci* 2010;30:1417-20.
- Perkins JA, Manning SC, Tempero RM, Cunningham MJ, Edmonds JL Jr, Hoffer FA, et al. Lymphatic malformations: review of current treatment. *Otolaryngol Head Neck Surg* 2010;142:795-803.
- Tei E, Yamataka A, Komuro Y, Ohshiro K, Yanai A, Lane GJ, et al. Huge lymphangioma of the tongue: a case report. *Asian J Surg* 2003;26:228-30.
- Tewari A, Munjal M, Kamakshi, Garg S, Sood D, Katyal S. Anaesthetic consideration in macroglossia due to lymphangioma of tongue: a case report. *Indian J Anaesth* 2009;53:79-83.