



# Adenoid cystic carcinoma of the accessory parotid gland

## Aksesuar parotis bezinin adenoid kistik karsinomu

Deniz Baklacı, MD,<sup>1</sup> Volkan Güngör, MD,<sup>1</sup> Müge Özcan, MD,<sup>1</sup> Yavuz Fuat Yılmaz, MD,<sup>1</sup>  
Adnan Ünal, MD,<sup>2</sup> Aysel Çolak, MD.<sup>3</sup>

<sup>1</sup>Department of Otolaryngology, Ankara Numune Training and Research Hospital, Ankara, Turkey

<sup>2</sup>Department of Otolaryngology, Medical Faculty of Hitit University, Çorum, Turkey

<sup>3</sup>Department of Pathology, Ankara Numune Training and Research Hospital, Ankara, Turkey

### ABSTRACT

Accessory parotid gland is a small salivary gland tissue separated from main part of parotid gland. It is located on the masseter muscle anterior to the Stensen's duct. Tumors of accessory parotid gland are rare. In this article, we report an unusual case of adenoid cystic carcinoma involving accessory parotid gland. The patient presented with a progressively growing mass in the middle portion of her cheek. She underwent a partial parotidectomy including both the superficial and accessory lobes. The histopathologic diagnosis was adenoid cystic carcinoma of cribriform type.

**Keywords:** Accessory parotid gland; adenoid cystic carcinoma; parotid neoplasm.

### ÖZ

Aksesuar parotis bezi, parotis bezinin ana parçasından ayrı küçük bir tükürük bezi dokusudur. Stensen kanalının ön tarafında, masseter kasın üzerinde yer alır. Aksesuar parotis bezi tümörleri nadirdir. Bu yazıda, aksesuar parotis bezini tutan nadir bir adenoid kistik karsinom olgusu sunuldu. Hasta yanağının orta kısmında progresif olarak büyüyen bir kitle ile başvurdu. Yüzeysel ve aksesuar lobları içeren parsiyel parotidektomi yapıldı. Histopatolojik tanı kribriform tip adenoid kistik karsinom idi.

**Anahtar Sözcükler:** Aksesuar parotis bezi; adenoid kistik karsinom; parotis neoplazmi.

The accessory parotid gland is a small salivary gland tissue separated from the main part of the parotid gland. It lies on the masseteric muscle anterior to Stensen's duct. The accessory parotid gland has its own blood supply from the transverse cervical artery and its own duct emptying into the parotid duct. It appears in 21-69% of individuals.<sup>[1]</sup> Tumors of the accessory parotid gland are rare and 1-8% of all parotid gland tumors arise from the accessory parotid gland.<sup>[2]</sup> All pathological types of parotid gland

tumors may occur in the accessory parotid gland. It has been estimated that 50% of accessory parotid gland tumors are malignant.<sup>[2,3]</sup>

Adenoid cystic carcinoma is a relatively rare parotid gland tumor constituting only 2-3% of all parotid gland tumors.<sup>[4]</sup> These malignant tumors are characterized by wide local infiltration, perineural spread, distant metastasis and a slow growing pattern. They have a remarkable capacity for recurrence. Adenoid cystic



carcinoma has three histopathological patterns--tubular, cribriform and solid. The solid pattern is associated with increased local recurrence, and higher rates for metastasis and mortality.

Accessory parotid gland tumors can be approached through a standard parotidectomy incision and excised together with superficial parotid tissue. Accessory gland tumors can also be excised directly with a skin incision over the tumor, without performing a superficial parotidectomy. This approach may result in facial nerve damage as the fine anterior branches run close to the duct. Following this method, a high risk for local recurrence can also be expected, especially in the case of pleomorphic adenoma or malignant tumors.<sup>[5]</sup> Intraoral excision and facelift approach can also be used.<sup>[6]</sup>

In this article, we report an adenoid cystic carcinoma arising from the accessory parotid gland, and to our knowledge, this is the second case reported in the English literature.

#### CASE REPORT

A 35-year-old woman had complained of a slowly-growing swelling in the middle portion of her right cheek for five months. On physical examination, there was a 2x2 cm firm, well defined and mobile mass on the right side of the cheek. Facial functions were normal bilaterally. Ultrasound-guided fine needle aspiration biopsy was reported as "the histopathological findings are primarily suggestive of adenoid cystic carcinoma but basaloid tumors could not be excluded." Magnetic resonance imaging showed a well-circumscribed 21x20x13 mm nodular mass in the right accessory parotid gland (Figure 1).

The tumor was approached through a modified Blair incision. The skin flap was raised anteriorly until adequate exposure achieved for the accessory lobe. The facial nerve was identified, exposed and all accessory lobe containing the tumor 3 cm in size was excised together with superficial lobe of parotid gland (Figure 2). The branches of facial nerve were not invaded by the tumor.

The facial nerve functions were normal postoperatively and no external salivary fistula was observed. Histopathological examination confirmed grade 1 cribriform type adenoid cystic carcinoma (Figure 3). No adjuvant therapy was given by our institution's tumor board. There was no recurrence after six months of follow-up.

#### DISCUSSION

Tumors of the accessory parotid gland are extremely rare. Some reports estimated that 50% of accessory parotid gland tumors were malignant.<sup>[2,3]</sup> Johnson and Spiro<sup>[7]</sup> reported that 1% of all parotid neoplasms arose from accessory parotid glands, more than a quarter of which were primary malignant tumors. Perzik and White<sup>[8]</sup> reported that 7.7% of parotid neoplasms arose from the accessory parotid gland and 26% of these tumors were malignant. According to Newberry et al.,<sup>[9]</sup> pooled data of 152 reported cases in the literature indicate that 30% of all reported tumors of the accessory parotid gland were malignant. Overall the most common malignant tumors were mucoepidermoid carcinoma (13%) and acinic-cell carcinoma (4%). To our knowledge, there is only one published case of adenoid cystic carcinoma arising from the

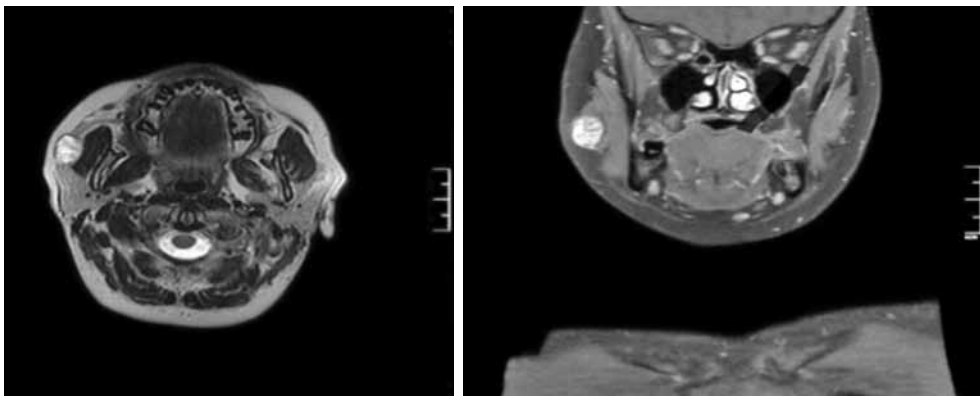
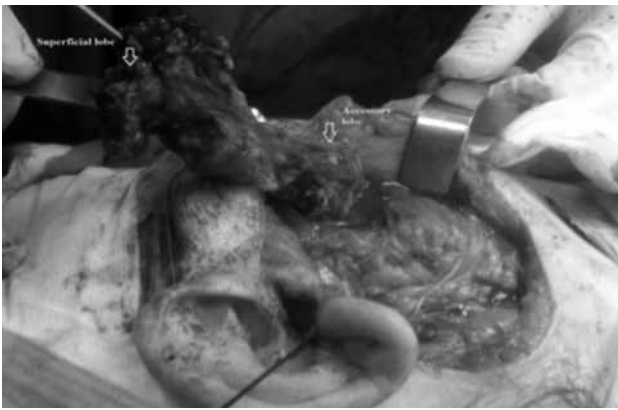


Figure 1. Magnetic resonance imaging showed a well-shaped mass in the right accessory parotid gland.



**Figure 2.** Accessory parotid lobe containing the tumor 3 cm in size was excised with superficial lobe of parotid gland.

accessory parotid lobe in the English literature reported by Johnson and Spiro in 1989.

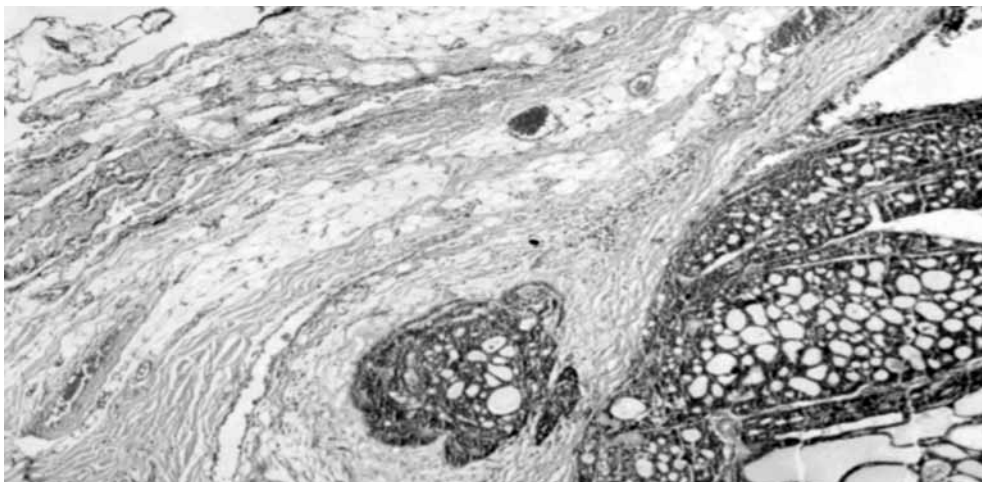
Adenoid cystic carcinoma is one of the most common salivary gland tumors. It usually involves the parotid, submandibular and minor salivary glands. This tumor is also well known for perineural invasion. Clinically it appears as a slow-growing mass with local pain, facial paralysis due to neural invasion and local invasion to deeper structures.

Eveson and Cawson<sup>[10]</sup> found a predominance of adenoid cystic carcinoma in women (F:M=1.2:1) with the ages of the patients between 24 and 78 years. The tumors most frequently appeared in the seventh decade of life with an average of 66.3 years. Histopathologically, adenoid cystic

carcinoma has three characteristic patterns. Huang et al.<sup>[11]</sup> observed a survival rate of 16.7% after 10 year treatment in cases with solid pattern and 47.4% in cases with cribriform and tubular forms. The authors concluded that the main factors associated with patient survival were tumor location, clinical stage and the observed histological pattern.

Surgery is the primary treatment of adenoid cystic carcinoma. In the advanced stages and in the presence of positive microscopic margins adjuvant radiotherapy may be considered. In parotid lesions, a radical parotidectomy procedure is advocated, though the main intent is to obtain a tumor-free area for at least 1 cm.<sup>[12]</sup> Neck dissection is not indicated since metastasis to regional lymph nodes is uncommon. Some authors suggested that advanced or non-resectable tumors might be treated only with radiotherapy.

Tumor free (at least 1 cm) resection is the primary aim for accessory lobe tumors similar to other parotid tumors. On the other hand, these tumors are rare and surgical experience for accessory lobe tumors is insufficient in the literature. Newberry et al.<sup>[9]</sup> published their six-year accessory parotid gland surgery experience which consisted of six malignant and seven benign tumors. Of six malignant tumors, two were mucoepidermoid carcinomas, two were B-cell lymphomas, one was adenocarcinoma, and one was myofibrosarcoma of the accessory parotid gland. In this paper, the authors utilized extended parotidectomy/pre-auricular incision,



**Figure 3.** Cribriform type of adenoid cystic carcinoma separated from the salivary gland tissue with a thick capsule. The capsule is invaded by tumor cells, but surrounding normal salivary gland parenchyma is not invaded (H-E x 200).

and after elevation of the skin flaps superficial and anterior to the accessory parotid tumor, they identified distal branches of the facial nerve. Then, they removed accessory lobe tumor with a cuff of tissue with the distal nerves, under direct vision. They also included parotidectomy and radiotherapy in the adenocarcinoma case.

In our case, we preferred a partial parotidectomy approach with a wider incision than the modified Blair incision, and identified and preserved the facial nerve. With a wider incision, we elevated the skin flap until the masseteric muscle and achieved a good exposure for the accessory lobe. After that, we followed the facial nerve branches until we exposed all accessory lobe, and resected it with the superficial parotid lobe.

#### Declaration of conflicting interests

The authors declared no conflicts of interest with respect to the authorship and/or publication of this article.

#### Funding

The authors received no financial support for the research and/or authorship of this article.

#### REFERENCES

- Toh H, Kodama J, Fukuda J, Rittman B, Mackenzie I. Incidence and histology of human accessory parotid glands. *Anat Rec* 1993;236:586-90.
- Lewkowicz A, Levy Y, Zeltser R, Zagury A, Nahlieli O. Accessory parotid gland masses. *Oral Surg Oral Med Oral Pathol Oral Radiol Endod* 2000;89:610-2.
- Schmutzhard J, Schwentner IM, Andrlé J, Gunkel AR, Sprinzl GM. Resection of accessory parotid gland tumors through a peroral approach with facial nerve monitoring. *J Craniofac Surg* 2007;18:1419-21.
- Bouquot NDA. Salivary gland pathology. In: Neville BW, Damm DD, Allen CM, Bouquot JE, editor. *Oral and Maxillofacial Pathology*. 2nd ed. Philadelphia: W.B. Saunders; 2002. p. 426-8.
- Choi HJ, Lee YM, Kim JH, Tark MS, Lee JH. Wide excision of accessory parotid gland with anterior approach. *J Craniofac Surg* 2012;23:165-8.
- Lin DT, Coppit GL, Burkey BB, Nettekville JL. Tumors of the accessory lobe of the parotid gland: a 10-year experience. *Laryngoscope* 2004;114:1652-5.
- Johnson FE, Spiro RH. Tumors arising in accessory parotid tissue. *Am J Surg* 1979;138:576-8.
- Perzik SL, White IL. Surgical management of preauricular tumors of the accessory parotid apparatus. *Am J Surg* 1966;112:498-503.
- Newberry TR, Kaufmann CR, Miller FR. Review of accessory parotid gland tumors: pathologic incidence and surgical management. *Am J Otolaryngol* 2014;35:48-52.
- Eveson JW, Cawson RA. Tumours of the minor (oropharyngeal) salivary glands: a demographic study of 336 cases. *J Oral Pathol* 1985;14:500-9.
- Huang M, Ma D, Sun K, Yu G, Guo C, Gao F. Factors influencing survival rate in adenoid cystic carcinoma of the salivary glands. *Int J Oral Maxillofac Surg* 1997;26:435-9.
- Marx RE, Stern D. Salivary gland neoplasm. In: *Oral and Maxillofacial Pathology: A Rationale for Treatment*. 1st ed. Miami: Quintessence Publishing; 2002. p. 550-3.