



Cochlear implantation: case report on incomplete partition type III

Koklear implantasyon: İnkomplet partision tip III üzerine olgu sunumu

Müge Özcan, MD.,¹ Rauf Oğuzhan Kum, MD.,² Deniz Baklacı, MD.,² Görkem Dünder, MD.,²
Yavuz Fuat Yılmaz, MD.,² Uğur Toprak, MD.,² Adnan Ünal, MD.²

¹Department of Otolaryngology, Hitit University Medical School, Çorum, Turkey

²Department of Otolaryngology, Ankara Numune Training And Research Hospital, Ankara, Turkey

ABSTRACT

Incomplete partition (IP) type III anomaly (X-linked deformity, IP type III) is a rare malformation of the inner ear. In these patients, cochlear implant surgery can be performed successfully. In this case report, we discussed the problems regarding cochlear implantation in patients with IP type III anomaly and profound sensorineural hearing loss. Cochlear implantation is a good choice for these patients. However, IP type III anomaly may pose some unusual risks in addition to other inner ear abnormalities. Therefore, the surgeon should be aware of these and must be ready to inform the patient and parents about possible complications.

Keywords: Cochlear implant; incomplete partition type III anomaly; inner ear anomaly.

ÖZ

İnkomplet partision (İP) tip III anomalisi (X-bağımlı deformite, İP tip III) iç kulağın nadir bir malformasyonudur. Bu hastalarda koklear implant cerrahisi başarıyla uygulanabilir. Bu olgu sunumunda, İP tip III anomalisi ve şiddetli sensörinöral işitme kaybı olan hastalarda koklear implantasyon ile ilgili problemler tartışıldı. Koklear implantasyon bu hastalar için iyi bir tercihtir. Ancak İP tip III anomalisi diğer iç kulak anormalliklerine ek olarak bazı olağandışı riskler oluşturabilir. Dolayısıyla, cerrah bunları bilmeli ve hastayı ve ebeveynleri olası komplikasyonlar hakkında bilgilendirmeye hazır olmalıdır.

Anahtar Sözcükler: Koklear implant; inkomplet partision tip III anomalisi; iç kulak anomalisi.

Congenital malformations of inner ear are rare conditions representing approximately 20% of all congenital sensorineural hearing loss (SNHL).^[1] Patients with inner ear anomalies are difficult cases for cochlear implant surgery. However, developing radiological imaging techniques and increasing surgical experience make these patients potential candidates for cochlear implantation.^[2] Aplasia of inner ear is a

contraindication for implant surgery. Mangabeira Albernaz first performed cochlear implantation in a patient with cochlear malformation in 1983, but they realized the malformation during revision surgery.^[3]

In this paper we report the clinical features and potential surgical difficulties during cochlear implantation in a patient with profound SNHL and incomplete partition (IP) type III anomaly.



CASE REPORT

A 15-year-old male patient was referred to our clinic with progressive SNHL. He had a history of febrile convulsions after birth and showed profound hearing loss (HL) in both ears on audiological examination. He had been using bilateral hearing aids since he was three years old, but he still had hearing problems and his speech development started to get worse. Preoperative temporal bone high resolution computed tomography (HRCT) and magnetic resonance imaging (MRI) were performed. The HRCT showed bilateral bulbous dilatation at the

lateral ends of the internal auditory canals (IAC) (Figure 1). Additionally, there were bilateral enlargements of the labyrinthine segments of the facial nerve canals (Figure 2). Both basal turns of the cochlea were incompletely separated from, and seemed to be a continuation of, the IACs (Figure 1). Both modioli were completely absent. Based on preoperative radiological evaluation, an incomplete partition type III anomaly was diagnosed. The patient had vaccinations for *Pneumococcus* and *Haemophilus influenza*. Cochlear implantation surgery was performed on his left ear. The stapes was found fixed. The

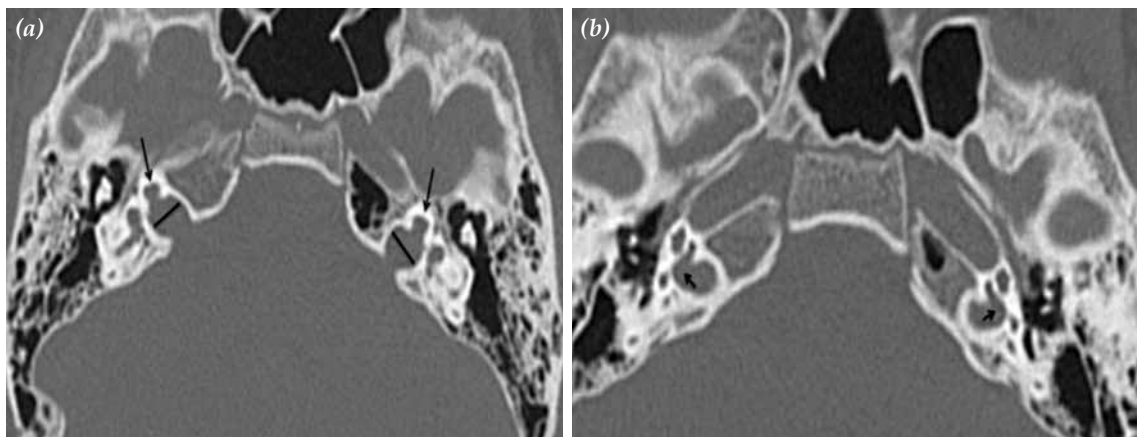


Figure 1. High resolution computed tomography, axial sections, showing bilateral bulbous dilatation at the lateral ends of both internal auditory canals. The basal turns of the cochlea were incompletely separated from, and seemed to be a continuation of the internal auditory canals (arrows).

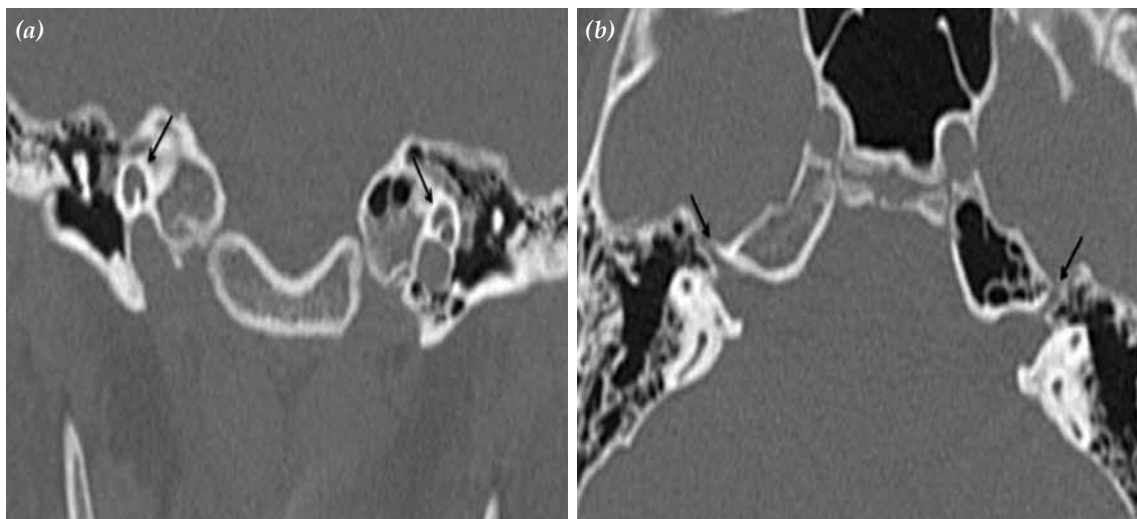


Figure 2. High resolution computed tomography, coronal section (a), showing bilateral cochlear hypoplasia (arrows); Axial section (b), showing bilateral enlargement of the labyrinthine segments of the facial nerve canals (arrows).

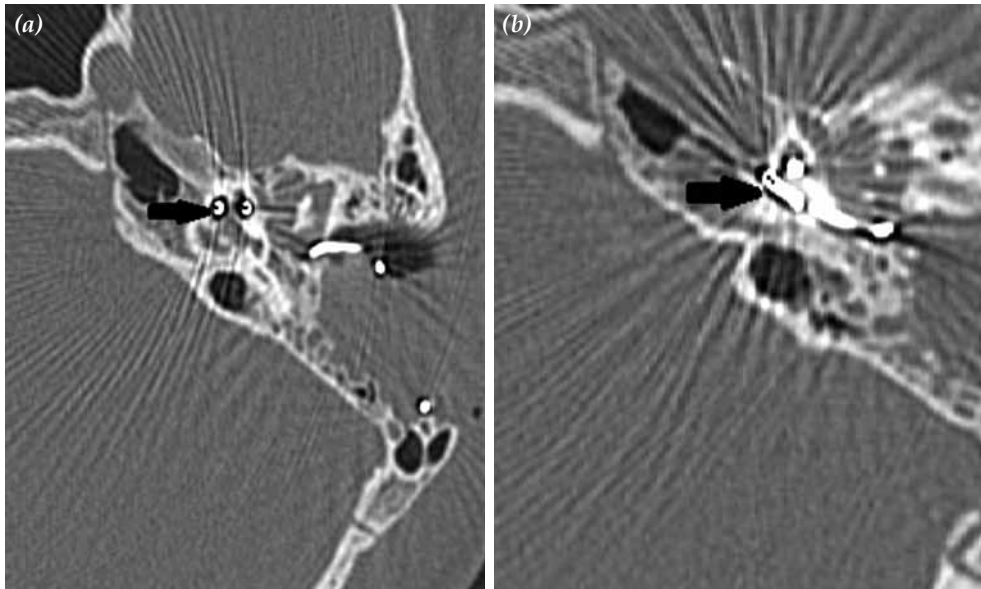


Figure 3. Postoperative temporal bone high resolution computed tomography of the left ear shows cochlear implant properly positioned in the cochlea.

round window niche was drilled and round window membrane made visible. After opening the round window membrane a perilymph gusher occurred. The gusher lasted 30 min, and was controlled with head elevation and administration of intravascular mannitol. A small piece of temporal muscle was plugged into the cochleostomy to prevent perilymphatic leakage. A Nucleus CI24RE Contour Advance straight array with full band electrodes was fully inserted into the cochlea through the round window cochleostomy. The values of the neural response telemetry (NRT) were evaluated for the 13th, 19th and 22th electrodes and were normal. On stimulation of the 19th electrode, the facial nerve was stimulated, and this electrode was switched off. The stapes reflex was positive

and postoperative facial nerve function was normal. Postoperative temporal bone HRCT imaging showed that the electrode was in normal location in the cochlea (Figure 3).

Post-implantation results were good. At 1.5 years after implantation, free field audiometry showed an average threshold of 40 dB HL, the child is able to identify words in a closed and open set. The child is also able to understand simple phrases and orders.

DISCUSSION

In 1987, Jackler et al.^[4] classified inner ear malformations into complete labyrinthine anomaly (Michel deformity), cochlear aplasia, common cavity deformity, cochlear hypoplasia

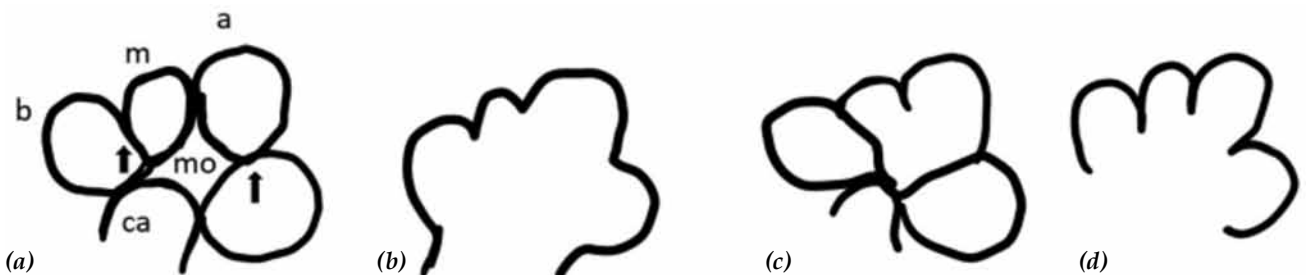


Figure 4. Schematic representation of the normal cochlea and incomplete partition anomalies of the cochlea. (a) Normal cochlea, midmodiolar section; mo: Modiolus; ca: Cochlear aperture; (b) incomplete partition type I; (c) incomplete partition type II; and (d) incomplete partition type III.^[7]

and incomplete partition anomaly. Phippard et al.^[5] addressed this malformation as pseudo Mondini stage II, described as partial hypoplasia of the cochlea, stapes fixation, dilated IAC and abnormal communication with the base of the cochlear duct. Sennaroglu and Saatci^[6] described a new classification in 2002. By the improvement of imaging techniques and increased knowledge of inner ear malformations, Sennaroglu^[7] published a review article in 2010 and this classification is commonly used.

Although patients with IP type III anomaly may show different phenotypic and genotypic features, their temporal bone HRCT findings demonstrate this malformation. In this deformity the interscalar septum is present but the modiolus is completely absent. The cochlea is placed directly at the lateral end of the IAC, instead of its typical anterolateral position (Figure 4).^[7] Because of the abnormal communication between the subarachnoid and perilymphatic spaces, there is an increased risk of gushers during stapes manipulation, and recognition of the IP type III anomaly is essential, precluding stapes surgery.

Incomplete partition type III anomaly shows X-recessive type of inheritance and the expectancy of severe HL in male patients and mild to moderate or delayed onset hearing impairment in females. In our case, we asked the patient's parents about a family history of severe and profound HL, and found that there were five relatives who underwent cochlear implant surgery at different ages. To the best of our knowledge, IP type III also causes profound HL in women and it causes late onset HL.^[2] Incomplete partition type III anomaly could be related to a syndrome that is yet undefined. A large number of research and additional cases are needed to establish this.

High resolution CT and MRI scans are very useful imaging studies to diagnose inner ear abnormalities. It had earlier been thought that the wide CT sections were enough to exclude congenital malformations. However, our clinical experience from inner ear malformations, HRCT scans should be obtained with at least 1 mm thick slices. The otolaryngologist should collaborate with a neuroradiologist in the management of these problematic cases. Our clinical experience shows that in children with SNHL, temporal bone

CT evaluation should be performed to diagnose the inner ear malformation. The rationale for this procedure was the high percentage of meningitis due to this anomaly in this group of patients.^[8] In this way, detection of any abnormality of the inner ear enables us catch meningitis and its complications, and prepare the family for possible meningitis sequela. An MRI scan is crucial to assess the cochlear nerve. If any inner ear anomaly was identified by HRCT, preoperative MRI must be performed to confirm the existence of the cochlear nerve. In our case, we confirmed the presence of the cochlear nerve on MRI scan.

In a normal anatomic inner ear, the perilymphatic space and subarachnoid space are separated from each other by the lamina cribrosa. Abnormal connections between these two spaces can present in inner ear malformations. This anatomic deficiency can explain why perilymph or cerebrospinal fluid (CSF) gushers occur during surgery. When CSF gushers occur, the head should be lifted, waiting until a clean and visible surgical area is regained. Cochleostomy sizes are also important in preventing perilymph gushers. For this, some authors suggest a minimal cochleostomy^[9] but in our case we try to obtain a standard cochleostomy size.

Meningitis is one of the complications that could occur after cochlear implant surgery. It is also believed to carry a higher risk of meningitis in children with inner ear abnormalities.^[10] Preoperative vaccination and covering the cochleostomy with temporal fascia may help to prevent postoperative possible meningitis risk. The surgeon must pay attention to achieve firm sealing of the cochleostomy in these patients, to prevent leakage of perilymphatic fluid.

The selection of electrode type is very important in cases with inner ear abnormalities. In most cases with inner ear anomaly, the amount of spiral ganglion cells seems to be enough to obtain successful hearing results. However the settlement of neural tissue may be different. For this reason, circumferential stimulator electrode devices could be more appropriate. On the other hand the full-banded electrode would be very risky because of facial nerve stimulation. It was reported that incidence of facial nerve stimulation was 1.89% in the

pediatric population.^[11] The possible mechanism of facial nerve stimulation in children with inner ear malformation was the proximity of the facial nerve to the electrode, dehiscence or an aberrant facial nerve. Most of the time, switching off the responsible electrodes can solve this problem. In our case the number 19 electrode stimulated the facial nerve and was switched off.

Conclusion

This case suggests that cochlear implantation is a suitable option for treatment of patients with IP type III (X-linked SNHL). We performed the standard transmastoid facial recess approach and completed the surgery without any complication. However, these anomalies have specific problems like perilymph gushers. The surgical team should be aware of all these problems and inform the patient and family of possible complications before surgery.

Acknowledgement

We want to thank Mrs. Serpil Allusoglu for her valuable contributions.

Declaration of conflicting interests

The authors declared no conflicts of interest with respect to the authorship and/or publication of this article.

Funding

The authors received no financial support for the research and/or authorship of this article.

REFERENCES

1. Jensen J. Malformations of the inner ear in deaf children. *Acta Radiol Suppl* 1969;286:1-97.
2. Tucci DL, Telian SA, Zimmerman-Phillips S, Zwolan TA, Kileny PR. Cochlear implantation in patients with cochlear malformations. *Arch Otolaryngol Head Neck Surg* 1995;121:833-8.
3. Mangabeira-Albernaz PL. The Mondini dysplasia--from early diagnosis to cochlear implant. *Acta Otolaryngol* 1983;95:627-31.
4. Jackler RK, Luxford WM, House WF. Congenital malformations of the inner ear: a classification based on embryogenesis. *Laryngoscope* 1987;97(3 Pt 2 Suppl 40):2-14.
5. Phippard D, Heydemann A, Lechner M, Lu L, Lee D, Kyin T, et al. Changes in the subcellular localization of the Brn4 gene product precede mesenchymal remodeling of the otic capsule. *Hear Res* 1998;120:77-85.
6. Sennaroglu L, Saatci I. A new classification for cochleovestibular malformations. *Laryngoscope* 2002;112:2230-41.
7. Sennaroglu L. Cochlear implantation in inner ear malformations--a review article. *Cochlear Implants Int* 2010;11:4-41.
8. Park AH, Kou B, Hotaling A, Azar-Kia B, Leonetti J, Papsin B. Clinical course of pediatric congenital inner ear malformations. *Laryngoscope* 2000;110:1715-9.
9. Weber BP, Dillo W, Dietrich B, Maneke I, Bertram B, Lenarz T. Pediatric cochlear implantation in cochlear malformations. *Am J Otol* 1998;19:747-53.
10. Tullu MS, Khanna SS, Kamat JR, Kirtane MV. Mondini dysplasia and pyogenic meningitis. *Indian J Pediatr* 2004;71:655-7.
11. Battmer R, Pesch J, Stöver T, Lesinski-Schiedat A, Lenarz M, Lenarz T. Elimination of facial nerve stimulation by reimplantation in cochlear implant subjects. *Otol Neurotol* 2006;27:918-22.