



Facial nerve abnormality on parotidectomy for Warthin tumor in a case of aural atresia

Murat Binar, Ümit Aydın, Ömer Karakoç, Mert Cemal Gökgöz, Hamdi Taşlı

Department of Otolaryngology, Gülhane Training and Research Hospital, Ankara, Turkey

ABSTRACT

To our knowledge, the coexistence of Warthin tumor and ipsilateral aural atresia has not been reported before. This situation may affect facial nerve structure and present a surgically challenging situation during superficial parotidectomy. A 68-year-old woman with right aural atresia was operated on due to a parotid mass below the atretic ear. Computed tomography and intraoperative findings demonstrated unusual properties of the facial nerve: (i) Extratemporal beginning was more superiorly located, (ii) Facial trunk was relatively longer and more vertical, (iii) Buccal, marginal mandibular, and cervical branching from the unique ring structure of the facial nerve. All facial nerve branches were preserved after careful dissection and the lesion was completely excised. Final histopathologic diagnosis was Warthin tumor. In order to preserve the facial nerve during parotid surgery and to avoid morbidity, it is necessary for surgeons to be familiar with different types of extratemporal facial nerve anatomy especially in cases of additional anomalies such as aural atresia.

Keywords: Anatomy; aural atresia; facial nerve; parotidectomy; variation; Warthin tumor.

Aural atresia is a rare congenital malformation of the ear and its incidence ranges from 1:10,000 to 1:20,000.^[1] The varying degrees of malformations of the tympanic membrane, ossicular chain, and middle ear may be involved, and the typical pattern of hearing loss in affected ears is a conductive hearing loss.^[2] In most cases, aural atresia is seen unilaterally.^[3-5] Due to concurrent embryological development, other syndromal abnormalities may accompany aural atresia.^[3,4,6]

Warthin tumor, also known as papillary cystadenoma lymphomatosum, was first described by Warthin in 1929.^[7] This tumor constitutes 2-15% of all parotid tumors and is more commonly seen in males.^[8,9] The treatment requires complete excision of the mass and affected portion of the gland with

uninvolved margins due to the risk of malignant evolution.^[8,10]

To the best of our knowledge, there is no report in the English literature demonstrating the coexistence of Warthin tumor and ipsilateral aural atresia. We describe how the facial nerve was affected, and discuss how it affects performing parotid surgery.

CASE REPORT

A 68-year-old woman with right aural atresia was admitted to our clinic due to one-year history of swelling below the atretic ear. Physical examination showed a right infraauricular solid mass below the atretic ear, 2×3 cm in size (Figure 1). There was no facial paralysis and the rest of the otorhinolaryngologic examination was normal. Fine needle aspiration cytologic

Received: October 11, 2017 Accepted: January 11, 2018

Correspondence: Murat Binar, MD. SBÜ Gülhane Eğitim ve Araştırma Hastanesi Kulak Burun Boğaz Kliniği, 06010 Etilik, Ankara, Turkey.

e-mail: mbinar4@yahoo.com

Doi: <http://dx.doi.org/10.5606/Tr-ENT.2018.98372>

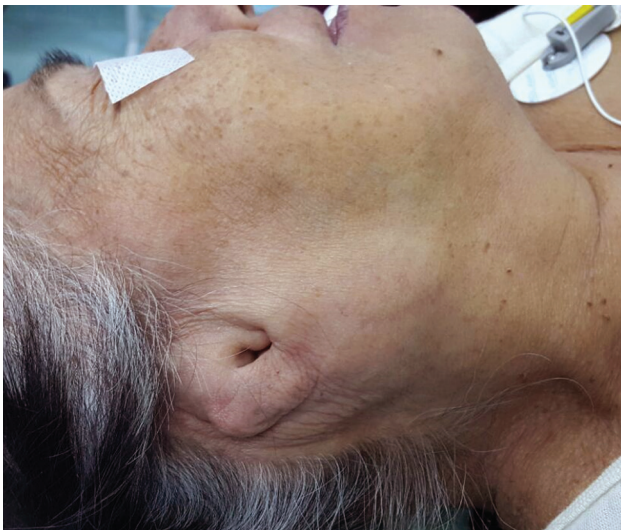

Figure 1. Preoperative appearance of right aural atresia and infraauricular mass.

findings supported pleomorphic adenoma, but the diagnosis was non-specific. Magnetic resonance imaging (MRI) revealed a right infraparotidal cystic lesion with multiple septations, hypointense on T₁-weighted images, hyperintense on T₂-weighted images, with contrast enhancement of the capsule. Computed tomography (CT) demonstrated limited temporal bone pneumatization and smaller total size on the atretic side compared with the contralateral healthy ear. The stylomastoid foramen on the atretic side was superiorly located, so the mastoid segment of the right fallopian canal was shorter than on the left side (Figure 2).

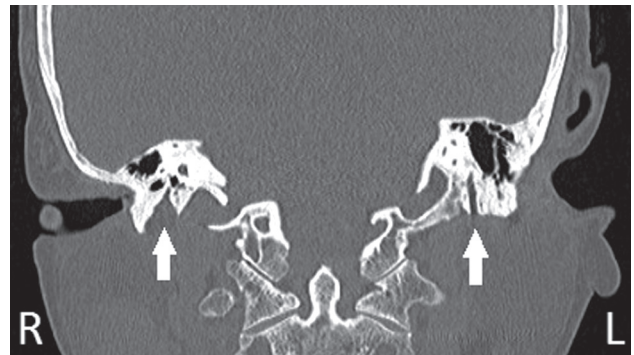

Figure 2. Smaller temporal bone and reduced pneumatization at the atretic side (right). The differences between the right and the left side in terms of mastoid segments of Fallopian canal, extratemporal facial nerve, and stylomastoid foramen.

Superficial parotidectomy under general anesthesia was performed. The facial trunk was identified according to anatomical landmarks with the aid of facial nerve monitoring, and the mass was carefully dissected from each facial branch (Figure 3a). We encountered a different facial nerve anatomy intraoperatively. As expected from preoperative CT imaging, the anomalous extratemporal segment of the facial nerve due to the superiorly located stylomastoid foramen continued as an anomalous facial trunk with a more vertical and longer course. The unique circumferential appearance was a facial nerve variation wherein the buccal, marginal mandibular and cervical branches emerged from this ring structure (Figure 3b, c).

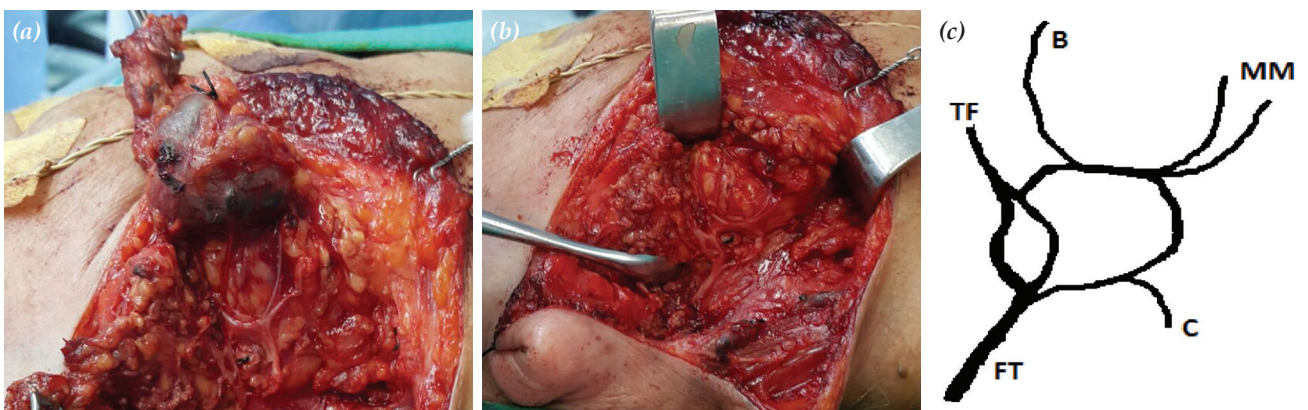


Figure 3. (a) Tumor dissection before excision with tumor-free margins. (b) Intraoperative finding of relatively longer and slightly vertical facial trunk. Note circumferential and unique ring structure of facial nerve branching. (c) Diagram showing facial nerve branches of the patient. FT: Facial trunk; C: Cervical; MM: Marginal mandibular; B: Buccal; TF: Temporofacial branches.

The marginal mandibular branch also had two branches emerging from this ring structure. All branches of facial nerve were preserved and the lesion was completely resected. One day after surgery, the patient was discharged without any complications. The final histopathological diagnosis was Warthin tumor. Written informed consent was also obtained from the patient who is presented in this paper.

DISCUSSION

Warthin tumor is a well encapsulated tumor and easily differentiates from adjacent tissues.^[10] Superficial parotidectomy with tumor-free margins is generally sufficient for treatment, but inadequate surgical resection leads to recurrence.^[11,12] Since the full extent of the facial nerve cannot be estimated before surgery, meticulous step-by-step dissection is important when separating the tumor from each branch of the facial nerve. The location and size of tumor determine the level of difficulty while handling the facial nerve.^[13] In case of additional anomalies such as aural atresia, facial nerve variation is possible as presented in this patient, and surgery becomes challenging for even the best surgeons.

When evaluating a patient with parotid mass, a temporal bone CT should be included in the radiological examination if patient has congenital aural atresia. Computed tomography is of particular significance in both anatomical and surgical evaluation of patients with congenital aural atresia as CT scanning assesses not only Fallopian canal variations of the facial nerve, but also shows ossicular and otic capsule abnormalities as well as temporal bone pneumatization.^[14] In this patient, CT revealed that the mastoid pneumatization was limited and total size of temporal bone was smaller on the atretic side compared with the contralateral healthy ear. Moreover, the right stylomastoid foramen on the atretic side was located more superiorly and the mastoid segment of the right Fallopian canal was shorter compared with the left side. This anatomical difference must have affected and changed the angle and length of the facial nerve trunk. As a result, a more vertical and longer facial trunk was identified intraoperatively. This was a predicted finding

based on preoperative imaging. However, when we followed the facial trunk delicately and dissected the tumor, we also recognized a different pattern of facial nerve branching within the parotid gland that was different from previously described facial nerve types.^[15-18] In this unique pattern, the cervicofacial branch emerged as two branches from the main trunk and these two branches created a circumferential structure. The buccal, marginal mandibular, and cervical branches emerged from this ring structure. All of these branches were confirmed by stimulation with facial nerve monitoring.

Postoperative permanent facial nerve paralysis is reported to occur in 0% to 3.9% of the initial parotid gland surgeries.^[13] The most anatomical variability of the facial nerve in the parotid region is related to differences in the anastomosis and origin of the buccal branch.^[15] Even without extra anomalies of the head and neck, tumors of the parotid gland may change facial nerve branch distribution, routes, length, thickness, and points where they attach to adjacent facial branches.^[15,19] These abnormalities particularly affect the buccal and/or marginal mandibular branches by making them more susceptible to injury during tumor resection.^[19] We believe that “unending and perpetual awareness” of the possible variations of anastomosis among facial nerve branches is the critical point to avoid facial nerve injury during parotidectomy.^[20] The commonly used surgical landmarks such as the tragal pointer, the digastric muscle, the retromandibular vein, the mastoid processes, and the tympanomastoid suture should be followed as in a routine parotidectomy, but always considering unexpected nerve patterns. Also, the use of facial nerve monitoring during parotidectomy has been shown to reduce the incidence of postoperative facial paralysis and the duration of surgery especially in cases with recurrence.^[13] Nerve monitoring can be utilized during dissection of each branch, but its use should not be an obsession for the surgeon. Although low in possibility, the technology may also mislead.

The coexistence of Warthin tumor and aural atresia on the same side is most probably a coincidence in this patient. Both an oncocytic epithelial component with papillary cystic

spaces and lymphoid stroma exist in the histologic structure of Warthin tumor. This combined structure of the tumor arises from salivary parenchyma inclusions trapped in the intraglandular and periglandular lymph nodes of the parotid gland.^[21] Therefore, it is another subject that needs to be investigated whether a different anatomy due to aural atresia triggers this histological development. To our knowledge, there is no study investigating the association between parotid tumor and ipsilateral aural atresia in terms of tumor development. In other words, no study regarding the incidence of parotid tumor in patients with aural atresia has been conducted yet. As a result, the coexistence of aural atresia and parotid tumor comprise a unique entity that has never been seen before, with the unusual extratemporal facial nerve findings.

In conclusion, otolaryngologists should keep in mind that despite the fact that it is a very rare coexistence, parotid tumor in congenital atresia cases is possible and can present with different facial nerve findings. In order to avoid morbidity and preserve the facial nerve during surgery, it is necessary for surgeons to be familiar with the different types of facial nerve anatomy. The surgery for any kind of parotid tumor related with abnormal facial nerve should be performed carefully by tiny step-by-step dissection with more patience and a great deal of attention.

Declaration of conflicting interests

The authors declared no conflicts of interest with respect to the authorship and/or publication of this article.

Funding

The authors received no financial support for the research and/or authorship of this article.

REFERENCES

1. Abdel-Aziz M. Congenital aural atresia. *J Craniofac Surg* 2013;24:418-22.
2. Dobratz EJ, Rastogi A, Jahrsdoerfer RA, Kesser BW. To POP or not: ossiculoplasty in congenital aural atresia surgery. *Laryngoscope* 2008;118:1452-7.
3. De la Cruz A, Linthicum FH Jr, Luxford WM. Congenital atresia of the external auditory canal. *Laryngoscope* 1985;95:421-7.
4. El-Hoshy Z, Abdel-Aziz M, Shabana M. Congenital aural atresia: transmastoid approach; an old technique with good results. *Int J Pediatr Otorhinolaryngol* 2008;72:1047-52.
5. Jahrsdoerfer RA. Congenital atresia of the ear. *Laryngoscope* 1978;88:1-48.
6. Kountakis SE, Helidonis E, Jahrsdoerfer RA. Microtia grade as an indicator of middle ear development in aural atresia. *Arch Otolaryngol Head Neck Surg* 1995;121:885-6.
7. Warthin A. Papillary cystadenoma lymphomatosum. *J Cancer Res* 1929;13:116-25.
8. Maiorano E, Lo Muzio L, Favia G, Piattelli A. Warthin's tumour: a study of 78 cases with emphasis on bilaterality, multifocality and association with other malignancies. *Oral Oncol* 2002;38:35-40.
9. Teymoortash A, Krasnewicz Y, Werner JA. Clinical features of cystadenolymphoma (Warthin's tumor) of the parotid gland: a retrospective comparative study of 96 cases. *Oral Oncol* 2006;42:569-73.
10. Yamada S, Matsuo T, Fujita S, Suyama K, Yamaguchi A, Mizuno A. Mucoepidermoid carcinoma arising in Warthin's tumor of the parotid gland. *Pathol Int* 2002;52:653-6.
11. Borumandi F, George KS, Cascarini L. Parotid surgery for benign tumours. *Oral Maxillofac Surg* 2012;16:285-90.
12. Witt RL, Nicolai P. Recurrent Benign Salivary Gland Neoplasms. *Adv Otorhinolaryngol* 2016;78:63-70.
13. Liu H, Wen W, Huang H, Liang Y, Tan X, Liu S, et al. Recurrent Pleomorphic Adenoma of the Parotid Gland: Intraoperative Facial Nerve Monitoring during Parotidectomy. *Otolaryngol Head Neck Surg* 2014;151:87-91.
14. Gassner EM, Mallouhi A, Jaschke WR. Preoperative evaluation of external auditory canal atresia on high-resolution CT. *AJR Am J Roentgenol* 2004;182:1305-12.
15. Gataa IS, Faris BJ. Patterns and surgical significance of facial nerve branching within the parotid gland in 43 cases. *Oral Maxillofac Surg* 2016;20:161-5.
16. Davis RA, Anson BJ, Budinger JM, Kurth LR. Surgical anatomy of the facial nerve and parotid gland based upon a study of 350 cervicofacial halves. *Surg Gynecol Obstet* 1956;102:385-412.
17. Kopuz S, Turgut S, Yavuz S, Ilgi S. Distribution of facial nerve in parotid gland: analysis of 50 cases. *Okajimas Folia Anat Jpn* 1994;70:295-9.
18. Smith OJ, Ross GL. A branching pattern of the facial nerve trunk with six initial branches: possible implications for parotid surgery? *J Plast Reconstr Aesthet Surg* 2013;66:288-9.
19. Kim YS, Suh YJ, Kim W, Chun CS. Branching pattern of the facial nerve in the parotid gland. *J Korean Surg Soc* 2002;62:453-5.
20. Zoulamoglou M, Zarokosta M, Kaklamanos I, Piperos T, Flessas I, Kakaviatos D, et al. Anatomic variation of the relation between the facial nerve and the retromandibular vein during superficial parotidectomy: A rare case report. *Int J Surg Case Rep* 2017;41:124-127.
21. Teymoortash A, Schrader C, Shimoda H, Kato S, Werner JA. Evidence of lymphangiogenesis in Warthin's tumor of the parotid gland. *Oral Oncol* 2007;43:614-8.