



Holmium:yttrium aluminum garnet laser lithotripsy for salivary calculi: A preliminary experience of 31 procedures

Necdet Özçelik¹, Gökhan Altın¹

Department of Otorhinolaryngology, Istanbul Medipol University Faculty of Medicine, Istanbul, Turkey

ABSTRACT

Objectives: This study aims to investigate the efficacy of holmium:yttrium aluminum garnet (Ho:YAG) laser as an intracorporeal lithotripter in the treatment of salivary calculi during sialendoscopy and to evaluate procedure-related complications.

Patients and Methods: Between April 2014 and April 2016, a total of 31 patients (22 males, 9 females; mean age 38 years; range, 8 to 57 years) who were treated with laser sialendoscopy were included. The patients were postoperatively followed on a weekly basis for four weeks and every month, thereafter. Procedural success was defined as the absence of symptoms after a three-month follow-up.

Results: Calculi were located in the parotid gland in eight of the patients and in the submandibular gland in 23 patients. The dimension of calculi varied between 2 to 12 mm. A 1.6 mm-Marchal all-in-one scope was used during sialendoscopy and the Sphinx 30, Lisa Laser was used as the laser device. In 27 of the patients, calculi were completely removed using laser sialendoscopy. In one of these cases, a second session was needed, since the patient definitely refused gland excision. In the second session, calculi were removed after breaking with laser lithotripsy. In four of these cases, calculi breaking process was unable to be completed with laser lithotripsy and open surgery was carried out. There was no canal perforation or nerve damage in any of the patients.

Conclusion: Based on our study results, Ho:YAG lasertriopsy is an effective and safe method in the treatment of salivary calculi. The use of Ho:YAG laser as an intracorporeal lithotripter increases the treatment success rate of salivary calculi with sialendoscopy.

Keywords: Holmium:YAG laser, lithotripsy, salivary calculi.

Recently, the use of lasermediated procedures for the treatment of salivary gland stones and ductal stenoses have increased with the development of sialendoscopy used in the ductal system of the gland. Subsequently, treatment of salivary gland stones has changed. Until that time, conventional treatment was, surgical excision of the salivary gland. However, with widespread use of sialendoscopy, removal of

calculi can be possible without the total excision of the gland.^[1-3]

Sialendoscopy is a minimally invasive procedure, and removal of small and mobile stones is usually performed through basket catheters and forceps.^[4] Removal of larger and immobile stones and those causing obstruction within the duct necessitates fragmentation of the stones. Starting with the idea of laser

Received: November 17, 2017 Accepted: May 22, 2018 Published online: May 02, 2019

Correspondence: Gökhan Altın, MD. İstanbul Medipol Üniversitesi Tıp Fakültesi Kulak Burun Boğaz Anabilim Dalı, 34214 Bağcılar, İstanbul, Turkey.
e-mail: drgokhanaltin@hotmail.com

Doi: <http://dx.doi.org/10.5606/Tr-ENT.2019.78871>

Citation:

Özçelik N, Altın G. Holmium: Holmium:yttrium aluminum garnet laser lithotripsy for salivary calculi: A preliminary experience of 31 procedures. Tr-ENT 2019;29(1):47-51.

fragmentation of urinary stones by urologists endoscopically, laser fragmentation of salivary stones was introduced.^[5,6] Endoscopic laser lithotripsy of the salivary gland was first applied in early 1990s and in many case series, different laser types were used.^[7-10] Holmium:yttrium aluminum garnet (Ho:YAG) laser has been widely used in intracorporeal lithotripsy in the urology practice and has been started to be used in the treatment of salivary gland recently.^[11]

In the present study, we aimed to investigate the efficacy of Ho:YAG laser as an intracorporeal lithotripter in the treatment of salivary calculi during sialendoscopy and to evaluate procedure-related complications.

PATIENTS AND METHODS

This study was conducted at Istanbul Medipol University Hospital, Department of Ear, Nose and Throat outpatient clinics between April 2014 and April 2016. A total of 31 patients (22 males, 9 females; mean age 38 years; range, 8 to 57 years) who were admitted with recurrent salivary gland swelling and diagnosed with salivary calculi using ultrasonography and thin-section computed tomography (CT) and treated with laser sialendoscopy were included in the study. A written informed consent was obtained from each patient. The study protocol was approved by the Istanbul Medipol University Ethics Committee. The study was conducted in accordance with the principles of the Declaration of Helsinki.

During sialendoscopy procedure, a 1.6 mm-Marchal all-in-one scope was used during sialendoscopy and the Sphinx 30, Lisa Laser (LISA Laser Products GmbH, Katlenburg, Lindau, Germany) was used as the laser device for sialendoscopic laser lithotripsy of salivary calculi which is also used for the lithotripsy treatment of urinary calculi in the urology department of the hospital where the study was conducted. This 4 to 20 Hz device has a maximum of 30W power outlet, shooting energy of 0.5 to 4.0 J, and shooting duration of 150 to 800 μ sec. The patients were postoperatively followed on a weekly basis for four weeks and every month, thereafter. Procedural success was defined as the absence of symptoms after a three-month follow-up.

All procedures were performed under general anesthesia. Following nasal intubation of the patient, punctum was dilated, until it enabled entrance of the endoscope into the duct, using Marchal dilators, as defined in conventional sialendoscopy. The endoscope was, then, advanced through the duct by irrigation. Following cleaning of the mucous secretions within the duct via irrigation, protected quartz optic fiber was passed through the intervention channel of the endoscope for the transmission of the laser light and was used by contacting the stone. During the breaking procedure, the device was commonly used at 0.6 to 1.5 J energy level and 5 to 15 Hz frequency interval.

Pieces of destroyed stones were removed from the channel using forceps, NGage[®] Nitinol stone extractors, and basket catheters. A stent was placed into the channel following the operation and was fixed to the oral mucosa for three to four weeks.

RESULTS

Calculi were located in the parotid gland in eight (20%) of the patients and in the submandibular gland in 23 patients (80%). The dimension of calculi varied between 2 to 12 mm. In 27 patients (one session n=26 and two sessions n=1), stones were broken completely into small fragments using Ho:YAG laser which were, then, removed from the duct using forceps (Figure 1). Calculi fragmentation was unable to be completed in four patients and gland excision was performed. In two of these patients, only a part of the stone which was able to be visualized in the submandibular gland, known as the "comma area", in which the channel is bend around the posterior border of the mylohyoid muscle, was unable to be broken completely. In the other two patients, stenosis was detected in the parotid gland. In these patients, stones were located in the right side at the back of the stenosis. Since the area of stenosis was unable to be passed, the right position to perform laser on the stones was unable to be achieved. In one of the patients, a second session was needed, since the patient definitely refused gland excision. In the second session, calculi, the remaining part of the 12-mm stone, were removed after breaking with laser lithotripsy. The diminished

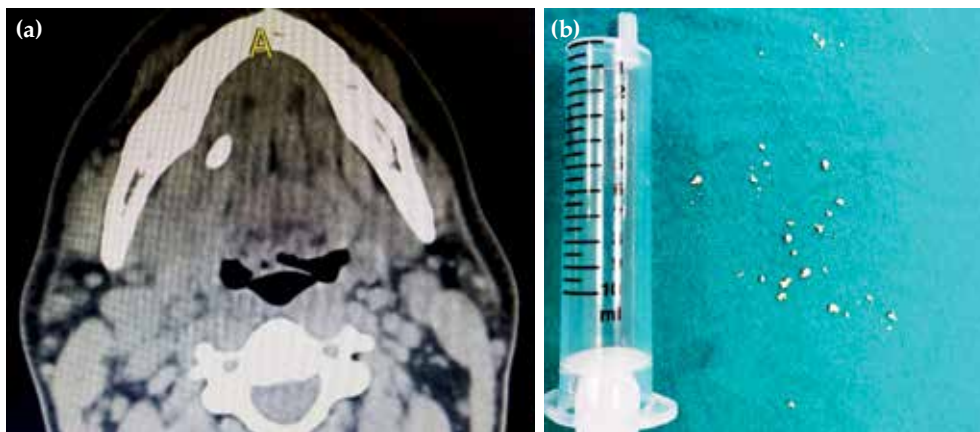


Figure 1. (a) Computed tomography view of the patient with stone in submandibular gland. (b) Stones fragmentation by holmium:yttrium aluminum garnet laser and taken out of the duct by baskets and NGage catheter.

stone was more visible in the duct six months later, and laser lithotripsy was completed.

There was no duct perforation or nerve damage in any of the patients. Intraoperative edema in the submandibular gland was observed in eight patients (30%), which resolved within 24 hours. During a three-month follow-up period, no complication was observed.

DISCUSSION

In the absence of proper devices or tools for lithotripsy, patient selection becomes obligatory for a sialendoscopy plan devoted to the stones within a salivary gland, considering the localization and size of the stones. Success rate decreases with the increased size and improper localization.^[12] Complete visibility of the stone is important in laser lithotripsy. In our study, we achieved procedural success in our patients in whom we were able to obtain complete visibility.

The main goal of laser lithotripsy is the fragmentation of the stones within the duct, until the pieces were small enough to be removed from the duct using basket catheters or forceps. Since the ducts of the salivary gland are narrow, particularly in the punctum, complete removal of the pieces is necessary. When anatomic visibility of the stones is poor due to its localization, where the stone is located in the proximal aspect or is large in size, or the patient does not give consent for complete removal of the gland, fragmentation can be performed in more than one session.

The definite success in lithotripsy is complete removal of the stones in one session, if possible. Confirmation of the absence of a residue is performed via a control endoscopy following laser lithotripsy. Durbec et al.^[6] reported their experience of Thulium fiber laser in removal of salivary gland stones and Blackmon et al.^[13] compared Thulium and Ho laser. Previous studies showed superior efficacy of Ho:YAG laser, although there is a very limited number of studies on this topic in the literature.

In an *in vitro* study of Chawla et al.^[14] on urinary system stone fragmentation, the validity of non-contact Ho:YAG laser stone fragmentation was demonstrated. In the presence of numerous pieces of stones, laser with irrigation was performed without directing it on a specific calculus, leading to an effect called “popcorn effect” which can further break calculi into smaller pieces and makes them proper for the removal from the duct. In the aforementioned study, the popcorn effect enabled visualization of small stones which remained invisible due to their localization by dislocating them. In our study, we also further diminished the size of the stones using this method. The sialendoscope should be removed from the duct with each piece of the stone grasped and, then, the channel is able to be re-entered. To eliminate repositioning of the sialendoscope, we used the popcorn effect and provided removal of the

stones that were diminished in size, until they became smaller than the diameter of the duct.

During laser lithotripsy, the duct is continuously irrigated using sterile physiological saline and dust-like pieces are removed from the sight of the endoscope. No specific fluid is needed for this purpose. Irrigation also eliminates the thermal effect caused by laser. When used in an aqueous environment, thermal absorption depth of the tissue is about 1 to 2 mm and the depth of photothermal damage in the tissue is 0.4 to 1 mm, which is ideal for all types of stone fragmentation.^[15] Stone fragmentation is often performed using 0.6 to 1.5 J energy and 5 to 15 Hz frequency. Low energy and high frequency selection during the procedure leads to a vaporization/dusting effect, whereas it vice versa leads to a fragmentation effect.^[14,16,17]

Luers et al.^[5] recommended the use of the laser 2-mm away from the stone directing the center and continuous irrigation to eliminate the thermal effect on the surrounding tissues. Similarly, in our study, we used Ho:YAG laser according to these principles and observed no ductal damage in any patients.

In another study, Durbec et al.^[6] used Thulium-YAG laser and directed laser to the center of the stone to prevent any damage to the duct and surrounding tissues. The authors completed the procedure in a second session where the stone was unable to be fragmented completely and needed much more laser energy. They experienced ductal perforation in eight patients (12.7%) and edema in the oral base in two patients (3.2%). The authors concluded that a good irrigation would prevent thermal damage of the laser to the surrounding tissues; however, it might lead to edema in the oral base which would recover in a short time period. In our study, we performed laser with continuous irrigation and except for eight patients with minimal oral base edema, no serious complication was encountered. Edema resolved within 24 hours without any complication. None of our patients had ductal perforation, either.

Causes of failure in sialendoscopy may be partial invisibility due to the angulation within the duct, moving of the fragmented stones into smaller ducts and unclear vision.^[6] Success was

not achieved by laser lithotripsy in four of our patients. Among them, only the visualized part of the stones could be fragmented in two of the patients, due to the limited vision in the area where the submandibular gland had a rotation around the mylohyoid muscle. In the remaining two, stenosis was detected in the parotid gland ducts, and the stones were located right after the stenosis. Since stenosis was unable to be passed, stone could not be fragmented. Similarly, Durbec et al.^[6] reported that laser-assisted calculi breakage could not be completed due to stenoses or folds within the duct in certain cases. In our study, stone could not be completely visualized through the sialendoscope in one patient; however, the patient did not give consent for the gland excision and, therefore, only the visualized part was broken and removed, while the remaining part was left for a second session. The diminished stone was observed to be more visible in the duct six months later and laser lithotripsy was completed.

Furthermore, Ho:YAG laser becomes ready shortly and it necessitates no specific irrigation fluid.^[16] Also, no eye-protective equipment is necessary since the procedure is endoscopic. The Ho:YAG laser can be used in every type of stones effectively. Since it is easy to direct, the stones can be broken into very small pieces and removed using equipment such as basket catheter. The main disadvantage of laser application is that it requires patience and the time to diminish the size of large stones.

In conclusion, laser lithotripsy is a proper method for fragmentation of salivary gland stones within the duct. Although other methods such as intracorporeal fragmentation may be used to break stones within the duct, laser is the most optimal procedure for the salivary gland duct. Based on our study results, Ho:YAG laser is an effective and safe method for fragmentation of the salivary gland. The use of Ho:YAG laser as an intracorporeal lithotripter increases the treatment success rate of salivary calculi with sialendoscopy.

Declaration of conflicting interests

The authors declared no conflicts of interest with respect to the authorship and/or publication of this article.

Funding

The authors received no financial support for the research and/or authorship of this article.

REFERENCES

1. Marchal F. Salivary gland endoscopy: new limits?. *Rev Stomatol Chir Maxillofac* 2005;106:244-9. [Abstract]
2. Lustmann J, Regev E, Melamed Y. Sialolithiasis. A survey on 245 patients and a review of the literature. *Int J Oral Maxillofac Surg* 1990;19:135-8.
3. Luers JC, Grosheva M, Stenner M, Beutner D. Sialoendoscopy: prognostic factors for endoscopic removal of salivary stones. *Arch Otolaryngol Head Neck Surg* 2011;137:325-9.
4. Faure F, Boem A, Taffin C, Badot F, Disant F, Marchal F. Diagnostic and interventional sialendoscopy. *Rev Stomatol Chir Maxillofac* 2005;106:250-2. [Abstract]
5. Luers JC, Petry-Schmelzer JN, Hein WG, Gostian AO, Hüttenbrink KB, Beutner D. Fragmentation of salivary stones with a 980nm diode laser. *Auris Nasus Larynx* 2014;41:76-80.
6. Durbec M, Dinkel E, Vigier S, Disant F, Marchal F, Faure F. Thulium-YAG laser sialendoscopy for parotid and submandibular sialolithiasis. *Lasers Surg Med* 2012;44:783-6.
7. Gundlach P, Scherer H, Hopf J, Leege N, Müller G, Hirst L, et al. Endoscopic-controlled laser lithotripsy of salivary calculi. In vitro studies and initial clinical use. *HNO* 1990;38:247-50. [Abstract]
8. Königsberger R, Feyh J, Goetz A, Schilling V, Kastenbauer E. Endoscopic controlled laser lithotripsy in the treatment of sialolithiasis. *Laryngorhinootologie* 1990;69:322-3. [Abstract]
9. Ito H, Baba S. Pulsed dye laser lithotripsy of submandibular gland salivary calculus. *J Laryngol Otol* 1996;110:942-6.
10. Arzoz E, Santiago A, Esnal F, Palomero R. Endoscopic intracorporeal lithotripsy for sialolithiasis. *J Oral Maxillofac Surg* 1996;54:847-50.
11. Marchal F, Becker M, Dulguerov P, Lehmann W. Interventional sialendoscopy. *Laryngoscope* 2000;110:318-20.
12. Marchal F, Chossegras C, Fare F, Delas B, Bizeau A, Mortensen B, et al. Salivary Stones and Stenosis. A Comprehensive Classification. *J Stoma* 2011;64:727-31.
13. Blackmon RL, Irby PB, Fried NM. Holmium:YAG (lambda= 2,120 nm) versus thulium fiber (lambda= 1,908 nm) laser lithotripsy. *Lasers Surg Med* 2010;42:232-6.
14. Chawla SN, Chang MF, Chang A, Lenoir J, Bagley DH. Effectiveness of high-frequency holmium:YAG laser stone fragmentation: the "popcorn effect". *J Endourol* 2008;22:645-50.
15. Reichel E, Paltauf G, Schmidt-Kloiber H, Groke K. A special irrigation liquid to increase the reliability of laser-induced shockwave lithotripsy. *Lasers Surg Med* 1992;12:204-9.
16. Kronenberg P, Traxer O. In vitro fragmentation efficiency of holmium: yttrium-aluminum-garnet (YAG) laser lithotripsy--a comprehensive study encompassing different frequencies, pulse energies, total power levels and laser fibre diameters. *BJU Int* 2014;114:261-7.
17. Spore SS, Teichman JM, Corbin NS, Champion PC, Williamson EA, Glickman RD. Holmium: YAG lithotripsy: optimal power settings. *J Endourol* 1999;13:559-66.