

# UPTAKE of $Tc^{99m}$ - MDP in a HEPATIC ANGIOSARCOMA

E.İbiş, M.D.\*\* / H.Özkaya, M.D.\*\* / A.T.Kemaloglu, M.D.\*\* / G.Erbay, M.D.\*

\* Professor, Department of Nuclear Medicine, Faculty of Medicine, Ankara University, Ankara, Turkey.

\*\* Specialist, Department of Nuclear Medicine, Faculty of Medicine, Ankara University, Ankara, Turkey.

## SUMMARY

The bone scan of a 55-year-old female with hepatic angiosarcoma had showed an abnormal area of increased uptake of  $Tc^{99m}$  MDP in the liver at the location of angiosarcoma.

**Key Words:** Hepatic angiosarcoma,  $Tc^{99m}$ -MDP accumulation.

## INTRODUCTION

Extraskeletal accumulation of bone-seeking radiopharmaceuticals in some benign and malignant neoplasms of the liver has previously been described (1-3). This is the first known report of a case in which hepatic angiosarcoma showed  $Tc^{99m}$ methylene diphosphonate ( $Tc^{99m}$ -MDP) uptake in a bone scan.

## CASE REPORT

A 55-year-old female is presented with a 5-week-history of weakness, nausea, vomiting, abdominal pain, and weight loss. Significant findings on physical examination included hepatomegaly and palpable mass at right hypocondrium. Significant laboratory findings included high levels of liver enzymes.

CT scan of the abdomen revealed a large heterogeneous, hypodence solid mass with irregular boundaries and calcified areas on the right lobe of the liver (fig.1). The mass occupied most of the liver.

On the ultrasonographic examination, a solid mass of 18 cm diameter on the right lobe of the liver was seen. The mass had irregular boundaries, heterogeneous echo structure, calcific and necrotic areas.

Liver scintigraphy with  $Tc^{99m}$  sulphur colloid showed a hypoactive area on the right lobe.

The bone scan obtained 4 hours after the intravenous injection of 20 mCi of  $Tc^{99m}$ -MDP, no evidence of bony abnormality, had showed an abnormal area of increased uptake at the right upper quadrant of abdomen (fig.2a-b).

Needle biopsy was taken and tumor proved to be angiosarcoma.

## DISCUSSION

Focal liver uptake of phosphate compounds by hepatoblastoma (4), cholangiocarcinoma (5), and metastases of malignant melanoma (6), esophageal (6), colon (7), breast (8), lung (9-12), bone (13), and ovarian (14, 15) carcinomas have been previously reported but no report have been found in the literature about  $Tc^{99m}$ -MDP accumulation in hepatic angiosarcoma.

The details of the uptake mechanism of extraskeletal accumulation of phosphonates are unknown. However some possible uptake mechanisms have been postulated. The precise point of accumulation of phosphonate in extraosseous tissues could be related to the increased calcium content of tissue (16). An alternative explanation is the possibility of high concentration of phosphatase enzyme systems in certain tumors (17). On the other hand, ion exchange between intracellular calcium phosphate and phosphate bone-scanning agents has been postulated as possible mechanisms of uptake (9).

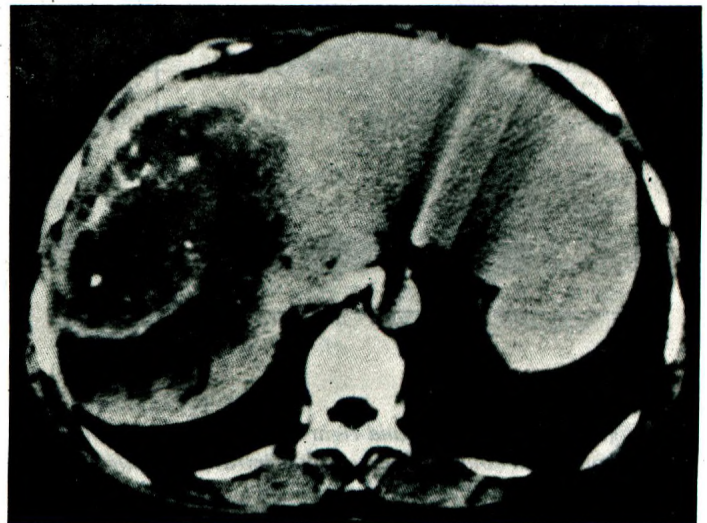


Figure 1: CT scan of the abdomen demonstrating a large heterogeneous, hypodence solid mass with irregular boundaries and calcified areas on the right lobe of the liver.

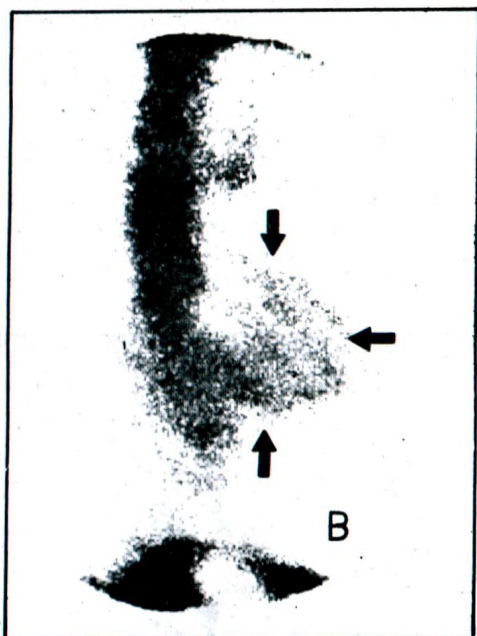
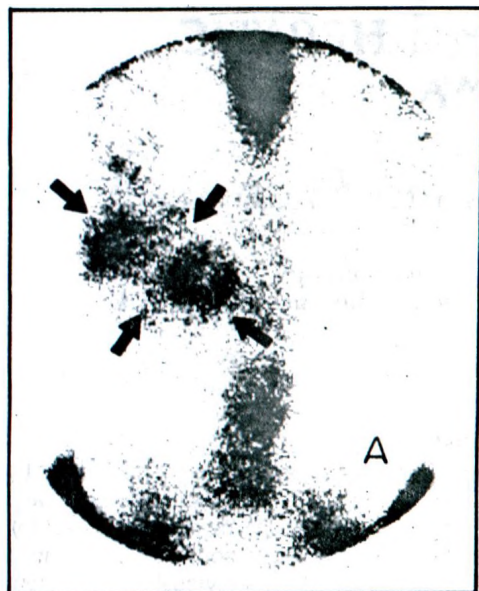


Figure 2: Anterior (A) and right lateral (B) bone scan of the abdomen obtained 4 hours later intravenous injection of 20 mCi of  $Tc^{99m}$ -MDP showing uptake in the liver (arrows), at the location of angiosarcoma involving a large portion of right lobe.

#### REFERENCES

1. Chaudhuri TK, Chaudhuri TK. Bone imaging tracer uptake in non-neoplastic osseous and non-osseous disease processes. *Semin Nucl Med* 1983; 13:78-81.
2. McAfee JG, Silberstein EB. Non-osseous uptake. In: Silberstein EB and McAfee JG eds. *Differential diagnosis in nuclear medicine*. New York: McGraw-Hill, 1984:300-318.
3. Naomi A. The musculoskeletal system. In: Harbert J and Rocha AFG eds. *Textbook of nuclear medicine*. Philadelphia: Lea and Febiger, 1984:157-216.
4. Elgazzar AH, Jahan S, Motawei S, Abdel-Dayem HM.  $Tc^{99m}$ -MDP uptake in hepatoblastoma. *Clin Nucl Med* 1989; 14:143-144.
5. Guibertean MJ, Potsaid MS, McKusick AK. Accumulation of  $Tc^{99m}$  diphosphate in four patients with hepatic neoplasm: Case report. *J Nucl Med* 1976;17:1060-1061.
6. Hansen S, Stadalnik RC. Liver uptake of  $Tc^{99m}$  pyrophosphate. *Semin Nucl Med* 1982;12:89-90.
7. Garcia AC, Yeh SDJ, Benua RS. Accumulation of bone seeking radionuclides in liver metastases from colon carcinoma. *Clin Nucl Med* 1977;2:265-269.
8. Baumert EJ, Lantieri RL, Harning S, et al. Liver metastases of breast carcinoma detected on  $Tc^{99m}$ -MDP bone scan. *AJR* 1980;134:389-391.
9. Lowenthal IS, Tow De, Chang YC. Accumulation of  $Tc^{99m}$  polyphosphate in two squamous cell carcinomas of the lung: Case report. *J Nucl Med* 1975;16:1021-1023.
10. Oren VO, Uszler JM. Liver metastases of oat cell carcinoma of lung detected on  $Tc^{99m}$  diphosphonate bone scan. *Clin Nucl Med* 1978;3:355-358.
11. Wilkinson RH, Gaede JT. Concentration of  $Tc^{99m}$ -MDP in hepatic metastases from squamous cell carcinoma. *J Nucl Med* 1979;20:303-305.
12. Marsh JJ, Belzberg ASB, Murphy KC. Uptake of  $Tc^{99m}$  diphosphonate by metastatic large cell carcinoma of the lung. *J Nucl Med* 1988;29:726-728.
13. Teates CD, Brower AC, Williamson RC. Osteosarcoma extraosseous metastases demonstrated on bone scans and radiographies. *Clin Nucl Med* 1977;2:298-300.
14. Growcock G, Lecklitner ML. Metastatic ovarian cystadenocarcinoma during bone scintigraphy. *Clin Nucl Med* 1983;8:274-277.
15. Kirsh JC, Steinhardt MI, Blackstein ME. Multi imaging demonstration of distant metastases from ovarian carcinoma. *Clin Nucl Med* 1984;9:533-555.
16. Silberstein E, Francis MD, Tofe AJ. Distribution of  $Tc^{99m}$ -Sn-diphosphonate and free  $Tc^{99m}$  pertechnetate in selected soft and hard tissues. *J Nucl Med* 1975;16:58-61.
17. Chaudhuri TK, Chaudhuri TK, Gulesserian HP, Christie JH, Tonami N. Extraosseous noncalcified soft tissue uptake of  $Tc^{99m}$  polyphosphate. *J Nucl Med* 1974;15:1054-1056.