

Askorbik Asit ve Sodyum Selenitin Renal İskemi-Reperfüzyon Hasarında İnflamatuvar Cevap ve Apoptoz Üzerine Etkileri

Effects of Ascorbic Acid and Sodium Selenite on Inflammatory Response and Apoptosis in Renal Ischemia-Reperfusion Injury

¹Songul DOGANAY, ²Ozcan BUDAK

¹Department of Physiology, Sakarya University Faculty of Medicine, Sakarya, Turkey

²Department of Histology and Embryology, Sakarya University Faculty of Medicine, Sakarya, Turkey

Songul Doganay: <https://orcid.org/0000-0002-1730-1331>

Ozcan Budak: <https://orcid.org/0000-0002-2617-3175>

ÖZ

Amaç: Bu çalışmanın amacı, renal iskemi ve reperfüzyon (IR) hasarında askorbik asit (AA) ve sodyum selenit (SS) uygulamasının anti-inflamatuvar ve anti-apoptotik etkilerini araştırmaktır.

Materyal ve Metot: Yirmi sekiz Wistar-albino sıçan dört gruba ayrıldı. Grup I; Kontrol grubu, Grup II; IR grubu, Grup III; IR+0,25mg/kg SS ve 100mg/kg AA ve Grup IV; IR+0,50mg/kg SS ve 200mg/kg AA. Kontrol grubuna sadece cerrahi stres oluşturuldu. IR grubunda, sağ nefrektomi yapıldıktan sonra sol böbrekte 60 dk iskemi ve 24 saat reperfüzyon sağlandı. Grup III ve Grup IV'e IR grubundaki işleme ek olarak IR işleminden 5 gün önce belirlenen dozlarda SS ve AA uygulandı.

Bulgular: Grup I, Grup III ve Grup IV ile karşılaştırıldığında Grup II'de glomerulus ve renal tübüllerin morfolojik yapılarında şiddetli hasar olduğu görüldü ($p<0,05$). Grup I, Grup III ve Grup IV ile karşılaştırıldığında Grup II'de TNF- α , IL-6, Kaspaz-3 ve Bcl-2 ekspresyonu ve pozitif hücre yüzdesi istatistiksel olarak arttı ($p<0,001$).

Sonuç: Bu çalışma, askorbik asit ve sodyum selenit'in profilaktik olarak uygulanmasının akut böbrek hasarına karşı koruyucu etkiler gösterdiğini belirledi.

Anahtar Kelimeler: Askorbik asit, inflamasyon, renal iskemi-reperfüzyon, sodyum selenit

ABSTRACT

Objective: The aim of this study is to investigate the anti-inflammatory and anti-apoptotic effects of ascorbic acid (AA) and sodium selenite (SS) administration in renal ischemia and reperfusion (IR) injury.

Materials and Methods: Twenty-eight Wistar-albino rats were divided into four groups. Group I; Control group, Group II; IR group, Group III; IR+0.25mg/kg SS and 100mg/kg AA and Group IV; IR+0.50mg/kg SS and 200mg/kg AA. In the control group, only surgical stress was created. In the IR group, 60 minutes of ischemia and 24 hours of reperfusion were applied in the left kidney after right nephrectomy. SS and AA were administered to Groups III and IV at doses determined 5 days before the IR procedure.

Results: In comparison of Group II with Group I, Group III and Group IV; severe damage was observed in the morphological structures of the glomerulus and renal tubules in Group II ($p<0.05$). Compared to Group I, Group III and Group IV the expression of TNF- α , IL-6, Caspase-3, and Bcl-2 and the percentage of positive cells increased statistically in Group II ($p<0.001$).

Conclusion: This study determined that prophylactic administration of ascorbic acid and sodium selenite showed protective effects against acute kidney injury.

Keywords: Ascorbic acid, inflammation, renal ischemia-reperfusion, sodium selenite

Sorumlu Yazar / Corresponding Author:

Songul Doganay
Department of Physiology, Sakarya University, Medical Faculty,
Sakarya – Turkey
Tel: +905309523295
E-mail: songuldoganay@sakarya.edu.tr

Yayın Bilgisi / Article Info:

Gönderi Tarihi/ Received: 11/01/2022
Kabul Tarihi/ Accepted: 21/01/2022
Online Yayın Tarihi/ Published: 01/03/2022

INTRODUCTION

Renal ischemia is the deprivation of oxygen of the kidney due to the reduction or interruption of blood flow to the tissue. Studies have shown that restoring blood flow after ischemia can increase tissue and cell damage in hypoxic organs and limit the return of function.¹ Researchers are making a great effort to identify the vascular changes caused by IR injury and to identify the mechanisms underlying this pathological process.^{1,2} Among the causes of damage to IR, primarily the increase of inflammatory cytokines (TNF- α and IL-6), free radicals and phagocytes are being showed.² IR damage aggravates tissue damage through the interaction of reactive oxygen metabolites, endothelium and neutrophils. By providing the tissue with oxygen support, the sudden excessive amount of oxygen entering the system causes the formation of free oxygen radicals.³ Post-ischemic tissues produce numerous inflammatory mediators such as tumor necrosis factor (TNF- α), interleukin-1 β (IL-1 β) interleukin-6 (IL-6) interleukin-10 (IL-10), which can activate or attract circulating neutrophils.⁴ TNF- α is thought to have a role in the systemic inflammatory response induced by IR. In experimental studies, administration of TNF- α appears to cause clinical symptoms of multiple organ dysfunction syndrome (MODS).⁵ Therefore, TNF- α is considered to be an inflammatory mediator that can directly initiate systemic inflammation and MODS. All the described mechanisms are interrelated and therefore it is quite difficult to provide a protective efficacy with individual mechanisms and mediators.⁶

Acute kidney injury (AKI), which is caused by the sudden decrease in kidney functions after IR, is a life-threatening clinical condition that causes the accumulation of waste materials in the blood.⁷ Deterioration in renal tubule structure, hemodynamic changes, increase in oxidant substances, increased oxidative stress due to inhibition of the antioxidant system, increased inflammation with the activation of proinflammatory cytokines and immune cells are responsible for the development of AKI due to kidney IR.^{3,8} Recent experimental studies have focused on the single or combined use of many anti-inflammatory and antioxidant agents to treat or prevent these factors.⁹ SS and AA are immune system regulators as well as antioxidant effects.^{9,10} The beneficial effects of using selenium and vitamin C separately or in combination with other vitamins have been shown to prevent IR damage in different organs such as the heart, lungs, intestines and kidneys.¹¹⁻¹³

In line with this information, we aimed to investigate the pro-inflammatory and anti-apoptotic effects of the combined use of sodium selenite and ascorbic

acid against AKI caused by renal IR.

MATERIALS AND METHODS

Ethical Status: Experiment protocols were carried out in accordance with international guidelines at Sakarya University Animal Laboratory (SUDATEM), after approval from Sakarya University Animal Care and Use Ethics Committee (Date: 04.11.2020, decision no: 61).

Animals: All rats were kept in wire cages under standard laboratory conditions with a 12-hour light/dark light cycle, a temperature of $22 \pm 2^\circ\text{C}$ and a humidity of 50-60%. Before the study, all rats were fed with standard pellet chow and tap water. For anesthesia, 30 mg/kg ketamine and 10 mg/kg xylazine were administered intraperitoneally (i.p.). Sodium selenite (SS) (Sigma Chemical East ellsworth rd. item no; N0636, USA) and ascorbic acid (AA) (Sigma Chemical 3050 Spruce Street. item no; 255564, USA) i.p. were given.

Experiment Protocol and Experimental Groups: In our study, 28 Wistar-albino male rats weighing approximately 280-300 g (12-14 weeks old) were used. The animals were randomly divided into 4 groups with 7 rats in each group. All surgical procedures were performed while the rats were under anesthesia. SS and AA doses were determined according to previous studies.¹⁴

Group I (Control, n=7): After the abdominal areas of the rats in this group were shaved and cleaned, both sides of the dorsal retroperitoneal regions were opened and closed without any procedure.

Group II (IR group, n=7): As in Group I, after right nephrectomy was performed on rats after surgical preparation; the left kidney artery, vein and ureter were clamped with a nontraumatic microvascular surgical clamp, preventing blood flow for 1 hour and ischemia was created, and then 24-hour reperfusion was achieved.

Group III (IR+0.25mg/kg SS and 100mg/kg AA, n=7): The low prophylactic dose of 0.25mg/kg SS and 100mg/kg AA is given i.p. for five days before performing the IR procedure. Then, the IR procedure was applied as in Group II.

Group IV (IR+ 0.50mg/kg SS and 200mg/kg AA, n=7): This group was i.p given a single high dose of 0.50mg/kg SS and 200mg/kg AA as a prophylactic for five days before applying the IR procedure. Then, the IR procedure was applied as in Group II. After the experimental period, the animals were sacrificed and the kidney tissues were taken into 10% formaldehyde for histological examinations.

Histopathological Examination: Tissue samples were kept in 10% buffered formalin solution for 2 days, then they were dehydrated, cleared and embedded in paraffin blocks. For histopathological exami-

nation, sections of 4 microns were taken from each block, stained with hematoxylin-eosin (H&E) and examined using a Light microscope (Olympus CX31 -Japan).

Kidney tissue sections were evaluated using the scale degree of kidney damage (tubular cell necrosis, cytoplasmic vacuolization, hemorrhage, and tubular dilatation), which was previously designed for semi-quantitative evaluation.¹⁵ Specifically, a single deep coronal section was examined under the microscope, depending on the extent of kidney involvement and the degree of damage. The scores were formed such as (0) is normal kidney; (1) is minimal damage (0-5% turnout); (2) is mild damage (5-25% involvement); (3) is moderate damage (25-75% involvement) and 4 is severe damage (75-100% involvement).¹⁵

Immunohistochemical Examination: Sections of 4 or 5 μm thickness from tissues embedded in paraffin blocks were taken on a slide with "Poly-L-Lysine" and after deparaffinization, immunohistochemical (IHC) staining was performed using the EnVision Flex detection kit (Agilent Technologies, California, USA) in accordance with the manufacturer's recommendations. Antigen unmasking was done by microwave incubation of the slides in a solution of citrate buffer (pH 6) for 40 min. Primary antibody diluted 1/300 (TNF- α : sc-52746, Santa Cruz-USA; IL-6:sc-32296, Santa Cruz-USA; Bcl-2: sc-7382, Santa Cruz-USA; Caspase -3:sc-56053, Santa Cruz-USA) was dripped and incubated overnight at +4°C in a humid environment. Diaminobenzidine (DAB) was used to make the dye visible. After staining with hematoxylin and eosin, the immunopositivity of the samples was evaluated by giving a semiquantitative H score. To evaluate the IHC staining results, both the inten-

sity of the image reaction (weak-1, intense-2) and the density of positive cells in percent (%0 - (0); 50-1% - (1); 51-75% - (2); 76-100% - (3)) scoring scale was used. The IHC image score calculation was calculated for each image by multiplying the image density reaction by the positive cell density.¹⁶

Statistical Analyzes: Statistical analyzes were performed using the SPSS 24.0 package program (SPSS Inc. and Lead Tech. Inc. Chicago. USA). Kolmogorov-Smirnov test was used to evaluate the normal distribution of the data. In the comparison of more than two variables, one-way ANOVA was used for data showing normal distribution, and Kruskal Wallis one-way analysis of variance test was used for data not showing normal distribution. In order to determine which group was different from the others, TUKEY HSD was used for homogeneous variances and Mann-Whitney U test was used for non-parametric tests. Results are given as mean \pm standard deviation (SD) and median-interquartile range (IQR). Statistical evaluation was considered significant if $P < 0.05$.

RESULTS

It was observed in the histopathological evaluations of the tissue samples that there were differences in the morphological structures of the glomerulus and renal tubules. Interstitial space, Bowman's capsule, structure of glomeruli, distal and proximal tubular epithelium were in regular morphological structure in Group I and Group IV groups. Severe damage was observed in the morphological structures of the glomerulus and renal tubules in Group II, which was the IR group that did not receive treatment, compared to the other groups (Figure 1).

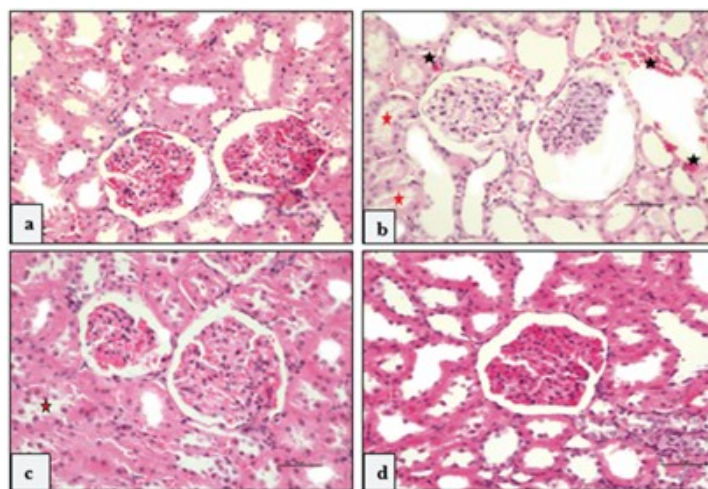


Figure 1. Microscopic images of kidney samples of control, untreated and treated IR groups after hematoxylin and eosin (H&E) staining. Kidney morphology was normal in Group I (a) and nearly normal in Group IV (d); Group II (b) showed high-intensity hemorrhage areas (black star), occasional tubular cell necrosis (red star) and cytoplasmic vacuolization. Group III (c) showed minimal cellular debris in rare areas, with no hemor-

The comparison of the histopathological scores of the experimental groups in terms of tubular necrosis, cytoplasmic vacuolization, hemorrhage and tubular dilatation of kidney damage is shown in Table 1. Statistically significant degeneration was observed in Group II, which is the IR group, compared to Group I, Group III, Group IV ($p < 0.001$). In comparisons made between Group I, Group III and Group IV, kidney morphology was preserved close to normal, especially in Group IV. There was no statistically significant difference between these groups ($p > 0.05$) (Table 1).

In the immunohistochemical examination of the kidney tissue, normal levels of TNF- α , IL-6, Caspase-3,

and Bcl-2 expression were observed in Group I. In Group II, TNF- α , IL-6, caspase-3, and Bcl-2 expressions were significantly higher than Group I, Group III, Group IV (Figure 2A-3A), and the percentage of positive cells increased statistically significantly. ($p = 0.000$ for all) (Figure 2B-3B). Comparing with Group II, the immunopositivity decreased in Group III and Group IV (especially Group IV), close to Group I, and this decrease was statistically significant ($p = 0.000$) (Figure 2B-3B). There was no statistical difference in the evaluations made between Group III and Group IV ($p > 0.05$).

Table 1. Comparison of histopathological scores of kidney injury between experimental groups.

Group (Each group n=7)	Tubular Necrosis Median (IQR)	Cytoplasmic Vacuolization Median (IQR)	Hemorrhage and Tubular Dilatation Median (IQR)
Group I	0 (1)	0 (0)	0 (0)
Group II	3 (1)	2 (1)	2 (1)
Group III	0 (1)	1 (1)	1 (1)
Group IV	0 (0)	0 (1)	0 (0)
P value (Kruskal Wallis)	0.000	0.001	0.000
P value (Mann-Whitney U)	0.001; I-II, III, IV	0.001; I-II 0.003; II-IV 0.007; II-III	0.001; I-II, III, IV

Values are presented as median (interquartile range); n: numbers.

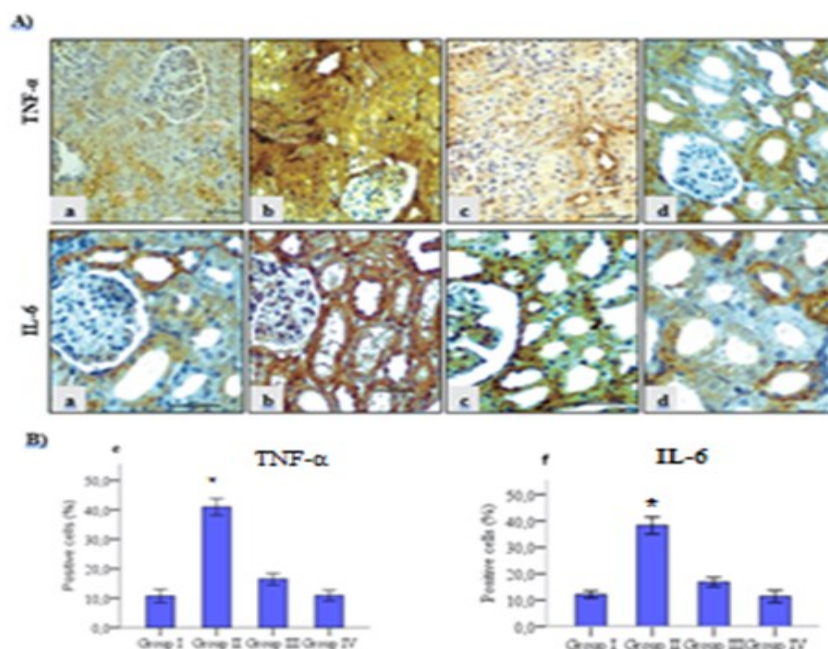


Figure 2. TNF- α and IL-6 positive staining percentage and expression were normal in the control and treatment groups (a, c, d); it is most intense in Group II (b). Extremely high TNF- α and IL-6 expression increased percentage of positive cells (e, f) in damaged areas in Group II. Decreased expression and percentage of positive cells in treated Group III and Group IV (e, f). * $p < 0.001$ when compared to Group I, Group III and Group IV. H&E, 200X.

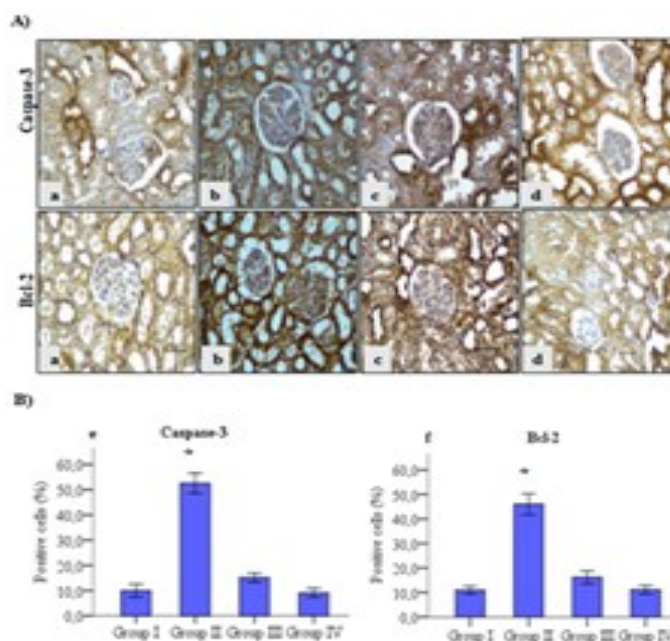


Figure 3. Caspase-3 and Bcl-2 positive staining percentage and expression were normal in the control and treatment groups (a, c, d); It is seen that it is most intense in Group II (b). Extremely high expression of Caspase-3 and Bcl-2 in damaged areas in Group II, increased percentage of positive cells (e, f). Decreased expression and percentage of positive cells in treated Group III and Group IV (e, f). * $p < 0.001$ when compared to Group I, Group III and Group IV. H&E, 200X.

DISCUSSION AND CONCLUSION

After the decrease or complete cessation of renal blood flow, acute renal failure (ARF) is triggered with various degrees of damage to the tissue with reperfusion.¹⁷ ARF is a life-threatening disease with a high mortality rate. Oxidative stress and inflammatory response play an important role in the progression of ARF. Products and phytochemical compounds with strong inhibitory effects on these mechanisms can be a useful treatment for ARF.¹⁸ Therefore, in this study, the anti-inflammatory and anti-apoptotic effects of using ascorbic acid and sodium selenite together in different doses against renal ischemia-reperfusion injury were investigated. Studies in the literature have shown an increase in cytoplasmic vacuolization, vascular hemorrhage, and tubular dilatation in tissues after IR.¹⁹ It was observed that the co-administration of high and low doses of ascorbic acid and sodium selenite to the treatment groups in order to alleviate the damage after IR, this damage was significantly reduced, especially in the high dose group. Positive effects of ascorbic acid and selenium administration on IR damage to reduce or treat renal IR damage have also been demonstrated in previous studies.^{20,21} As a result of a study in which different doses of AA were applied before and after ischemia to prevent hepatic ischemia-reperfusion injury. It even produces antioxidant activity, and that it has pre-oxidant effects in high-dose application.²² Hasanvand et al.,²³ and Ostrońska-Cieślak et al.²⁴ reported that the application of

selenium against kidney IR injury reduces kidney damage.

Kidney damage after IR causes the production of inflammatory mediators such as various cytokines and chemokines from tubular and endothelial cells. This results in the infiltration of inflammatory cells into the renal interstitium. Inflammatory cells in the kidney produce pro-inflammatory cytokines.²⁵ In ischemic ARF, the levels of proinflammatory cytokines/chemokines such as interferon gamma (IFN- γ), interleukin-2 (IL-2), interleukin (IL-10), tumor graft factor beta (TGF- β), IL-6, macrophage inflammatory protein 2 (MIP-2), and monocyte chemoattractant protein 1 (MCP-1) increase in the kidney.²⁶ In the current study, we observed that TNF- α , IL-6 expression and the percentage of positive cells increased in the IR group compared to the control and treatment groups as a result of the IHC evaluation. It has been shown that the application of high and low doses of ascorbic acid and sodium selenite reduces TNF- α and IL-6 expression and the percentage of positive cells; especially high-dose application gives results close to the control group.

Apoptosis is mainly initiated by the extrinsic pathway that is triggered extracellularly (presence of TNF- α or absence of growth factor) or the intrinsic pathway triggered from intracellular DNA damage, endoplasmic reticulum stress, or mitochondria. It eliminates abnormal or dead cells to maintain homeostasis. In IR injury, cells die from apoptosis in the first 24 hours of reperfusion.²⁷ Once the caspases

involved in apoptosis are activated, they induce a series of reactions that lead to the initiation of effector caspase cell death. Caspase-3 is an important marker in the initiation of apoptosis-inducing cascades. Oxidative stress and severe inflammation trigger the activation of caspase-3, which leads to cell apoptosis.²⁸ In our study, caspase-3 and Bcl-2 expression and the percentage of positive cells were increased in the IR group compared to the control and treatment groups. The expression and the percentage of positive cells decreased in high and low doses of AA and SS treatment groups, and especially high dose administration gave results close to the control group.

Many factors contribute to apoptosis. But key elements are categorized into two major protein families, including caspase enzymes and the Bcl-2 family. The Bcl-2 family is a set of cytoplasmic proteins that regulate apoptosis. The two main groups of this family, the Bcl-2 and Bax proteins, are functionally opposite: Bcl-2 and Bcl-xL inhibit apoptosis, while Bax counteracts this effect. Caspases, particularly caspase-3, are known to play a key role in the Bax/Bcl-2 ratio in driving apoptosis.²⁹ Recent evidence indicates that Bcl-2 is also a downstream death substrate of caspases and can thus inactivate the Bcl-2 anti-apoptotic function of caspase enzymes. Although there is a feedback loop between Bcl-2 and caspase, Bcl-2 cannot always prevent apoptosis.³⁰ The results of our study concluded that Bcl-2 expression increased with caspase-3 in the IR group. It has been shown that the application of AA and SS did not increase the expression of Bcl-2. These results suggest that AA and SS can not trigger the anti-apoptotic effect of Bcl-2.

In conclusion, prophylactic administration of AA and SS significantly improved kidney morphology in renal IR injury and promoted cell survival by targeting inflammatory cytokines and apoptosis.

Ethics Committee Approval: The study was approved by the Sakarya University Animal Experiments Local Ethics Committee (Date: 04.11.2020, decision no: 61).

Conflict of Interest: No conflict of interest was declared by the authors.

Author Contributions: Concept – SD; Supervision – SD, OB; Materials – SD, OB; Data Collection and Processing – SD, OB; Analysis and Interpretation – SD, OB; Writing – SD.

Peer-review: Externally peer-reviewed.

REFERENCES

- Cheng Z, Guo C. Pemaifibrate pretreatment attenuates apoptosis and autophagy during hepatic ischemia-reperfusion injury by modulating jak2/stat3β/pparα pathway. *PPAR Research*. 2021;2021:1-15. doi:10.1155/2021/6632137
- Yamaguchi M, Okamoto K, Kusano T, et al. The effects of xanthine oxidoreductase inhibitors on oxidative stress markers following global brain ischemia reperfusion injury in C57BL/6 mice. *PLoS One*. 2015;10(7):e0133980. doi:10.1371/journal.pone.0133980
- Basile DP, Yoder MC. Renal endothelial dysfunction in acute kidney ischemia reperfusion injury. *Cardiovascular & Haematological Disorders-Drug Targets*. 2014; 14(1):3-14.
- Bhogal RH, Sutaria R, Afford SC. Hepatic liver ischemia/reperfusion injury: processes in inflammatory networks-a review. *Liver Transpl*. 2011;17:95. doi:10.1002/lt.22205
- Ma M, Ma ZH. Effect of tumor necrosis factor-alpha in rats with hepatic ischemia-reperfusion injury. *Hepatobiliary&Pancreatic Diseases International*. 2008;7:296-299.
- Dai J, Chen Q, Huang W, et al. Liver kinase B1 attenuates liver ischemia/reperfusion injury via inhibiting the NLRP3 inflammasome. *Acta Biochimica et Biophysica Sinica*. 2021;53:601-611.
- Kezić A, Stajic N, Thaiss F. Innate immune response in kidney ischemia/reperfusion injury: potential target for therapy. *Journal of immunology research*. 2017;2017:1-10. doi:10.1155/2017/6305439
- Pefanis A, Ierino FL, Murphy JM, Cowan PJ. Regulated necrosis in kidney ischemia-reperfusion injury. *Kidney international*. 2019;96:291-301. doi:10.1016/j.kint.2019.02.009
- Ahmadiasl N, Banaei S, Alihemmati A. Combination antioxidant effect of erythropoietin and melatonin on renal ischemia-reperfusion injury in rats. *Iranian journal of basic medical sciences*. 2013;16(12):1209-1216.
- Asgharpour M, Tolouian AC, Bhaskar LV, Tolouian R, Massoudi N. Herbal antioxidants and renal ischemic-reperfusion injury; an updated review. *Journal of Nephro pharmacology*. 2020;10(1):e03. doi:10.34172/npj.2021.03
- Erkut B, Özyazicioğlu A, Karapolat BS, et al. Effects of ascorbic acid, alpha-tocopherol and allopurinol on ischemia-reperfusion injury in rabbit skeletal muscle: an experimental study. *Drug Target Insights*. 2007;2:DTI-S303. doi:10.4137/DTI.S303
- Sandhi J, Singh JP, Kaur T, Ghuman SS, Singh AP. Involvement of progesterone receptors in ascorbic acid-mediated protection against ischemia-reperfusion-induced acute kidney injury. *Journal of Surgical Research*. 2014;187:278-288. doi:10.1016/j.jss.2013.10.025
- Ahmadvand H, Babaenezhad E, Nayeri H, Nezhad ZZ. Selenium effects on antioxidant and

- inflammatory indices in renal ischemia-reperfusion injury in rats. *Journal of Renal Injury Prevention*. 2019;8(2):71-77. doi:10.15171/jrip.2019.14
14. Leskovec J, Levart A, Nemeč Svete A, et al. Effects of supplementation with α -tocopherol, ascorbic acid, selenium, or their combination in linseed oil-enriched diets on the oxidative status in broilers. *Poultry Science*. 2018;97:1641-1650.
 15. Irmak MK, Koltuksuz U, Kutlu NO, et al. The effect of caffeic acid phenethyl ester on ischemia-reperfusion injury in comparison with α -tocopherol in rat kidneys. *Urological Research*. 2001;29:190-193. doi:10.1007/s002400100185
 16. Zeng J, Tang ZH, Liu S, Guo SS. Clinicopathological significance of overexpression of interleukin-6 in colorectal cancer. *World Journal of Gastroenterology*. 2017;23(10):1780-1786. doi:10.3748/wjg.v23.i10.1780
 17. Pektaş A, Gemalmaz H, Balkaya M, et al. Renal iskemi/reperfüzyon hasarı oluşturulan ratlarda likopenin kısa dönemdeki koruyucu etkisi. *Turkish Journal of Urology*. 2014;40(1):46-51. doi:10.5152/tud.2014.53765
 18. Boozari M, Hosseinzadeh H. Natural medicines for acute renal failure: A review. *Phytotherapy Research*. 2017;31(12):1824-1835. doi:10.1002/ptr.5943
 19. Golab F, Kadkhodae M, Zahmatkesh M, et al. Ischemic and non-ischemic acute kidney injury cause hepatic damage. *Kidney International*. 2009;75(8):783-792. doi:10.1038/ki.2008.683
 20. Liu L, Liu C, Hou L, et al. Protection against ischemia/reperfusion-induced renal injury by co-treatment with erythropoietin and sodium selenite. *Molecular Medicine Reports*. 2015;12(6):7933-7940. doi:10.3892/mmr.2015.4426
 21. Park SW, Ghim W, Oh S, et al. Association of vitreous vitamin C depletion with diabetic macular ischemia in proliferative diabetic retinopathy. *PLoS One*. 2019;14(6): e0218433. doi:10.1371/journal.pone.0218433
 22. Seo MY, Lee SM. Protective effect of low dose of ascorbic acid on hepatobiliary function in hepatic ischemia/reperfusion in rats. *Journal of Hepatology*. 2002;36(1):72-77. doi:10.1016/S0168-8278(01)00236-7
 23. Hasanvand A, Abbaszadeh A, Darabi S, Nazari A, Gholami M, Kharazmkia A. Evaluation of selenium on kidney function following ischemic injury in rats; protective effects and antioxidant activity. *Journal of Renal Injury Prevention*. 2017;6(2):93-98. doi:10.15171/jrip.2017.18
 24. Ostróžka-Cieślík A, Dolińska B, Ryszka F. Therapeutic potential of selenium as a component of preservation solutions for kidney transplantation. *Molecules*. 2020;25(16):3592. doi:10.3390/molecules25163592
 25. Aboutaleb N, Jamali H, Abolhasani M, Toroudi H. Lavender oil (*Lavandula angustifolia*) attenuates renal ischemia/reperfusion injury in rats through suppression of inflammation, oxidative stress and apoptosis. *Biomedicine & Pharmacotherapy*. 2019;110:9-19. doi:10.1016/j.biopha.2018.11.045
 26. Yaribeygi H, Farrokhi FR, Rezaee R, Sahebkar A. Oxidative stress induces renal failure: A review of possible molecular pathways. *Journal of Cellular Biochemistry*. 2018;119(4):2990-2998. doi:10.1002/jcb.26450
 27. Kunak CS, Ugan RA, Cadirci E, et al. Nephroprotective potential of carnitine against glycerol and contrast-induced kidney injury in rats through modulation of oxidative stress, proinflammatory cytokines, and apoptosis. *The British Journal of Radiology*. 2016;89:105820140724. doi:10.1259/bjr.20140724
 28. Lakhani SA, Masud A, Kuida K, et al. Caspases 3 and 7: key mediators of mitochondrial events of apoptosis. *Science*. 2006;311(5762):847-851. doi:10.1126/science.1115035
 29. Jafari Anarkooli I, Sankian M, Ahmadpour S, Varasteh AR, Haghiri H. Evaluation of Bcl-2 family gene expression and Caspase-3 activity in hippocampus STZ-induced diabetic rats. *Experimental Diabetes Research*. 2008;2008:1-6. doi:10.1155/2008/638467
 30. Yang B, Johnson TS, Thomas GL, et al. A shift in the Bax/Bcl-2 balance may activate caspase-3 and modulate apoptosis in experimental glomerulonephritis. *Kidney International*. 2002;62(4):1301-1313. doi:10.1111/j.1523-1755.2002.kid587.x