

Comparison of N-Acetyl Cysteine and Resveratrol Treatments in Acetaminophen Toxicity Model in Rabbits

Tavşanlarda Yapılan Asetaminofen Toksikoloji Modelinde N-Asetilsistein ve Resveratrol Tedavilerinin Karşılaştırılması

Hasan Gazi UYAR¹  Ayşegül BAYIR²  Hasan KARA²  Pınar KARABAĞLI³ 

Abdullah SİVRİKAYA⁴  Ali ÜNLÜ⁴ 

ÖZ

Amaç: Asetaminofen güvenli bir analjezik ilaçtır fakat yüksek dozlarda akut karaciğer hasarına neden olmaktadır. Asetaminofen intoksikasyonunda tedavisinde N-asetil sistein (NAC) kullanılmaktadır. Resveratrolun (RES), asetaminofen intoksikasyonu modellerinde kullanılabileceği gösterilmiştir. Çalışmamızda amaç, asetaminofen intoksikasyonunda NAC ile resveratrol tedavilerinin etkinliğinin karşılaştırmaktır.

Araçlar ve Yöntem: Çalışmamızda 6'sı kontrol grubunda olmak üzere, 28' i 4 farklı çalışma grubunda olmak üzere toplam 34 tavşan kullanıldı. Asetaminofen (APAP) (n=7) grubunda hayvanlara 2 gr/kg asetaminofen orogastrik tüp aracılığıyla verildi. Asetaminofen+N-asetilsistein (APAP+NAC) (N=7) grubunda hayvanlara 2 gr/kg asetaminofen orogastrik tüp aracılığıyla verildi ve takibinin 1. saatinde 150 mg/kg NAC intramüsküler (i.m) uygulandı. Asetaminofen+resveratrol (APAP+RES) (N=7) grubunda hayvanlara 2 gr/kg asetaminofen orogastrik tüp aracılığıyla verildi ve takibinin 1. saatinde orogastrik tüple 100 mg/kg resveratrol verildi. Asetaminofen+Nasetilsistein+Resveratrol (APAP+NAC+RES) (N=7) grubunda ise hayvanlara 2 gr/kg asetaminofen orogastrik tüp aracılığıyla verildi ve takibinin 1. saatinde orogastrik tüple 100 mg/kg resveratrol verildi ve 150 mg/kg NAC i.m uygulandı. ALT, AST, total GSH ve kan asetaminofen düzeyleri çalışıldı. Hayvanlar 24. saatte sakrifiye edildi. Karaciğer dokusu histopatolojik inceleme için kullanıldı.

Bulgular: Sonuçlarımızda 12 saat GSH düzeyi APAP+NAC grubunda APAP+RES grubuna göre istatistiksel olarak anlamlı bulundu (p=0.007). Histopatolojik çalışmada, apoptozis için kullandığımız HSCORE düzeyi kontrol grubunda APAP grubuna göre istatistiksel olarak daha düşük tespit edildi (p=0.007). Bu sonuç asetaminofen toksisitesini karaciğer hücrelerinde apoptozisi tetiklediğini gösteriyor.

Sonuç: Resveratrol asetaminofen toksisitesi tedavisinde NAC'a alternatif bir tedavi seçeneği olabilir.

Anahtar Kelimeler: asetaminofen; NAC; parasetamol; resveratrol; toksisite

ABSTRACT

Purpose: Acetaminophen is safe analgesic drug but it may cause hepatic failure in high doses. N-acetyl cysteine (NAC) is used in the treatment of acetaminophen intoxication. Resveratrol may be used in experimental acetaminophen intoxication models. Purpose, compare the efficacy of NAC and resveratrol treatments in acetaminophen intoxication.

Materials and Methods: We used 34 rabbits. Six rabbits were included in control group, and 7 rabbits were enrolled in other groups Asetaminofen (APAP) (N=7) group. The animals were administered 2 g/kg of acetaminophen by an orogastric tube. Asetaminofen+N-acetylcysteine (APAP+NAC) (N=7) group, 150 mg/kg NAC was administered intramuscular (i.m) to animals at 1st hour following 2 g/kg of acetaminophen administration by orogastric tube. Asetaminofen+resveratrol (APAP+RES) (N=7) group, animals received 100 mg/kg resveratrol by orogastric tube at 1st hour following oral administration of 2 g/kg of acetaminophen by orogastric tube. e. Asetaminofen+N-acetyl cysteine+resveratrol (APAP+NAC + RES) (N=7) group, animals received 100 mg/kg resveratrol by orogastric tube and 150 mg/kg NAC i.m at 1st hour following oral administration of 2 g/kg of acetaminophen by orogastric tube. ALT, AST, GSH, and acetaminophen levels were measured. Animals were sacrificed at the 24th hour. Liver samples were obtained for histopathological examination.

Results: According to our results, the GSH level at 12th hour was significantly different between APAP+NAC group and APAP+RES group (p=0.007). In histopathological examination, HSCORE level we used for apoptosis was statistically significantly lower in control group than in APAP group (p=0.007). Its supports that acetaminophen toxicity triggers apoptosis in liver cells.

Conclusion: Resveratrol may be an alternative treatment option to NAC in the treatment of acetaminophen toxicity.

Keywords: acetaminophen; NAC; paracetamol; resveratrol; toxicity

Received: 24.01.2022; Accepted: 30.04.2022

¹Emergency Medicine Service, Meram State Hospital, Konya, Türkiye.

²Department of Emergency Medicine, University of Selçuk, Faculty of Medicine, Konya, Türkiye.

³Department of Medical Pathology, University of Selçuk, Faculty of Medicine, Konya, Türkiye.

⁴Department of Medical Biochemistry, University of Selçuk, Faculty of Medicine, Konya, Türkiye.

Corresponding Author: Hasan Gazi Uyar, Emergency Medicine Service, Meram State Hospital, Konya, Türkiye. e-mail: dr.hasangaziuyar@gmail.com

How to cite: Uyar HG, Bayır A, Kara H, Karabağlı P, Sivrikaya A, Ünlü A. Comparison of n-acetylene cysteine and resveratrol treatments in acetaminophen toxicity model in rabbits. Ahi Evran Med J. 2022;6(3):282-289. DOI: 10.46332/aemj.1060025

INTRODUCTION

Acetaminophen (N-acetyl-p-aminophenol or paracetamol) is a commonly used analgesic and antipyretic drug worldwide.¹ In all age groups, suicidal attempts with acetaminophen (APAP) are frequently encountered due to it being frequently prescribed and easy availability. APAP toxicity is the most common cause of acute liver failure in the United States. There are many studies suggesting that APAP causes hepatic failure by damaging the liver tissue.²

NAC is used in patients with APAP toxicity, and it has some serious side effects. These side effects include acute allergic reactions such as anaphylaxis, anaphylactic shock, angioedema, and urticaria. Moreover, relatively frequent side effects, such as nausea and vomiting, are also observed. These side effects suggest that new antidotes should be developed for APAP toxicity. One of these new antidotes is resveratrol.

Resveratrol (3,4,5-trihydroxystilbene) is a natural antioxidant in the polyphenol structure found in abundance in fruits, such as grapes, peanuts, strawberries, and cherries.³ It is a strong antioxidant and prevents oxidative damage by binding to reactive free oxygen radicals and chelating metal.⁴ Resveratrol increases the level of glutathione through the glutamate-cysteine ligase enzyme and neutralizes the free oxygen radicals.⁵ Resveratrol has been shown to increase hepatic glutathione, induce phase-2 hepatic enzymes and remove free radicals. It has been demonstrated that resveratrol inhibits the nuclear factor kappa β (NF- κ), which is the transcription factor in the inflammatory cascade,⁶⁻¹⁰ and also decreases the NF- κ core translocation and affects transcription.¹¹ Resveratrol has also been shown to have a hepatoprotective effect against many hepatotoxic agents such as ethanol and carbontetrachloride together with APAP.¹²

To the best of our knowledge, there is no experimental study in the literature comparing NAC and resveratrol treatments in terms of protective and therapeutic aspects in APAP-induced hepatotoxicity. In this study, we aimed to compare the efficacy of NAC and resveratrol therapies with biochemical parameters and tissue histopathological examination in an experimental APAP toxicity model in rabbits.

MATERIALS and METHODS

Approval was obtained from the Experimental Animals Ethics Committee of Selcuk University Experimental Medicine Application and Research Center (Approval date, no: 14.07.2015-2015/77). All procedures were carried out in accordance with the provisions in the Helsinki Declaration on the care and use of laboratory animals.

Experimental Method

In our study, we used a total of 34 New Zealand rabbits. The rabbits were divided into 5 groups. Six of these rabbits were included in the control group, and 7 rabbits were enrolled in each of the other groups. The rabbits in the control group did not receive any medication or treatment. At the beginning of the experiment, venous blood samples were drawn from the dorsal ear artery of all subjects to measure the serum ALT, AST and total GSH levels.

The rabbits in the sham group were given 2 g/kg of acetaminophen via an orogastric tube. The rabbits in the APAP+NAC group received 150 mg/kg NAC i.m. 1 hour after administration of 2 g/kg of acetaminophen orally via an orogastric tube. The rabbits in the APAP+resveratrol group received 100 mg/kg resveratrol orally via an orogastric tube 1 hour after administration of 2 g/kg acetaminophen via the orogastric tube. The rabbits in the APAP+NAC+resveratrol group received 100 mg/kg resveratrol orally via an orogastric tube and 150 mg/kg NAC i.m. 1 hour after administration of 2 g/kg of acetaminophen orally via an orogastric tube. Venous blood samples were obtained to measure the serum ALT, AST, total GSH and APAP levels at the 1st hour, 12th hour and 24th hour from all subjects except those in the control group. The subjects were sacrificed 24 hours after the experiment under anesthesia by decapitation. Tissue samples were obtained from the caudate lobe of the liver of all subjects to detect apoptosis histopathologically.

Biochemical Method

Arterial blood samples were obtained from all rabbits into tubes with EDTA and gel tubes. Samples obtained into EDTA tubes were centrifuged at 3000 rpm for 5 minutes.

After the separation of the plasma, the remaining erythrocyte package was added to the physiological serum (0.9% NaCl) approximately five times the blood volume and centrifuged at 1500 rpm for 5 minutes. After centrifugation, the supernatant was poured away, and the same amount of saline was added again, and this process was repeated twice. The total GSH level in the washed erythrocytes was analyzed with the Shimadzu brand prominence model HPLC System (Japan) using Immuchrom (Lot no: IC1800-150828) HPLC assay kits.

The arterial blood samples obtained into plain tubes were centrifuged at 3000 rpm for 10 minutes after clotting and the serum samples were separated. The AST, ALT and APAP levels in these serum samples were measured. The serum AST and ALT levels were analyzed in the architect-C 16000 auto-analyzer using the Abbott test kits (lot no. 47489UN15 and 47820UQ06, respectively).

The serum APAP levels were analyzed by a method developed in the LC-MS/MS device in the Biochemistry Laboratory of Selcuk University Medical Faculty. For the APAP sample preparation, 200 µl of acetonitrile was added to 100 µl of plasma and vortexed for 30 sec. It was then centrifuged at 13000 rpm for 5 minutes. 10 µL of LC-MS/MS was injected from the resulting supernatant.

Mass spectrometry analysis was performed with an electrospray ion source (ESI) in positive mode and ABSCIEX API 3200 triple quadrupole mass spectrometer (USA) Shimadzu LC-20-AD (Kyoto, Japan). Calculation of the data was carried out with the ABSCIEX Analyst Software Wizard version 1.6.1. The Phenomenex brand Luna C18 (3µm, 4.6×50mm) was used as the analytical column. The mobile phase was made using a 50% acetonitrile / water (v/v) isocratic pump. The analysis time was set to 2 minutes.

Pathological Examination

The liver tissues of 34 rabbits sacrificed were transferred to the Pathology Department at Selcuk University Faculty of Medicine in 10% formalin solution. Paraffin-embedded tissue blocks prepared from samples obtained from the tissues were cut to 4 microns thick sections using the Leica brand RM2255 model microtome device in the laboratory and then taken onto Poly-L-Lysin-coated positive loaded

slides. The sections were stained with anti-Caspase-3 antibody (polyclonal rabbit Abcam USA ab4051) in a semi-automatic Ventana Benchmark XT immunohistochemistry staining device after 60 min deparaffinization in a 60°C oven.

The staining procedure was performed with a 60 min incubation period, 1/350 concentration, and 36 minutes pre-treatment with citrate. The stained preparations were evaluated by a researcher and a pathologist under a light microscope. Each preparation was examined in at least 5 big magnification areas (x400), and the presence and intensity of intra-nuclear and/or intra-cytoplasmic expression were assessed. The histological scoring (HSCORE) method was used in the pathological evaluation of the experimental groups. The HSCORE is the value obtained by multiplying the total density of the positively stained hepatocytes by the staining intensity.

$$\text{HSCORE} = \sum \text{Pi} (I+1)$$

I, staining intensity (0=no staining, 1=mild, 2=moderate, and 3=intense staining)

Pi, the percentage rate of staining for each density.(76)

Statistical Analysis

The data were recorded in pre-prepared forms. Statistical analyses were performed using the SPSS for Windows 18 program. Comparison between the groups was made through analysis of variance (ANOVA) in repeated measurements. The Bonferroni-corrected one-way analysis of variance and a pairwise comparison with the Tukey HSD test were used as Post Hoc tests. A p-value of lower than 0.05 was considered statistically significant.

RESULTS

The mean weight of all subjects in the groups was 2044 g, and there was no statistically significant difference between the groups (p=0.422).

When the baseline GSH levels of the groups were examined, the highest GSH level was determined as 38543 µmol/L in the APAP+Resveratrol group and the lowest was 9085 µmol/L in the control group. The mean baseline

GSH level of all groups was 23138 $\mu\text{mol/L}$. There was a statistically significant difference in the baseline GSH levels between the groups ($p=0.027$). The 12th-hour GSH level was the highest in the APAP+Resveratrol group with 4872 $\mu\text{mol/L}$, and the lowest GSH level was 2308 $\mu\text{mol/L}$ in the APAP+NAC group. There was a statistically significant difference between the groups in terms of the mean GSH level at the 12th hour ($p=0.010$).

There was no statistically significant difference between the groups in terms of the mean GSH level at the 1st hour and the 24th hour ($p>0.05$, for both). The mean GSH level at the 24th hour was the highest in the APAP+NAC+Resveratrol group with 5617.1429 $\mu\text{mol/L}$ and the lowest mean GSH level was determined in the APAP group with 3815.1667 $\mu\text{mol/L}$ (Figure 1).

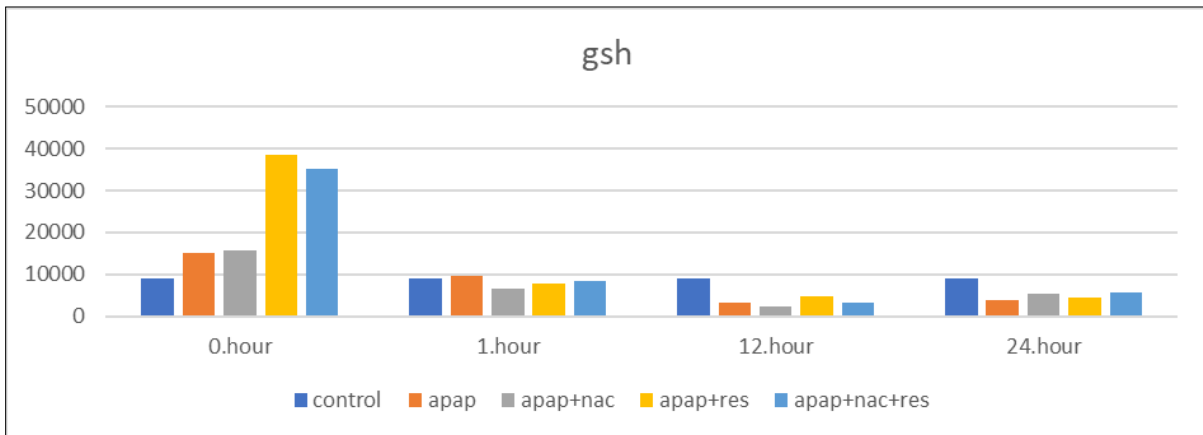


Figure 1. Chart showing the mean GSH levels of the study groups at baseline/1st/12th/24th hours

There was no statistically significant difference between the pairwise comparisons of the groups regarding the mean GSH levels at baseline, 1st hour and 24th hour ($p>0.05$, for all).

of the APAP+RES group was significantly higher than that of the APAP+NAC group ($p=0.007$). There was no statistically significant difference in other pairwise comparisons of the groups regarding the 12th-hour GSH levels ($p>0.05$ for all) (Figure 2).

When we compared the groups in terms of the mean GSH levels at the 12th hour, we found that the mean GSH level

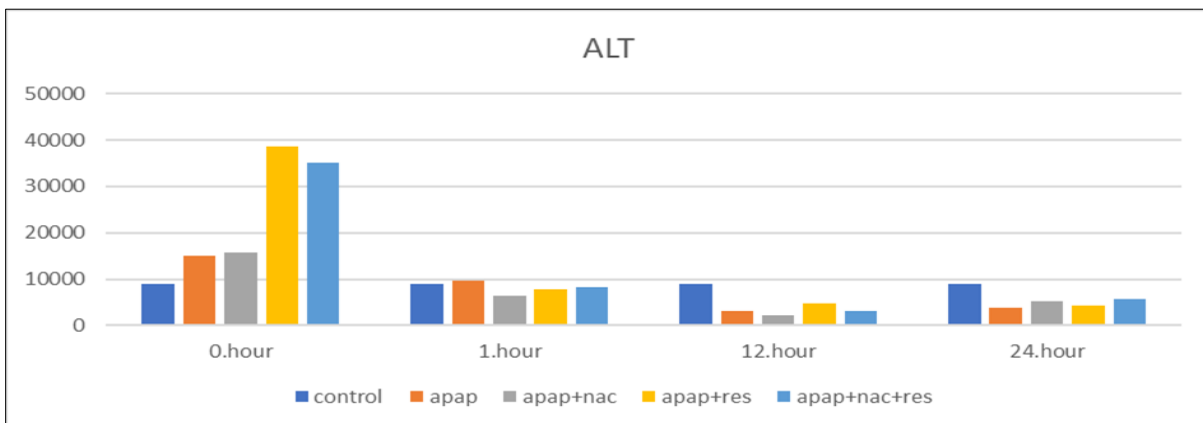


Figure 2. Chart showing the mean ALT level of the study groups at baseline/1st/12th/24th hours

There was no statistically significant difference between the groups in terms of the mean ALT levels at baseline, 1st hour, 12th hour and 24th hour ($p>0.05$, for all).

There was no statistically significant difference between the groups in terms of the mean ALT levels at baseline, 1st hour, 12th and 24th hours ($p>0.05$, for all) (Figure 3).

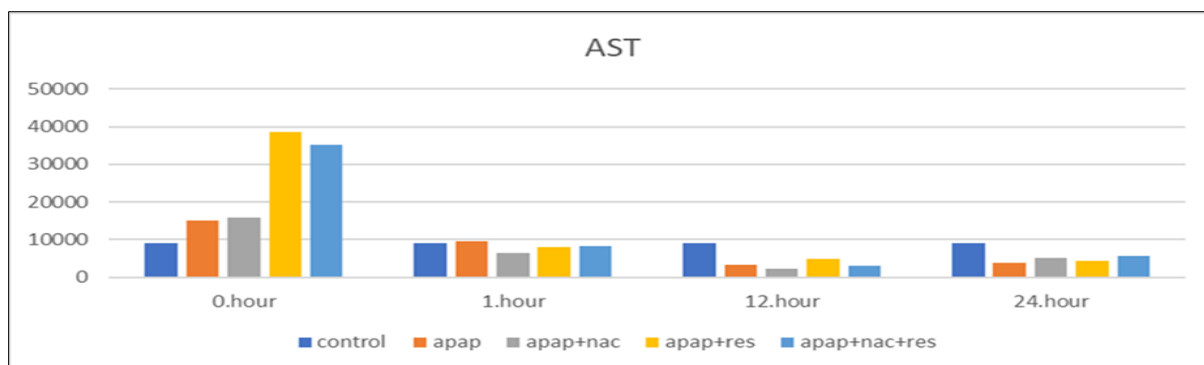


Figure 3. Chart showing the mean AST level of the study groups at baseline/1st/12th/24th hours

There was no statistically significant difference between the groups regarding the mean AST levels at the baseline, 1st hour, 12th hour, and 24th hour ($p > 0.05$, for all) (Figure 4).

There was no statistically significant difference between the groups regarding the mean APAP levels at the 1st hour, 12th hour, and 24th hour ($p > 0.05$, for all).

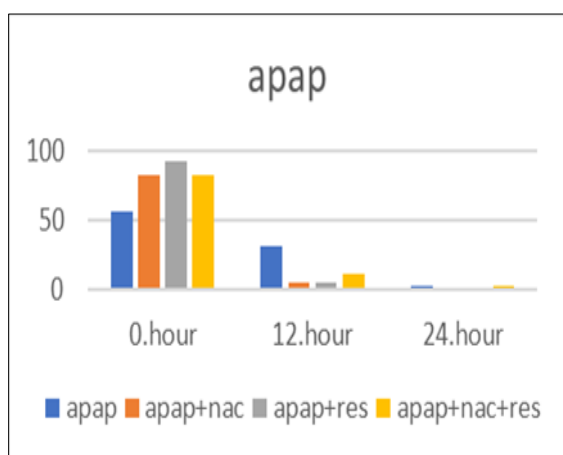


Figure 4. Chart showing the mean APAP level of the study groups at the 1st/12th/24th hours

HSCORE (Histological Scoring System)

The histological scoring (HSCORE) method was used in the histopathological evaluation of liver tissue samples of the rabbits in the study groups.

At the end of the experiment, liver tissue sampling was carried out from the liver caudate lobe of each subject, and the apoptosis status was examined according to the HSCORE using the anti-caspase-3 immunohistochemical staining method. The lowest rate of apoptosis was found in the control group, and the highest apoptosis rate was observed in the APAP group ($p = 0.012$) (Figure 5).

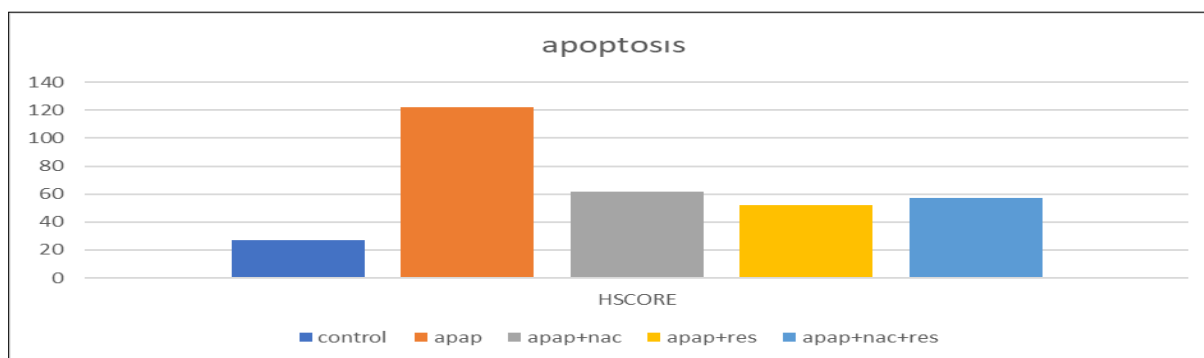
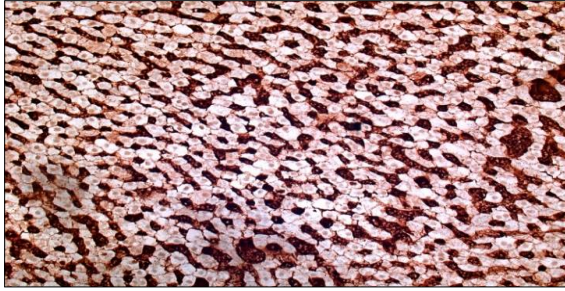

Figure 5. The mean HSCORE value of the study groups

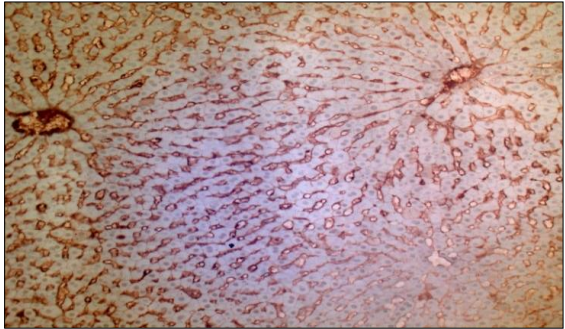
There was a statistically significant difference between the control group and the APAP group in terms of apoptosis rate ($p = 0.007$). There was no statistically significant difference in apoptosis rate of the other pairwise comparisons between the groups.

Microscopic Changes

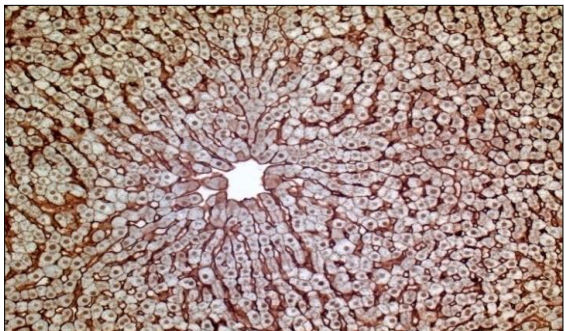
Tissue integrity and overall appearance of the cells were normal in the control group. There was no significant staining with anti-caspase 3 in the control group. The APAP group showed marked staining in both the cytoplasm and the nucleus (Picture 1, 2, 3)



Picture 1. Histopathological appearance of a tissue sample in the control group at x200 magnification by the anti-caspase 3 method. No significant staining was observed in the hepatocytes in either the cytoplasm or the nucleus of this sample.



Picture 2. The appearance of a tissue sample in the APAP+RES group at x200 magnification using the anti-caspase 3 method. This subject in the APAP+RES group has no staining in either the cytoplasm or the nucleus of hepatocytes.



Picture 3. The appearance of a tissue sample in the APAP+NAC+RES group at x200 magnification by the anti-caspase 3 method. In the hepatocytes of this subject in the APAP+NAC+RES group, the nucleus showed staining, but there was no significant staining in the cytoplasm.

DISCUSSION

In this study, we aimed to investigate whether Resveratrol treatment is an alternative or superior to NAC in the APAP toxicity in an experimental rabbit model. According to the results of our study, the serum GSH levels at baseline and the 12th hour showed statistically significant differences between the groups. The mean serum GSH level at the 12th hour was significantly lower in the APAP+NAC group compared to the APAP+RES group. When the mean GSH levels at the 24th hour were examined, and the highest serum GSH level was measured in the APAP+NAC+RES

group, the difference between the groups was not statistically significant. These findings suggest that resveratrol treatment may have favorable effects in the treatment of APAP toxicity when used alone or with NAC. When the groups were compared in terms of apoptosis, as expected, the HSCORE was lower in the control group than in the APAP group. In other words, apoptosis was induced together with hepatocyte damage due to APAP toxicity. In our study, no staining was detected in the nucleus and cytoplasm of the hepatic tissue of control subjects after staining using the anti-caspase 3 method. In the stained liver tissue samples of the APAP+RES group, we obtained similar results to the control group. In other words, the nucleus and cytoplasm stainings were not detected in the liver tissue samples of animals in the APAP+RES group. However, we detected nucleus and cytoplasm staining in hepatocytes, which are indicators of apoptosis, not only in the APAP group but also in the APAP+NAC group. This suggests that resveratrol use in APAP toxicity has protective effects on liver tissue, and this effect is superior to that of NAC.

There was a significant difference between the study groups regarding the serum ALT levels at the baseline, 1st hour, 12th hour and the 24th hour. Besides, the APAP group was the group with the highest ALT level throughout the experiment and especially with a sharp increase at the 12th hour. On the other hand, the ALT levels of the APAP+RES and APAP+NAC+RES groups were found to be lower than that of APAP+NAC and APAP groups during the experiment. The ALT levels of the APAP+RES group were found to be lowest at the 24th hour compared to the other groups. This may be interpreted as resveratrol having protective effects against liver damage caused by APAP toxicity. The same interpretation can be made by considering the serum AST levels of all groups during the experiment and by comparing the groups with each other in terms of the AST levels.

In our study, we measured the serum APAP level, which is an important parameter for treatment success and prognosis. There was no significant difference in the serum APAP levels between the groups, while in the APAP+RES, APAP+NAC, and APAP+NAC+RES groups, the sharp decrease at the 12th hour compared to the

1st hour was not observed in the APAP group. This suggests that resveratrol is as effective as NAC in the treatment of APAP toxicity. However, the serum APAP levels at the 24th hour decreased to very close values in all groups, including the APAP group. This result indicates that serum APAP levels decrease to very low levels within 24 hours in cases with APAP toxicity, even if treatment was not begun with NAC or any other drug.

Wojnarova et al. also used resveratrol as a hepatoprotective agent, as we used in our study. Resveratrol is a natural SIRT1 activator. SIRT1 (silent information regulator T1 protein) is an important molecule that regulates the cell cycle, apoptosis, and inflammation. In this study, the authors compared resveratrol, which they used as hepatoprotective agent, with CAY10591 (synthetic selective activator 1 activator), an artificial SIRT1 activator, in a rat model of APAP toxicity. Resveratrol and CAY have been shown to reduce acetaminophen-mediated hepatotoxicity both *in vivo* and *in vitro* experiments. In addition, both treatments have been shown to increase SIRT1 activity, which is reduced by APAP.¹³ In our study, the protective effects of resveratrol treatment at cellular level were observed in APAP toxicity.

Several studies have also shown the hepatoprotective activity of resveratrol.¹⁴⁻¹⁷ Resveratrol demonstrates a hepatoprotective effect against liver damage resulting from free radicals and inflammatory cytokines via increasing the levels of antioxidant enzymes and GSH. Resveratrol also shows a hepatoprotective effect by making changes in the signal transduction pathway.

There are many studies on the protective effect of resveratrol on liver diseases such as ethanol-induced liver damage, liver damage caused by carbontetrachloride, liver damage with atherogenic diet, liver damage with various chemicals and acetaminophen-induced liver damage.

In their experimental APAP toxicity-induced mice model using 30 mg/kg resveratrol, Şener et al. demonstrated the hepatoprotective effects of resveratrol in acetaminophen-induced liver injury by reducing free radicals via antioxidant mechanisms. They found that resveratrol decreased the serum levels of ALT, AST, MDA and TNF- α and in-

creased the GSH activity. They found that resveratrol reduced inflammation by reducing neutrophil infiltration.¹⁸ Consistent with this study, we showed in our study that resveratrol has favorable effects both biochemically and histopathologically.

Masubuchi et al. reported that resveratrol reduced the serum ALT, IL-6 and TNF- α levels in an experimental study using 75 mg/kg resveratrol in a mice model and exhibited the hepatoprotective effect.¹⁹

In a study by Wadsworth et al., resveratrol was shown to reduce the expression of a number of pro-inflammatory cytokines, including TNF- α .²⁰ However, none of these studies compared Resveratrol with NAC therapy.

In a rat model with APAP-induced liver injury, Elbe et al. used light and electron microscopy to examine the APAP-induced liver tissue and found an increase in the malondialdehyde (MDA) level and a reduction in GSH level, CAT(catalase) and SOD(superoxide dismutase) activity. They interpreted that APAP-induced hepatotoxicity was mediated by oxidative stress. In rats treated with resveratrol, they found significant beneficial changes in tissue oxidative stress indicators.²¹

In our study, the fact that resveratrol treatment was not given before the toxicity and that the duration of follow-up was limited to 24 hours were the main limitations. In addition, as a general rule, the results obtained from experimental studies cannot be generalized to humans.

The improvement effect of resveratrol in serum markers in the treatment of the experimental APAP toxicity model was similar to NAC. On the other hand, the hepatoprotective and curative effects on liver tissue were superior to NAC treatment.

Our study can be a reference for further studies to be carried out experimentally on this subject. Different results may be obtained with different experimental models, with a longer follow-up period and more frequent blood sampling.

In addition, our study also contains important results for clinical studies. Our results should be supported by further large-scale clinical studies.

Conflict of Interest

The authors declare that there is not any conflict of interest regarding the publication of this manuscript.

Ethics Committee Permission

Approval was obtained from the Experimental Animals Ethics Committee of Selçuk University Experimental Medicine Application and Research Center (Approval date, no: 14.07.2015-2015/77).

Authors' Contributions

Concept/Design: HGU, AB, HK, AU. Data Collection and/or Processing: AB, HGU, AS, HK, PK, AU. Data analysis and interpretation: HGU, AB, AU, AS, PK. Literature Search: AB, PK, AS. Drafting manuscript: HGU, HK. Critical revision of manuscript: HGU, AB, HK. Supervision: AB.

REFERENCES

- Bessems JG, Vermeulen NP. Paracetamol (acetaminophen)-induced toxicity: molecular and biochemical mechanisms, analogues and protective approaches. *Crit. Rev. Toxicol.* 2001;31(1):55-138.
- Bonkovsky HL, Kane RE, Jones DP, Galinsky RE, Banner B. Acute hepatic and renal toxicity from low doses of acetaminophen in the absence of alcohol abuse or malnutrition: evidence for increased susceptibility to drug toxicity due to cardiopulmonary and renal insufficiency. *Hepatology.* 1994;19(5):1141-1148.
- De La Lastra CA, Villegas I. Resveratrol as an antioxidant and pro-oxidant agent: mechanisms and clinical implications *Biochem Soc Trans.* 2007;35(5):1156-1160.
- Dernek S, İközler M, Erkasap N, et al. Cardioprotection with resveratrol pretreatment: improved beneficial effects over Standard treatment in rat hearts after global ischemia. *Scand Cardiovasc J.* 2004;38(4):245-254.
- Robb EL, Page MM, Wiens BE, Stuart JA. Molecular mechanisms of oxidative stress resistance induced by resveratrol: Specific and progressive induction of MnSOD. *Biochem Biophys Res Commun.* 2008;367(2):406-412.
- Baur JA, Pearson KJ, Price NL, et al. 2006. Resveratrol improves health and survival of mice on a high-calorie diet. *Nature.* 2006;444(7117):337-342.
- Lagouge M, Argmann C, Gerhart-Hines Z, et al. 2006. Resveratrol improves mitochondrial function and protects against metabolic disease by activating SIRT1 and PGC-1alpha. *Cell.* 2006;127(6):1109-1122.
- Saiko P, Szakmary A, Jaeger W, et al. Resveratrol and its analog: defense against cancer, coronary disease and neurodegenerative maladies or just a fad? *Mutat Res.* 2008;658(1-2):68-94.
- Mann CD, Neal CP, Garcea G, et al. Phytochemicals as potential chemopreventive and chemotherapeutic agents in hepatocarcinogenesis. *Eur J Cancer Prev.* 2009;18(1):13-25.
- Muriel P. NF-kB in liver diseases: a target for drug therapy. *J Appl Toxicol.* 2009;29(2):91-100.
- Pendurthi UR, Williams JT, Rao LV. Resveratrol, a polyphenolic compound found in wine, inhibits tissue factor expression in vascular cells: a possible mechanism for the cardiovascular benefits associated with moderate consumption of wine. *Arterioscler Thromb Vasc Biol.* 1999;19(2):419-426.
- Kuo D, Mitchell R, McGill Yuchao X, Mary LB, Hartmut J. Resveratrol prevents protein nitration and release of endonuclease from mitochondria during acetaminophen hepatotoxicity. *Food Chem. Toxicol.* 2015;81:62-70.
- Wojnarova L, Kutinova N, Farghali H, Kucera T. Sirtuin 1 Modulation in Rat Model of Acetaminophen-Induced Hepatotoxicity. *Physiol. Res.* 2015;64(4):477-487.
- Bishayee A, Darvesh AS, Politis T, McGory R. Resveratrol and liver disease: from bench to bedside and community. *Liver Int.* 2010;30(8):1103-1114.
- Wang Z, Jiang Y, Fan X, et al. Hepatoprotective effect of resveratrol against acetaminophen-induced liver injury is associated with inhibition of CYP-mediated bioactivation and regulation of SIRT-p53 signaling pathways. *Toxicol Lett.* 2015;236(2):82-89.
- Farghali H, Kutinova Canova N, Lekic N. Resveratrol and related compounds as antioxidants with an allosteric mechanism of action in epigenetic drug targets. *Physiol Res.* 2013;62(1):1-13.
- Černý D, Kutinova Canova N, Martinek J, et al. Effects of resveratrol pretreatment on tert-butylhydroperoxide induced hepatocytotoxicity in immobilized perfused hepatocytes: Involvement of inducible nitric oxide synthase and hemoxygenase-1. *Nitric Oxide.* 2009;20(1):1-8.
- Sener G, Toklu HZ, Şehirli AO, Velioglu-Oğunc A, Cetinel S, Gedik N. Protective effects of resveratrol against acetaminophen-induced toxicity in mice. *Hepatol. Res.* 2006;35(1):62-68.
- Masubuchi Y, Suda C, Horie T. Involvement of mitochondria permeability transition in acetaminophen-induced liver injury in mice. *J. Hepatol.* 2005;42(1):110-116.
- Wadsworth TL, Koop DR. Effects of the wine polyphenolics quercetin and resveratrol on pro-inflammatory cytokine expression in RAW 264.7 macrophages. *Biochem Pharmacol.* 1999;57(8):941-949.
- Elbe H, Gul M, Çetin A, et al. Resveratrol reduces light and electron microscopic changes in acetaminophen-induced hepatotoxicity in rats: Role of Inos expression. *Ultrastruct. Pathol.* 2018;42(1):39-48.