

EDİTÖRE MEKTUP/LETTER TO THE EDITOR

A rare cause of esophageal ulcer: chestnut

Özofagus ülserinin nadir bir nedeni: kestane

Adnan Taş¹, Mehmet Suat Yalçın¹, Şehmus Ölmez¹, Banu Kara¹

¹Adana Numune Research and Education Hospital, Department of Gastroenterology, Adana, Turkey

Cukurova Medical Journal 2016;41(Suppl 1):122-123.

Dear Editor,

There are many causes of esophageal ulcer. These causes include drugs, lymphoma, cytomegalovirus, cancers and gastroesophageal reflux disease^{1,2,3,4,5}. Here, we have presented a rare case who has not ever been reported as a cause of esophageal ulcer.

A 25-year old male patient was admitted to gastroenterology clinic with retrosternal pain and odynophagia shortly after eating chestnut. Because the food was hot, he swallowed it without chewing. There was no other medication, alcohol use or any other health problems in the history. The physical examination and biochemical analysis were normal. In esophagoscopy, there were two ulcers in 2 and 3 cm diameter with white exudates at the mild esophagus (Figure 1).

In the histopathologic evaluation, nonspecific acute inflammatory changes were found. Esomeprazole 40 mg bid and sucralfate 2 gr qid were given as management. All symptoms were improved and he was asymptomatic at the tenth days of the treatment. In esophagoscopy which was repeated 20 days later was normal.

The etiology of esophageal ulcers included gastrointestinal reflux disease, drug induced, candidal, caustic injury, and herpes simplex virus, human immunodeficiency virus, cytomegalovirus, foreign body as in our case⁵. The patients with esophageal ulcer complain retrosternal pain, dysphagia and odynophagia as in our case. Esophageal ulcers except cancers and lymphoma may have been given protone pump inhibitors and

sucralfate as in our case⁵.

In conclusion, esophageal ulceration must be suspected in patients with retrosternal pain and odynophagia after eating hot meal.

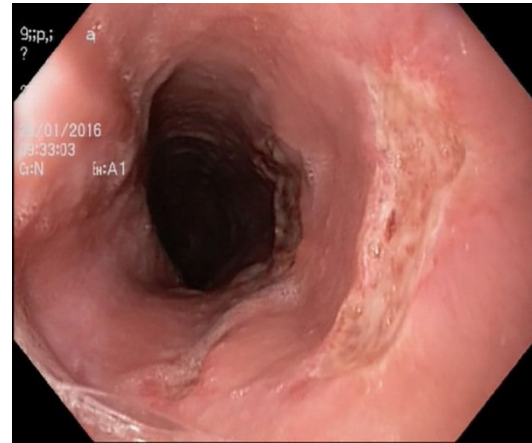


Figure 1. Endoscopic view of esophageal ulcer in the middle esophagus.

REFERENCES

1. Ikuta K, Umeda M, Seno H. Esophageal ulcer due to lymphoma. Intern Med. 2014;53:2649-50.
2. Dağ MS, Öztürk ZA, Akın I, Tutar E, Çıkman Ö, Gülşen MT. Drug-induced esophageal ulcers: case series and the review of the literature. Turk J Gastroenterol. 2014;25:180-4.
3. Jang HJ, Kim AS, Hwang JB. Cytomegalovirus-associated esophageal ulcer in an immunocompetent infant: When should ganciclovir be administered?

Yazışma Adresi/Address for Correspondence: Dr. Adnan Taş, Adana Numune Research and Education Hospital, Department of Gastroenterology, Adana, Turkey E-mail: dradnantas@gmail.com
Geliş tarihi/Received: 15.05.2016 Kabul tarihi/Accepted: 06.06.2016

- Korean J Pediatr. 2012;55:491-3.
4. Samiullah S, Samad F, Tang YM, Abdullah N, Mariam M, Shaikh Z et al. Double lumen esophagus: a rare complication of gastroesophageal reflux disease. *Dig Endosc.* 2014;26:282-4.
 5. Higuchi D, Sugawa C, Shah SH, Tokioka S, Lucas CE. Etiology, treatment, and outcome of esophageal ulcers: a 10-year experience in an urban emergency hospital. *J Gastrointest Surg.* 2003;7:836-42.