

## A NEW TECHNIQUE FOR MINILAPAROTOMY

(Received 16 December, 1991)

**F. Durmuşoğlu, M.D.\* / E.C. Tüfekçi, M.D.\*\* / K. Kutlay M.D.\*\*\* / T. Pekin, M.D.\*\*\***

- \* Assistant Professor, Department of Obstetrics and Gynecology, Faculty of Medicine, Marmara University, İstanbul, Türkiye.
- \*\* Specialist, Department of Obstetrics and Gynecology, Zeynep Kamil Maternity Hospital, İstanbul, Türkiye.
- \*\*\* Research Assistant, Department of Obstetrics and Gynecology, Faculty of Medicine, Marmara University, İstanbul, Türkiye.

### SUMMARY

This new technique provides better exposure, adequate control of pelvic viscera and furthermore, excludes unnecessary ancillary instrumentation as in sounding or elevation of the uterus. We strongly recommend this procedure, especially in developing countries where there is room for and need of minilaparotomy for surgical sterilization.

**Key Words :** Female sterilization, Minilaparotomy

### INTRODUCTION

Female sterilization is now such an established and accepted component of many national family planning programs that its existence requires no further justifications. The arguments for and against laparoscopy or minilaparotomy have been stated many times.

Laparoscopy requires surgeons trained in the method and expensive and a relatively delicate equipment. Moreover, it carries with it hazards associated with blind penetration of the abdomen. On the other hand, minilaparotomy is rapid, requires only a small incision needing little or no aftercare and is associated with little post-operative discomfort. In addition it also requires simple, durable, and inexpensive instrumentation and no special surgical skill is needed (1,2)

### MATERIALS AND METHOD

Twenty-five patients were admitted to the study. The average patient age was 33.4 years with a standard deviation of 5.5 years. Mean body weight was  $60.32 \pm 5.65$  kg. and mean height was  $163 \pm 4.7$  cm. None of the patients had previous operations nor medical conditions to increase surgical risks. Standard surgical instruments were used with the exception of a uterine elevator and tenaculum to manipulate the uterus.

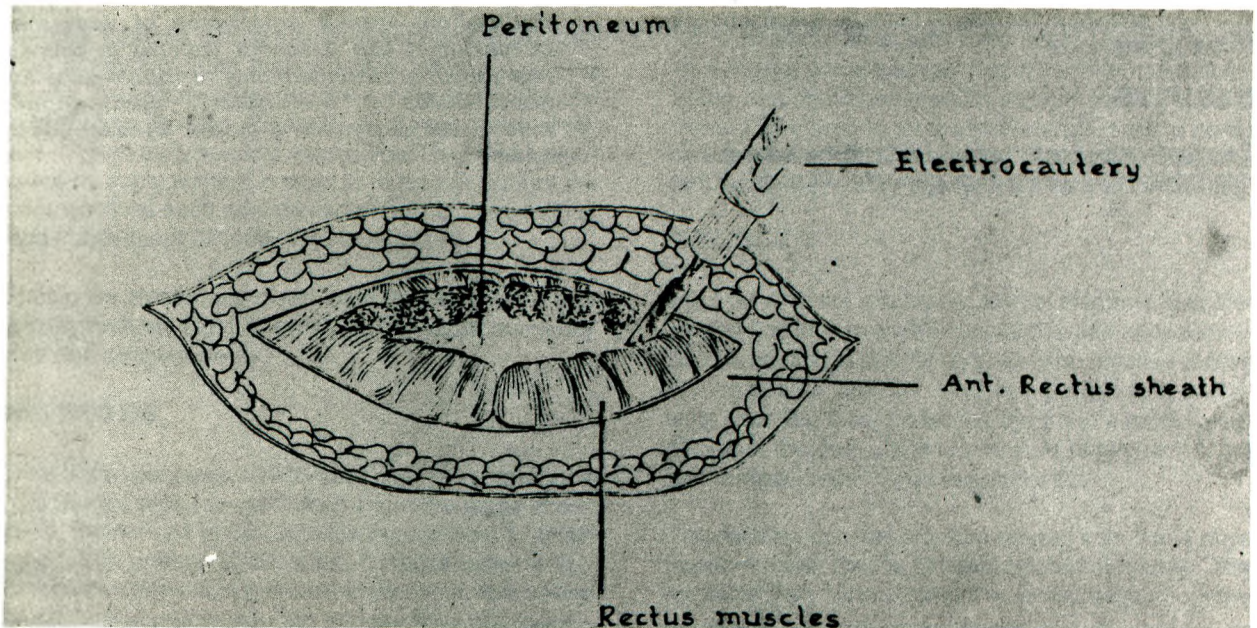


Figure 1: Electrocautery is used to transect the one third medial portion of rectus muscle.

## SURGICAL PROCEDURE

The patients admitted to the study were informed of the permanent effect of the procedure. An informed consent form for tubal ligation was signed and a complete physical examination was performed. General anesthesia with endotracheal tube was used in all operations.

A three centimetre transverse skin incision was made above the symphysis pubis and was carried down to the anterior rectus sheath by using electrocautery. Two right angled retractors were used for better visualization. A transverse incision was made on the rectus sheath fascia and was carried down to the one third medial portions of the two rectus muscles by using electrocautery. This procedure is the main differentiating point of this technique, (Fig. 1).

After inserting retractors beneath divided rectus muscles in both directions, the incision on the parietal peritoneum was also made transversely. Subsequently, the retractors were placed inside the peritoneal cavity, mobilizing the uterus into the surgical field without using any kind of vaginal manipulation. The tubes were grasped with babcock forceps and pulled out to the incision one at a time. Pomeroy tubal ligation technique was applied on the whole population. In difficult cases, small Deaver retractors were used to visualize the tubes. At the end of surgical sterilization, the peritoneal edges were sutured with 2 - 0 chromic catgut in a transverse fashion. The anterior rectus sheath was then closed, excluding the divided position of rectus muscles, with 2.0 synthetic absorbable sutures.

After closing the skin, the patients were observed for one night and were discharged from the hospital on the following day.

## RESULTS

Twenty-five patients were sterilized by suprapubic minilaparotomy using this new modification at the

entrance to abdominal cavity. The mean time for performing the operation was 13.8 minutes. No attempt to achieve tubal occlusion failed. Neither readmissions nor complications occurred in any of the cases.

## DISCUSSION

Despite the other methods of surgical sterilization, minilaparotomy conserves its own place in surgical sterilization. In this study, the documentation of this simple modification to the entrance of the peritoneal cavity makes the classical technique more conventional and less risky. As previously mentioned in the essay, cutting one third medial portion of rectus muscles and the transverse opening of parietal peritoneum, provides better exposure and reduced operational time. In the classical minilaparotomy technique, leaving the rectus muscles intact and opening the peritoneum vertically further restricts the already restricted surgical area. Especially in training hospitals, the time loss during minilaparotomy procedure makes it inferior to other modalities. In fact there is a marginal benefit from the laparoscopic approach to the fallopian tube. In the literature there are no significant differences of advantages and disadvantages between laparoscopy and minilaparotomy (3).

## REFERENCES

1. *Osathanondh V. Suprapubic minilaparotomy, uterine elevation technique; Simple inexpensive and out-patient procedure for interval female sterilization. Contraception 1974;10:251.*
2. *Penfield AJ. Minilaparotomy for female sterilization. Obstet Gynecol 1979;54:184.*
3. *World Health Organization. Task force on female sterilization, special programme of Research, Development and Research Training in Human Reproduction: Minilaparotomy or Laparoscopy for Sterilization. A multicenter, multinational randomized study. Am J Obstet Gynecol 1982; 143:645.*