

Case Report / Olgu Sunumu

An atypical case of pantothenate kinase-associated neurodegeneration (PKAN) initially presenting with stammering and speech disorder

Türkçe başlık İlk bulguları kekeleme ve konuşma bozukluğu olan atipik bir pantotenat kinaz ile ilişkili nörodejenerasyon (PKAN) olgusu

Fatma Müjgan Sönmez^{1,1}, Ahsen Dönmez², Serdar Ceylaner³, Eyüp Üçtepe¹, Halil İbrahim Aydın⁴

Departments of ¹Child Neurology, ²Pediatrics and ⁴Pediatric Nutrition and metabolism, TurgutOzal University, Faculty of Medicine, TR-06510 Ankara; ³Intergen Genetics Center, Ankara

Abstract

Pantothenate kinase-associated neurodegeneration (PKAN) (previously called Hallervorden-Spatz disease) is an autosomal recessive neurodegenerative disorder that is characterized by pyramidal and extrapyramidal findings. We describe a 15-year-old Turkish male with an atypical form of PKAN whose only early symptoms were stammering and hyperactivity, leading to a misdiagnosis of speech disorder and attention hyperactivity; he had been treated with speech therapy and methylphenidate until admission to our clinic. Cranial magnetic resonance imaging (MRI) revealed a typical eye-of-the-tiger sign, and PANK2 mutation was determined. We should note that the atypical type of PKAN could appear as stammering and ADHD in the initial stage. Thus, the juvenile patient with stammering and slowly progressive speech disorder, parental consanguinity and a similar family history should be evaluated by brain MRI to search for the eye-of-the-tiger sign to elucidate PKAN before initiating the other psychiatric treatments.

Keywords: Pantothenate kinase-associated neurodegeneration, atipik; stammering; speech disorder

¹ Corresponding author:

Dr. Fatma Mujgan Sonmez, Çocuk Nörolojisi Bilim Dalı, Turgut Özal Üniversitesi Tıp Fakültesi, TR-06510 Ankara

Email: mjgsonmez@yahoo.com

Sonmez et al.: An atypical case of pantothenate kinase-associated neurodegeneration (PKAN) initially presenting with stammering and speech disorder

104

This is an open-access article distributed under the terms of the Creative Common Attribution License, which permits unrestricted use, distribution, and reproduction in any medium, provided the original author(s) and source are credited.

This article may be cited as: Sönmez FM, Dönmez A, Ceylaner S, Üçtepe E, Aydın HA. An atypical case of pantothenate kinase-associated neurodegeneration (PKAN) initially presenting with stammering and speech disorder. Basic Clin Sci 2015; 4: 104. DOI: [dx.doi.org/ 10.12808/bcs.v4i2.5000149955](https://doi.org/10.12808/bcs.v4i2.5000149955). Available from: dergipark.ulakbim.gov.tr/bcs.

Özet

Pantotenat kinaz ile ilişkili nörodejenerasyon (PKAN) (önceden Hallervorden-Spatz hastalığı olarak bilinen) otozomal nörodejeneratif bir hastalıktır ve pramidal ve ekstrapramidal bulgular ile karakterizedir. Burada atipik bir PKAN formu ile başvuran 15 yaşında bir Türk erkek olguyu sunuyoruz. İlk bulgularının sadece kekeleme ve hiperaktivite olması nedeniyle kliniğimize başvurmadan önce konuşma bozukluğu ve hiperaktivite tanıları ile konuşma tedavisi ve metilfenidat tedavileri almıştır. Kranial manyetik rezonans görüntüleme (MRI) ile atipik kaplan gözü bulgusu ve PANK2 mutasyonu bulunmuştur. Bu bilgiler ışığında PKAN olgularının kekeleme ve konuşma bozukluğu ile de başvurabileceğine dikkat çekmek istiyoruz. Jüvenil hastalarda kekeleme ve yavaş ilerleyen konuşma bozukluğu gözlemlendiğinde parenteral akrabalık ve benzer aile öyküsü gibi ek etkenlerde var ise beyin MRI incelemesi ile kaplan gözü bulgusunun aranması PKAN ayırıcı tanısının psikiyatrik tedavilerden önce konulmasına yardımcı olabilir.

Anahtar sözcükler: Pantotenat kinaz ile ilişkili nörodejenerasyon, atipik; kekeleme; konuşma bozukluğu

Introduction

Pantothenate kinase-associated neurodegeneration (PKAN), previously known as Hallervorden-Spatz disease [HSD]), is a rare autosomal recessive hereditary disorder characterized by pyramidal and extrapyramidal findings, including dystonia, rigidity, choreoathetosis, mental deterioration, dysarthria, and retinal degeneration, due to a defect in the pantothenate kinase gene (PANK2) [1-4]. PKAN was first described in 1922 as a familial childhood disorder characterized by progressive extrapyramidal features and dementia. The disease was classified according to age of onset as classical or atypical form.

In this report, we present a male adolescent with the clinically atypical form of PKAN whose only early symptoms were stammering and attention deficit-hyperactivity disorder (ADHD).

Case Report

A 15-year-old-male patient was admitted to our clinic with complaints of stammering and progressive speech disorder and limitation of movement on the left hand. He was born to first- cousin parents as the third child of the family following an uneventful delivery. His mental and motor development was normal until seven years of age, at which time progressive stammering began. He was also diagnosed at that time as ADHD according to the Diagnostic and Statistical Manual of Mental Disorders (DSM)-IV. Risperidone and speech therapy were started at another center, and the patient was followed by the Child Psychiatry and Otorhinolaryngology Departments. Two years ago, while he was cutting wood, he suffered an injury to his left wrist for which he underwent surgery twice.

Sonmez et al.: An atypical case of pantothenate kinase-associated neurodegeneration (PKAN) initially presenting with stammering and speech disorder 105

This is an open-access article distributed under the terms of the Creative Common Attribution License, which permits unrestricted use, distribution, and reproduction in any medium, provided the original author(s) and source are credited.

This article may be cited as: Sönmez FM, Dönmez A, Ceylaner S, Üçtepe E, Aydın HA. An atypical case of pantothenate kinase-associated neurodegeneration (PKAN) initially presenting with stammering and speech disorder. Basic Clin Sci 2015; 4: 104. DOI: [dx.doi.org/ 10.12808/bcs.v4i2.5000149955](https://doi.org/10.12808/bcs.v4i2.5000149955). Available from: dergipark.ulakbim.gov.tr/bcs.

The patient's family history revealed four other patients (3 maternal uncles [1 with Parkinson's disease] and 1 daughter of another maternal uncle) (Fig. 1). One of the patient's three affected maternal uncles had spasms of the mouth and died at the age of 55. The affected 21-year-old female cousin had a history similar to that of our patient. She had progressive dystonia and eye-of-the-tiger finding on magnetic resonance imaging (MRI).

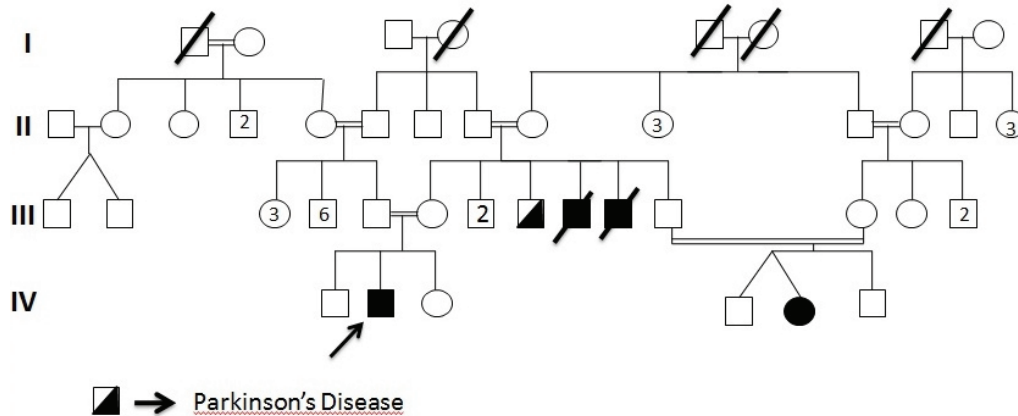


Figure 1. Pedigree of the patient.

The physical examination revealed deformity and surgical scar on his left hand. The neurological examination revealed ataxia, flexion disability and dystonia on the left hand and peroral region during speaking and 3/5 motor deficiency of the left hand and fingers. He had stammering, dysarthria and difficulty in initiating speech. No retinitis pigmentosa or optic atrophy was present on the ocular examination.

Laboratory investigations including hematological and biochemical results were normal. Acanthocytosis was not described on peripheral blood analyses. Cranial MRI showed bilateral marked hypointensity with a central region of hyperintensity in the medial globuspallidus, indicating iron, called eye-of-the-tiger sign (Fig. 2).

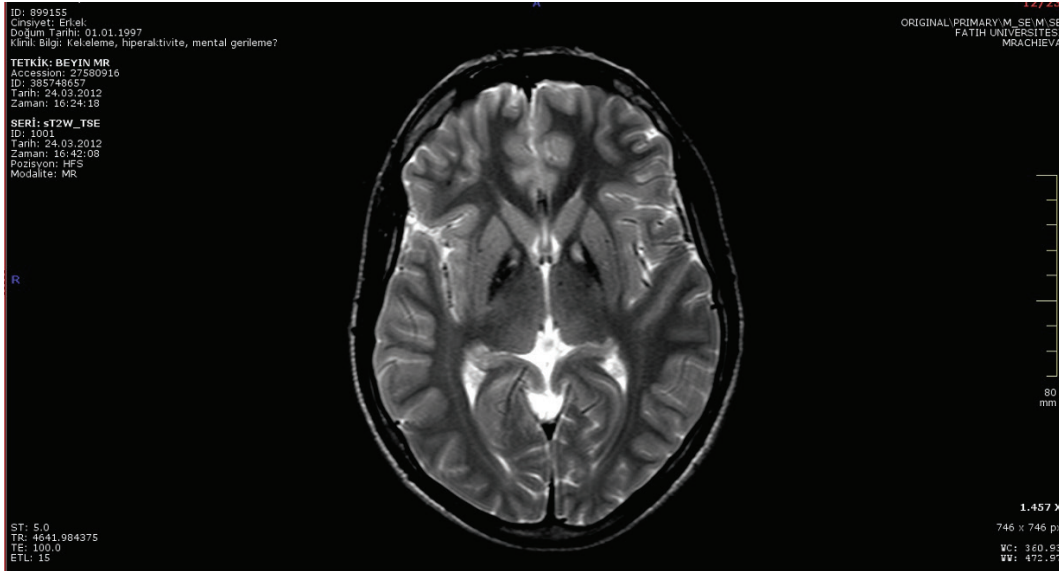


Figure 2. T2-weighted cranial MRI of the case showed bilateral marked hypointensity with a central region of hyperintensity in the medial globus pallidus indicating iron, referred to as eye-of-the-tiger sign.

For the genetic analyses, an EDTA blood sample was taken, and DNA isolation was done by spin column method. Polymerase chain reaction (PCR) and sequence analysis of the entire coding region of the PANK2 gene were performed with ABI 3 1 3 0 capillary electrophoresis with the primers designed by using Ensembl ENST00000 3 1 6 5 6 2 transcript. A c.8 33G>T (p.R 2 7 8L) homozygote mutation was detected. This mutation is reported in the Human Genome Mutation Database (HGMD) (code CMO 3 3 4 2 3) as a disease-causing mutation.

Discussion

Pantothenate kinase-associated neurodegeneration (PKAN) is a major form of the syndrome of neurodegeneration with brain iron accumulation (NBIA) and accounts for approximately 50% of cases of NBIA [1]. Deficiency of PANK2 leads to the accumulation of cysteine-containing neurotoxic compounds that cause tissue damage and excessive iron accumulation in iron-rich brain regions [5].

The classification of PKAN can be made according to age at onset [1,6]. The majority of the cases are classic and therefore relatively homogeneous [1]. In the classic variant, symptoms usually begin around 3-4 years of age, and usually before six years of age [1,5]. Gait or postural difficulty is usually the presenting symptom [1]. This group is characterized by progressive pyramidal (spasticity, hyperreflexia, extensor toes) and extrapyramidal symptoms with prominent dystonia. Prominent oromandibular

Sonmez et al.: An atypical case of pantothenate kinase-associated neurodegeneration (PKAN) initially presenting with stammering and speech disorder

107

This is an open-access article distributed under the terms of the Creative Common Attribution License, which permits unrestricted use, distribution, and reproduction in any medium, provided the original author(s) and source are credited.

This article may be cited as: Sönmez FM, Dönmez A, Ceylaner S, Üçtepe E, Aydın HA. An atypical case of pantothenate kinase-associated neurodegeneration (PKAN) initially presenting with stammering and speech disorder. Basic Clin Sci 2015; 4: 104. DOI: dx.doi.org/ 10.12808/bcs.v4i2.5000149955. Available from: dergipark.ulakbim.gov.tr/bcs.

involvement is a characteristic sign [4]. Other extrapyramidal features including chorea or parkinsonism and cognitive features such as behavioral changes and dementia may occur. These children usually lose ambulation by 10-15 years after disease onset [2].

The atypical type of PKAN is a clinically heterogeneous disease and onset is much later and slowly progressive. The symptoms may start between the ages of 20-30 with retinopathy and cognitive and psychiatric disorders [5-8]. In some cases, initiation before this age was also reported. In the atypical form, speech difficulty is a frequent presenting sign and includes palilalia, tachylalia/tachylogia, dysarthria to anarthria, hypophonia, and difficulty initiating speech [1].

Other presenting symptoms include mild gait abnormalities and prominent psychiatric symptoms such as depression, emotional lability, impulsivity, obsessive compulsive disorder, and violent outbursts [9-11]. Tourettism has also been reported in the early stages of atypical PKAN. In this group, extrapyramidal features may be seen in the late period, and the loss of ambulation occurs within 15-40 years of initiation of the disease.

Atypical cases of PKAN are probably not being recognized, similar to our patient. In our patient, the only symptom appearing in the early stage of the disease was stammering and ADHD, which led to the misdiagnosis of speech disorder and ADHD. According to the patient's history, this symptom slowly progressed, and when we evaluated the patient, he had stammering, dysarthria, and difficulty initiating speech. Oner et al.[11] reported a case of PKAN with hyperactivity attention problems in childhood and adolescence with difficulties in achieving adequate school performance, and their patient also had stuttering in the first year of school, similar to our case. However, the major findings in their case were psychotic symptoms.

Pantothenate kinase-associated neurodegeneration (PKAN), atypical neuroaxonal dystrophy (NAD), and idiopathic NBIA have similar presentations and can be distinguished by MRI. The characteristic MRI finding of PKAN is the eye-of-the-tiger sign, and this finding is correlated with the presence of a PANK2 mutation in both classical and atypical forms. The hypointensity on the T2-weighted image is because of iron deposition, and the central hyperintensity is due to the glioses and spongioses due to cell death. There is an absolute correlation between the presence of a mutation in PANK2 and the eye-of-the-tiger sign.

The eye-of-the-tiger sign can sometimes be seen in some cases of neuroferritinopathy, dihydropteridinereductase deficiency and non-NBIA conditions such as corticobasal ganglia degeneration and progressive supranuclear palsy. However, in neuroferritinopathy, involvement of the caudate and putamen, as well as thalamus and cerebral cortex, is the differential finding from PKAN. In dihydropteridinereductase deficiency, associated findings are cortical calcifications and cysts [12].

Pantothenate kinase-associated neurodegeneration (PKAN) is caused by mutations in the gene encoding PANK2. The gene is located on chromosome 20p13. PANK2 is a key regulatory enzyme in the biosynthesis of coenzyme-A, critical to energy metabolism, fatty

Sonmez et al.: An atypical case of pantothenate kinase-associated neurodegeneration (PKAN) initially presenting with stammering and speech disorder 108

This is an open-access article distributed under the terms of the Creative Common Attribution License, which permits unrestricted use, distribution, and reproduction in any medium, provided the original author(s) and source are credited.

This article may be cited as: Sönmez FM, Dönmez A, Ceylaner S, Üçtepe E, Aydın HA. An atypical case of pantothenate kinase-associated neurodegeneration (PKAN) initially presenting with stammering and speech disorder. *Basic Clin Sci* 2015; 4: 104. DOI: [dx.doi.org/ 10.12808/bcs.v4i2.5000149955](https://dx.doi.org/10.12808/bcs.v4i2.5000149955). Available from: dergipark.ulakbim.gov.tr/bcs.

acid synthesis and degradation, and neurotransmitter and glutathione metabolism [2]. In humans, three additional genes encoding related proteins are PANK1, 3, and 4, but only PANK2 is targeted to mitochondria [2]. Deficiency of PANK2 leads to the accumulation of cysteine-containing neurotoxic compounds that cause tissue damage and excessive iron accumulation in iron-rich brain regions [2]. Oner et al.[11] suggested that almost all of the classical cases have PANK2 mutations, with more prominent speech-related and psychiatric symptoms, similar to our case.

We should note that the atypical type of PKAN could appear as stammering and ADHD in the initial stage. Thus, the juvenile patient with stammering and slowly progressive speech disorder, parental consanguinity and a similar family history should be evaluated by brain MRI to search for the eye-of-the-tiger sign to elucidate PKAN before initiating the other psychiatric treatments.

Conflict of Interest

The authors declare that no scientific and/or financial conflicts of interest exists with other people or institutions.

References

1. Hayflick SJ, Westaway SK, Levinson B, et al. Genetic, clinical and radiographic delineation of Hallervorden-Spatz syndrome. *N Engl J Med.* 2003; 348: 33-40.
2. Gregory A, Polster BJ, Hayflick SJ. Clinical and genetic delineation of neurodegeneration with brain iron accumulation. *J Med Genet.*2009; 46: 73-80.
3. Sunwoo YK, Lee JS, Kim W-H, et al. Psychiatric disorder in two siblings with Hallervorden-Spatz disease. *Psychiatry Invesig.*2009; 6: 226-229.
4. Schneider SA, Hardy J, Bhatia KP. Syndromes of neurodegeneration with brain iron accumulation (NBIA): an update on clinical presentations, histological and genetic underpinnings, and treatment considerations. *MovDisord.*2012; 27: 42-53.
5. Hayflick SJ. Neurodegeneration with brain iron accumulation: from genes to pathogenesis. *SeminPediatr Neurol.* 2006; 13: 182-185.
6. Antonini A, Goldwurm S, Benti R, et al. Genetic, clinical and imaging characterization of one patient with late-onset, slowly progressive, pantothenate kinase-associated neurodegeneration. *MovDisord.*2006; 21: 417-418.
7. Aggarwal A, Schneider SA, Houlden H, et al. Indian-subcontinent NBIA: unusual phenotypes, novel PANK2 mutations, and undetermined genetic forms. *MovDisord.* 2010; 25: 1424-1431.
8. Yoon WT, Lee WY, Shin HY, et al. Novel PANK2 gene mutations in Korean patient with pantothenate kinase-associated neurodegeneration presenting unilateral dystonic tremor. *MovDisord.*2010; 25: 245-247.
9. Vansteenkiste I, van Gool WA, Hofstee DJ, Tijssen MA. Conversion disorder as initial diagnosis in pantothenate kinase associated neurodegeneration. *J Neurol.*

Sonmez et al.: An atypical case of pantothenate kinase-associated neurodegeneration (PKAN) initially presenting with stammering and speech disorder 109

This is an open-access article distributed under the terms of the Creative Common Attribution License, which permits unrestricted use, distribution, and reproduction in any medium, provided the original author(s) and source are credited.

This article may be cited as: Sönmez FM, Dönmez A, Ceylaner S, Üçtepe E, Aydın HA. An atypical case of pantothenate kinase-associated neurodegeneration (PKAN) initially presenting with stammering and speech disorder. *Basic Clin Sci* 2015; 4: 104. DOI: [dx.doi.org/ 10.12808/bcs.v4i2.5000149955](https://doi.org/10.12808/bcs.v4i2.5000149955). Available from: dergipark.ulakbim.gov.tr/bcs.

- 2011; 258: 152-154.
10. del Valle-López P, Pérez-García R, Sanguino-Andrés R, González-Pablos E. Adult onset Hallervorden-Spatz disease with psychotic symptoms. *ActasEsp Psiquiatr.* 2011; 39: 260-262.
 11. Oner O, Oner P, Deda G, Icgasioglu D. Psychotic disorder in a case with Hallervorden-Spatz disease. *ActaPsychiatr Scand.* 2003; 108: 394-397.
 12. McNeill A, Birchall D, Hayflick SJ, et al. T2* and FSE MRI distinguishes four subtypes of neurodegeneration with brain iron accumulation. *Neurology.* 2008; 70: 1614-1619.

Sonmez et al.: An atypical case of pantothenate kinase-associated neurodegeneration (PKAN) initially presenting with stammering and speech disorder 110

This is an open-access article distributed under the terms of the Creative Common Attribution License, which permits unrestricted use, distribution, and reproduction in any medium, provided the original author(s) and source are credited.

This article may be cited as: Sönmez FM, Dönmez A, Ceylaner S, Üçtepe E, Aydın HA. An atypical case of pantothenate kinase-associated neurodegeneration (PKAN) initially presenting with stammering and speech disorder. Basic Clin Sci 2015; 4: 104. DOI: [dx.doi.org/ 10.12808/bcs.v4i2.5000149955](https://doi.org/10.12808/bcs.v4i2.5000149955). Available from: dergipark.ulakbim.gov.tr/bcs.