

## THE CLOSURE OF MEDIUM TO LARGE URETHRAL FISTULAS BY FLIP FLAP PROCEDURE

(Received 22 September, 1992)

**E. Mavili M.D\*\* / F. Özgür M.D.\*\* / A.Keçik, M.D\***

- \* *Professor, Department of Plastic and Reconstructive Surgery, Hacettepe University, Faculty of Medicine, Ankara, Türkiye.*
- \*\* *Assistant Professor, Department of Plastic and Reconstructive Surgery, Hacettepe University, Faculty of Medicine, Ankara, Türkiye.*

### SUMMARY

Urethral fistula formation is a rather frequent complication of hypospadias repair. 7 patients with medium to large urethral fistulas underwent surgery for closure of the fistulae during the years 1990 and 1991. The flip flap procedure described for the correction of distal penile hypospadias was used for repair of fistulae in these patients. The follow-up period ranged between 2-17 months. In two patients the fistulas persisted after the operation but diameter of the fistulas were decreased remarkably. Although flip flap procedure is widely used for primary hypospadias repair, its use for closure of urethral fistula is not reported in the literature.

**Key words:** Urethral fistula, Flip flap, Hypospadias

### INTRODUCTION

Urethral fistula continues to be the most common complication of hypospadias surgery. Problems such as hematoma, infection, erection, incorrect suturing, overlapping suture lines, inadequate urinary diversion increase the incidence of fistula formation. The rate of fistula formation have been reported to vary greatly in different series. Culp (1) reported 17% fistulas with his modification of the Cecil technique, 30 % with the Dennis-Browne technique, 50 % with the Thiersh-Duplay technique. Wray et al. (2) reported 21% fistulas with Byars technique. Van der Meulen (3) observed no postoperative fistula in 200 hypospadias patients operated with his technique. Dvir (4) observed 3.75% fistula formation with the same technique. Horton et al. (5) have encountered a fistula rate of 15% in 750 patients repaired with their one stage hypospadias repair technique.

This paper describes the use of flip flap for closure of large and medium sized urethral fistulas.

### MATERIALS AND METHODS

From March 1990 to August 1991, 7 cases with

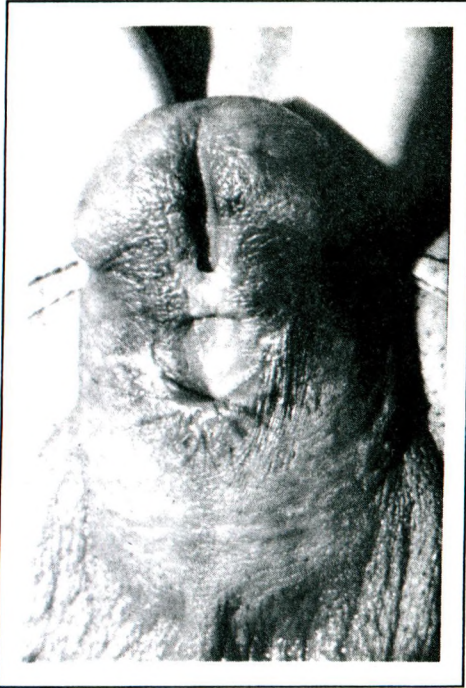medium to large urethral fistulas were operated on in our department, using the flip flap procedure. The ages of the patients ranged between 6 to 23. In 2 of the patients the fistulas appeared after the correction of distal penile hypospadias with flip flap procedure. 4 patients had developed urethral fistulas following the repair of penile hypospadias with different techniques in other hospitals. In one patient the fistula followed the circumcision done by an unqualified circumciser.

The diameters of the fistulas were determined with the use of urethral catheter of the appropriate size. The sizes of the fistulas were large enough for the passage of catheters between F-10 to F-16. The time elapsed between primary hypospadias surgery and our operation was 1 to 12 years.

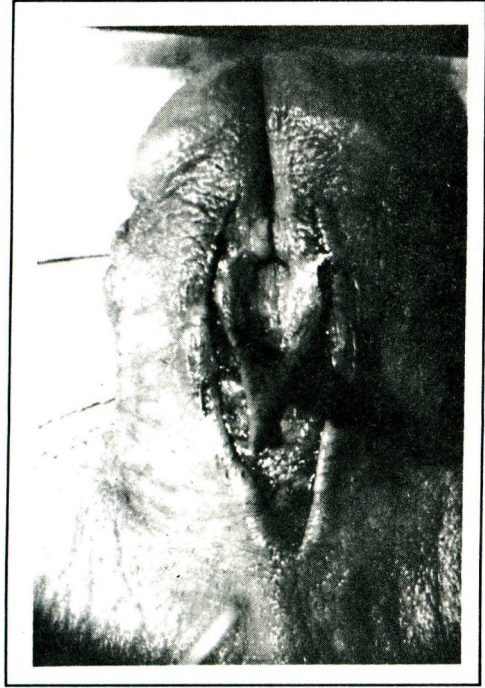
**Technique :** A ventral flip flap based on the proximal border of the fistula is elevated. (Figs 1a, 1b). The width of the flap is planned in correlation to the width of the fistula. The length of the flap varies in accordance with the situation of the distal urethra. If the distal urethra is patent the flip flap is designed just to cover the ventral aspect of urethra. If the distal urethra is strictured the flip flap is extended to the radix of the penis in order to cover ventral aspects of both fistula and distal urethra. The flip flap is turned over to cover the ventral aspect of the urethra (Fig. 1c) The edges of the flap is sutured to the edges of the fistula with 6-0 absorbable suture material. The skin on both sides of the fistula is then undermined and sutured on the midline (Fig. 1d).

### RESULTS

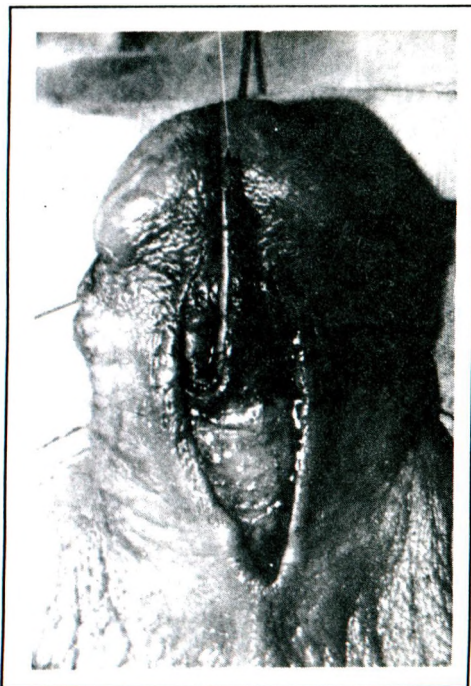
The segment of urethra distal to the fistulas were strictured in most of the patients so they required either reconstruction of the distal urethra with an extended flip flap or dilatation of the urethra for a long time after the operation. We have followed our patients for 6 to 8 months. 5 of the 7 fistulas were closed completely. In 2 of the patients fistulas recurred, but diameters of the fistulas were reduced remarkably.



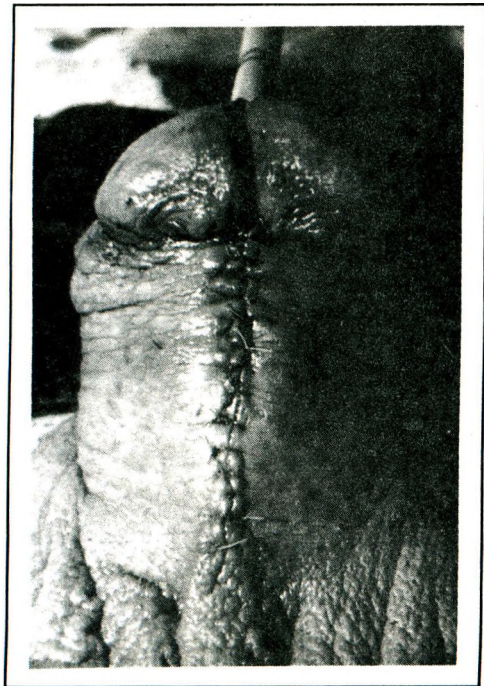
1a. Appearance of a large urethral fistula appeared after the unsuccessful correction of mid penile hypospadias.



1b. A flip flap based on the proximal border of the fistula is elevated.



1c. The flap is hinged on the fistula.



1d. The second layer closure is completed on the midline.

## DISCUSSION

Although the literature contains numerous articles concerning hypospadias repair and about the complications of this operation, relatively less have been written on the management of urethral fistulas. Davis (6) and Fatah (7) advocated the use of different modifications of purse-string suture first suggested by Diffenbach for closure of urethral fistulas. Cecil (8) sutured the penis into a bed prepared on the scrotum for closure of the urethral fistula. Culp (9) and Malament (10) have reported good success with this two-stage operation. Blandy (11) claimed that in fistulas proximal to strictures dilatation of the associated stricture is enough for the spontaneous closure of the fistula. Saad (12) repaired urethral fistula by V-Y advancement flaps designed on the ventral aspect of the penile skin. Horton (5) classified the acquired fistulas of the urethra as early fistulas, mature single fistulas, chronic, multiple large lesions and severe surgical cripples and advocated the use of different modes of treatment for each group. He used a local turnover flap based on the fistula edge to reconstruct the urethral wall and a large flap as the second layer in mature large fistulas. Roberts (13) reported his experience with a local flap which he had used with 95% success.

Although recurrence rates observed after these repairs differ from one report to another a fact is approved by most of these surgeons dealing with urethral fistulas; superimposition of the urethral and skin suture lines almost always ends up in recurrence of the fistula. The flip flap procedure has long been used successfully for correction of distal penile hypospadias. We also use flip flap procedure for distal penile hypospadias cases unexceptionally. The successful results that we have obtained in a great majority of our cases inspired us the application of this procedure for moderate to large urethral fistulas. We have not observed any serious difficulties, such as scarring of the surrounding tissues or tension on suture lines in elevation of the flaps and closure of their donor sites. The time elapsed between the primary correction of the hypospadias and fistula repair was long enough in all cases for maturation of the scars and relaxation of the surrounding skin, so that we closed the donor site of the flap with little tension even in our two cases on which we had

applied flip flap procedure in the previous operation. In our opinion flip flap procedure fulfills the requirements of an ideal flap for closure of an urethral fistula for the following reasons.

- It provides a two layer closure
- It brings new tissue on to the fistula
- Suture lines are not over each other
- There is little or no tension on suture lines

## REFERENCES

1. Culp OS. *Experiences with 200 hypospadiacs. Surg Clin North Am* 1959;39:1007-1014.
2. Wray RC, Ribaudo JM, Weeks PM. *The Byars hypospadias repair a review of 253 consecutive patients. Plast Reconstr Surg* 1976;58:329-331.
3. Van der Meulen JCH. *The correction of hypospadias. Plast Reconstr Surg* 1977; 59:206-215.
4. Dvir E. *The repair of penile hypospadias by the van der Meulen Technique. Eur J Plast Surg.* 1987; 10: 99-102.
5. Horton CE, Devine CJ, Graham JK. *Fistulas of the penile urethra. Plast Reconstr Surg* 1980; 66:407-418.
6. Davis DM. *The pedicled tube-graft in the surgical treatment of hypospadias in the male with new method of closing small urethral fistulas. Surg Gyn Obs* 1940; 71:790-796.
7. Fatah MF. *A method of closing urethral fistulae using a purse-string or interrupted silk sutures. Br J Plast Surg* 1982; 35:102-103.
8. Cecil AB. *Repair of hypospadias and urethral fistula. J Urol* 1946; 56:237-242.
9. Culp OS. *Struggles and triumphs with hypospadias and associated anomalies: Review of 400 cases. J Urol* 1966; 96: 339-352.
10. Malament M. *Repair of the recurrent fistula of the penile urethra. J Urol* 1971; 106:704-708.
11. Blandy JP, Singh M. *Fistulae involving the adult male urethra. Br J Urol* 1972; 44:632-636.
12. Saad MN, Khoo CTK, Lochaitis AS. *A simple technique for repair of urethral fistulae by V-Y advancement. Br J Plast Surg* 1980; 33:410-413.
13. Roberts AHN. *A new operation for the repair of hypospadias fistulae. Br J Plast Surg* 1982; 35:384-386.