

# Morphometric analysis of middle and posterior cranial fossae foramina in 3D reconstructions of CT images: A midline asymmetry evaluation

Ural VERIMLI<sup>1</sup>, Onur BUGDAYCI<sup>2</sup>, Sercan Dogukan YILDIZ<sup>3</sup>, Emrah OZKILIC<sup>4</sup>, Nural BEKIROGLU<sup>5</sup>, Omer OZDOGMUS<sup>1</sup>

<sup>1</sup> Department of Anatomy, School of Medicine, Marmara University, Istanbul, Turkey.

<sup>2</sup> Department of Radiology, School of Medicine, Marmara University, Istanbul, Turkey.

<sup>3</sup> Basic Sciences, School of Dentistry, Istanbul Kent University, Istanbul, Turkey.

<sup>4</sup> Emergency Medicine, Tuzla State Hospital, Istanbul, Turkey.

<sup>5</sup> Department of Biostatistics, School of Medicine, Marmara University, Istanbul, Turkey.

**Corresponding Author:** Ural VERIMLI

**E-mail:** ural.verimli@marmara.edu.tr

**Submitted:** 27.08.2021

**Accepted:** 11.11.2021

## ABSTRACT

**Objective:** The cranial base harbours numerous foramina, and the anatomical properties of the foramina are crucial in clinical interventions. The purpose of the current study is to evaluate possible asymmetries regarding the middle and posterior cranial fossae foramina using 3D reconstructions of high-resolution computed tomography (CT) images.

**Patients and Methods:** High-resolution cranial CT images of 253 female and 287 male adult patients were used in the study. The patients were 18 to 40 years of age without any apparent cranial pathology. The distances from the foramen rotundum, foramen ovale, foramen spinosum, internal acoustic meatus, hypoglossal canal to the midline were measured bilaterally to compare both sides.

**Results:** The foramen spinosum and the mid-clival line measurements demonstrated statistically significant results favoring the right side ( $p=0.03$ , right mean  $3.052 \pm 0.253$  cm, left mean  $2.982 \pm 0.193$  cm). In males, the right foramen spinosum to mid-clival line measurements were significantly longer than the left side ( $p=0.027$ , right mean  $3.150 \pm 0.250$  cm, left mean  $3.070 \pm 0.180$  cm).

**Conclusion:** As predicted, the male measurements were significantly longer than the female measurements regardless of sides in all measurements. The measurements of cranial asymmetries may help describe anomalies and may contribute to the clinical approaches.

**Keywords:** Asymmetry, Computed tomography, Cranial fossa, Foramen, Midline

## 1. INTRODUCTION

Asymmetry has long been a topic of interest among many disciplines and there are different views in the literature regarding the concept of symmetry in the human body. Some researchers state that asymmetry is diverse, but according to some, there is apparent lateralization [1].

Although, the human skull is generally assumed as symmetric, asymmetry of the human skull base is an expected and a very common finding observed in morphometric measurement studies [2]. Environmental and genetic factors, and certain pathologies may affect the developmental entities and cause dissimilarities in the right and left measurements [3]. According to the studies performed on cephalometric X-ray graphies, the right side of the skull is observed larger than the left side. This difference is assumed to be due to the developmental properties of the human brain [2]. Accordingly, it is very crucial and yet very hard to understand whether the asymmetry is abnormal or is within normal limits [3].

Certain asymmetries may affect the anatomical structure of the skull base accommodating the foramina through which prominent neurovascular structures enter or exit the skull [4,5]. Since, the middle cranial fossa articulates with the bony framework of the face, these corresponding structures may influence each other reciprocally in means of developmental morphology [6].

The structural relationship among the skull base foramina is crucial in identifying certain pathologies, evaluating neurological disorders, and performing skull base surgical interventions [4,5,7,8,9]. For instance, detailed information concerning the foramen ovale (FO) and the foramen spinosum (FS) is significant in identifying nasopharyngeal and middle cranial fossa lesions such as abnormal enlargements in the foramen ovale may suggest trigeminal neurinomas [10,11].

The foramen spinosum has also been a widely studied structure since it permits the passage of the middle meningeal artery,

**How to cite this article:** Verimli U, Bugdayci O, Yildiz S D, Ozkilic E, Bekiroglu N, Ozdogmus O. Morphometric analysis of middle and posterior cranial fossae foramina in 3D reconstructions of CT images: A midline asymmetry evaluation. *Marmara Med J* 2022; 35(1):42-47. doi: 10.5472/marumj.1057384

which is used as a bypass graft material in the internal carotid artery and the posterior cerebral artery interventions [12,13].

The posterior cranial fossa harbours the petroclival region and important foramina, therefore it has been of utmost importance for certain neurological interventions [14]. The trans-sphenoidal, anterior, lateral, presigmoidal, retrosigmoidal and the transcondylar approaches require detailed structural knowledge concerning the region [15,16].

Finally, the gender difference among the measurements is also valuable for forensic sciences, anthropology, and archaeology [7]. This study aims to identify possible asymmetries and gender differences in the middle and posterior cranial fossae foramina and provide normative data in the population using high-resolution computed tomography (CT) images obtained from the Turkish population in our institution.

## 2. MATERIALS and METHODS

The study was approved by the Ethics Committee for Clinical Research of Marmara University, School of Medicine with the protocol number 09.2019.477. Patient information remained confidential and solely used for scientific purposes.

The images used in the study were obtained from the School of Medicine Department of Radiology. High-resolution cranial CT images of 253 female and 287 male Caucasian adult patients who were referred to the Department of Radiology from October 2019 to February 2020 were taken into consideration.

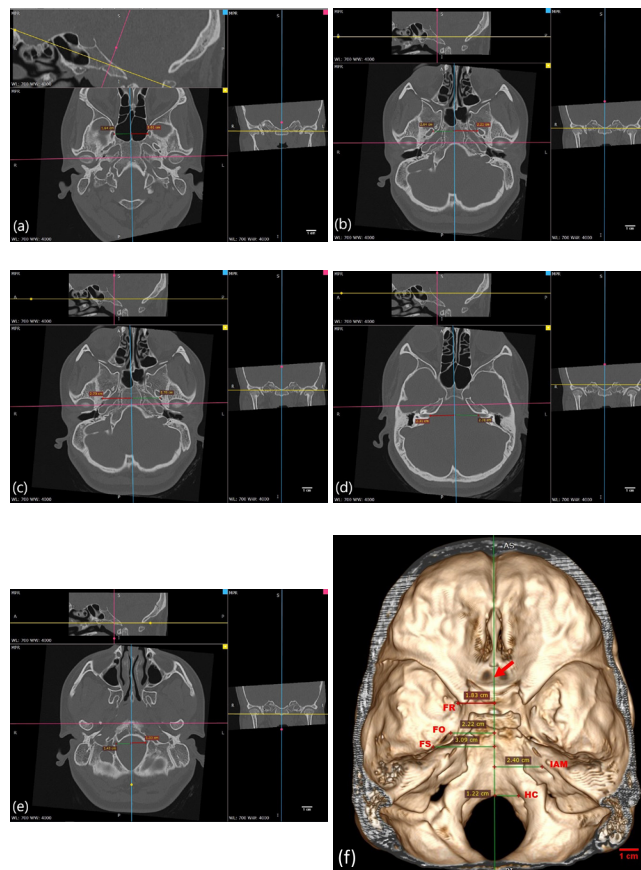
The images were chosen from the thin section cases referred from various clinics to rule out cranial pathologies. The patients were 18 to 40 years of age without any apparent cranial pathology. The mean age was  $28.25 \pm 0.8256$  for the male patients and  $30.36 \pm 0.8088$  for the females.

Imaging was performed on a 256 channel (2x128) Multidetector Computed Tomography Scanner (Somatom Definition Flash, Siemens Healthcare; Erlangen, Germany). Images were obtained in the axial plane with 0.6 mm collimation and 120 kVp (kilovolt peak). mAs (milliamperes per second) were adjusted for each patient via tube current modulation.

After the scan, high-resolution images (0.6 mm slice thickness) were reconstructed in sagittal and coronal planes. The images were evaluated utilizing RadiAnt Dicom Viewer 4.2.1 free version. The images were transferred to the software and 3D multiplanar reconstruction (MPR) was applied to the images. In 3D MPR reconstructions, tilt corrections were made to achieve a true positioning in sagittal, coronal, and axial axes.

The calvariae of the images, cervical vertebrae in the scanning area, together with excessive lateral areas of the skull were removed to enhance the measuring process in 3D measurements. MPR measurements were used to confirm the consistency of the 3D data. The mid-clival line passing through the basion and the mid-point of the dorsum sella was marked as the midline [14,17,18]. The distances between the medial rims of the foramen rotundum (FR), FO, FS, internal acoustic meatus (IAM), hypoglossal canal (HC), and the mid-clival midline

reference were measured bilaterally to compare both sides (Figure 1). All measurements were performed randomly by the same expert investigator for the right and left sides.



**Figure 1** a. Bilateral foramen rotundum to the midline measurement sample in axial sections of multiplanar reconstruction. Coronal and sagittal sections were included to demonstrate the tilt correction. The blue line represents the midline.  
 b. Bilateral foramen ovale to the midline measurement sample in axial sections of multiplanar reconstruction. Coronal and sagittal sections were included to demonstrate the tilt correction. The blue line represents the midline.  
 c. Bilateral foramen spinosum to the midline measurement sample in axial sections of multiplanar reconstruction. Coronal and sagittal sections were included to demonstrate the tilt correction. The blue line represents the midline.  
 d. Bilateral internal acoustic meatus to the midline measurement sample in axial sections of multiplanar reconstruction. Coronal and sagittal sections were included to demonstrate the tilt correction. The blue line represents the midline.  
 e. Bilateral hypoglossal canal to the midline measurement sample in axial sections of multiplanar reconstruction. Coronal and sagittal sections were included to demonstrate the tilt correction. The blue line represents the midline.  
 f. A measurement sample of the cranial fossae foramina to the midline in the 3D reconstruction of high-resolution CT images. The red arrow represents the midline,

### Statistical Analysis

Statistical Package for the Social Sciences version 15.0 was used for the statistical analysis of the data. Assumption of normality was tested using the Kolmogorov-Smirnov test and the mean comparisons of the independent groups were tested via unpaired t-test. The Pearson correlation coefficient was calculated and the correlation among the data was tested.  $P < 0.05$  was accepted to be significant.

### 3. RESULTS

The comparison of gender measurements regardless of sides was found to be longer in the males than the females as expected. Regardless of the gender difference, side comparisons of the FR, FO, HC, and the IAM to the midline reference measurements were statistically insignificant. However, when the FS and the midline reference measurements were taken into account, the comparison

demonstrated statistically significant results favoring the right side shown in Table I ( $p = 0.03$ , right mean  $3.052 \pm 0.253$  cm, left mean  $2.982 \pm 0.193$  cm).

In females, all measurements of the related structures were compared in means of side differences, and no statistical significance was found. When the right side measurements were compared among the genders, FS, IAM, FR and FO measurements were statistically significant, favoring the male measurements ( $p < 0.0001$  for FS and IAM;  $p = 0.027$  for FR;  $p = 0.017$  for FO), but HC measurements were not significant. For the left side comparison among the genders FO, FS, HC and IAM measurements were longer in males ( $p < 0.0001$  for FO, FS and IAM;  $p = 0.015$  for HC), but FR measurements failed to demonstrate statistical significance (Table I). The right FS to midline measurements in males were significantly longer than the left side ( $p = 0.027$ ) (Table I). When the general correlation is considered, all variables demonstrated a linear but poor relationship.

**Table I.** Mean distances measured from the medial rims of the foramina to the midline

	Foramen Rotundum		Foramen Ovale		Foramen Spinosum		Hypoglossal Canal		Internal Acoustic Meatus	
	Mean $\pm$ SD (cm)	Significance	Mean $\pm$ SD (cm)	Significance	Mean $\pm$ SD (cm)	Significance	Mean $\pm$ SD (cm)	Significance	Mean $\pm$ SD (cm)	Significance
<b>Female (n= 110)</b>	1.640 $\pm$ 0.271	0.005**	2.211 $\pm$ 0.163	<0.0001**	2.911 $\pm$ 0.172	<0.0001**	1.401 $\pm$ 0.160	0.004**	2.380 $\pm$ 0.290	<0.0001**
<b>Male (n= 128)</b>	1.741 $\pm$ 0.292		2.310 $\pm$ 0.192		3.110 $\pm$ 0.221		1.460 $\pm$ 0.162		2.661 $\pm$ 0.292	
<b>Right (n= 119)</b>	1.682 $\pm$ 0.271	0.418	2.281 $\pm$ 0.182	0.241	3.052 $\pm$ 0.253	0.03*	1.453 $\pm$ 0.172	0.069	2.563 $\pm$ 0.341	0.237
<b>Left (n= 119)</b>	1.711 $\pm$ 0.293		2.253 $\pm$ 0.191		2.982 $\pm$ 0.193		1.412 $\pm$ 0.151		2.512 $\pm$ 0.311	
<b>Female - Right (n= 55)</b>	1.621 $\pm$ 0.261	0.027*	2.241 $\pm$ 0.171	0.017*	2.931 $\pm$ 0.190	<0.0001**	1.423 $\pm$ 0.178	0.085	2.390 $\pm$ 0.272	<0.0001**
<b>Male - Right (n= 64)</b>	1.730 $\pm$ 0.272		2.320 $\pm$ 0.182		3.150 $\pm$ 0.250		1.474 $\pm$ 0.172		2.701 $\pm$ 0.330	
<b>Female - Left (n= 55)</b>	1.662 $\pm$ 0.273	0.081	2.180 $\pm$ 0.151	<0.0001**	2.890 $\pm$ 0.151	<0.0001**	1.371 $\pm$ 0.140	0.015*	2.371 $\pm$ 0.322	<0.0001**
<b>Male - Left (n= 64)</b>	1.751 $\pm$ 0.312		2.310 $\pm$ 0.202		3.070 $\pm$ 0.180		1.440 $\pm$ 0.152		2.622 $\pm$ 0.256	
<b>Female - Right (n= 55)</b>	1.621 $\pm$ 0.261	0.442	2.241 $\pm$ 0.171	0.094	2.931 $\pm$ 0.190	0.295	1.423 $\pm$ 0.178	0.143	2.390 $\pm$ 0.272	0.743
<b>Female - Left (n= 55)</b>	1.662 $\pm$ 0.273		2.180 $\pm$ 0.151		2.890 $\pm$ 0.151		1.371 $\pm$ 0.140		2.371 $\pm$ 0.322	
<b>Male - Right (n= 64)</b>	1.730 $\pm$ 0.272	0.674	2.320 $\pm$ 0.182	0.815	3.150 $\pm$ 0.250	0.027*	1.474 $\pm$ 0.172	0.249	2.701 $\pm$ 0.330	0.142
<b>Male - Left (n= 64)</b>	1.751 $\pm$ 0.312		2.310 $\pm$ 0.202		3.070 $\pm$ 0.180		1.440 $\pm$ 0.152		2.622 $\pm$ 0.256	

\* Significance at  $p < 0.05$

\*\* Significance at  $p \leq 0.005$

**Table II.** Comparison of the mean measurements in the literature to the current study

Authors	Lang et al. [23]	Sharma and Garud [18]	Sharma and Garud [19]	Unver Doğan et al. [26]	Somesh et al. (2015)	Chen et al. [31]	Mohebbi et al. [29]	Current Study
Research material	Dry skulls	Dry skulls	Dry skulls	Dry skulls	Dry skulls	CT Angiography Images	CT Images (3 mm slice thickness)	CT Images (0.6 mm slice thickness)
Reference point for Foramina	Center of foramen	Medial rim	Medial rim	Medial rim	Center of foramen	Medial rim	Medial rim	Medial rim
Right FR to ML Distance				1.799 ± 0.259 cm		1.751 ± 0.151 cm	1.900 ± 0.207 cm	1.682 ± 0.271 cm
Left FR to ML Distance				1.853 ± 0.241 cm		1.732 ± 0.144 cm	1.934 ± 0.217 cm	1.711 ± 0.293 cm
Right FO to ML Distance		2.213 cm		2.258 ± 0.299 cm				2.281 ± 0.182 cm
Left FO to ML Distance		2.171 cm		2.215 ± 0.241 cm				2.253 ± 0.191 cm
Right FS to ML Distance	2.808 cm	2.853 cm		2.861 ± 0.296 cm	3.039 ± 0.179 cm			3.052 ± 0.253 cm
Left FS to ML Distance	2.976 cm	2.813 cm		2.847 ± 0.297 cm	3.086 ± 0.15 cm			2.982 ± 0.193 cm
Right IAM to ML Distance								2.563 ± 0.341 cm
Left IAM to ML Distance								2.512 ± 0.311 cm
Right HC to ML Distance			1.680 cm					1.453 ± 0.172 cm
Left HC to ML Distance			1.668 cm					1.412 ± 0.151 cm

FO: Foramen ovale, FR: Foramen rotundum, FS: Foramen spinosum, HC: Hypoglossal canal, IAM: Internal acoustic meatus, ML: midline

#### 4. DISCUSSION

Briefly, the current results demonstrate that the FS to midline measurements reveal statistical significance favoring the right side in gender-neutral comparison and in the male population but not in the female group in regards to asymmetry. In contrast to the general assumption, the left side comparison of the FR and the right side comparison of the HC among the gender groups were statistically insignificant. Some of the current results were in concordance with the literature but some were not, where the literature in itself, is mainly insufficient in providing consistent data concerning the skull base asymmetries [21].

Asymmetry is generally observed in the skull base due to its close relationship with the developing neurological structures [2]. Cranial asymmetries without any pathological conditions and functional anomalies should be taken into consideration since they may be of importance to prevent certain malpractice cases [20].

Generally, the studies concerning the cranial fossa foramina to the midline measurements were performed on dry skulls [23-28] and they provided limited results for they were restricted to a single structure, lacking to provide a collective measurement perspective to several foramina. Additionally, only one study used adult CT images for the measurements, again dealing with a restricted set of structures measured, utilizing 3 mm slice thickness. In the current study, the image resolution was higher, therefore, image reconstruction quality was more precise with

the slice thickness of 0.6 mm. In terms of the measurement landmarks, five of these studies measured the midline distance from the medial rims of the foramina, two of them from the centers of the foramina and one did not specify the measurement landmark of the foramina. In the current study, medial rims of the foramina were used as the foraminal landmark.

The mid-region of the cranial base is structurally more stable than the lateral regions [20]. Especially the regions containing FS, stylomastoid foramen, and the foramen magnum are not generally susceptible to symmetry changes [22], but in the current study, the results demonstrated significantly longer measurements on the right FS in gender-neutral comparison and in male population right and left side comparison (Table 1). This finding may contribute to the interventions in the mid-region of the cranial base, especially in FS where asymmetry is not prominently expected.

In another study, conducted in dry human skulls, the distances of the FO and the FS to the midline were found shorter to the left side when compared to the right [23]. In the current study, both right and left FO measurements to the midline were very similar with longer measurements on the right side without a statistical significance. Regarding the FS measurements in the current study, the right side measurements were longer in males with a statistical significance, whereas in females, there were no significant results. Table II demonstrates a comprehensive comparison of the literature together with the current study.

The studies concerning the skulls may provide accurate measurements in means of demonstrating physical distance. However, the devices used in the measurements may not reach or fit the reference points or they may damage the bony structure. Our measurements which are conducted in 3D high-resolution CT reconstruction images do not represent the physical distance but they are superior in demonstrating asymmetries due to the ease of referencing measurement landmarks. Furthermore, the current measurements may be superior to dry skull measurements because high-resolution radiological images represent the living tissue since dry skull structures may be damaged due to the natural progressions and clinical cases require radiological imaging of the skull base region for preoperative evaluation.

Measurement data and asymmetry information may also be very important in identifying occult pathologies since larger than expected asymmetries may be the only finding encountered in these cases such as cystic adenoid carcinoma, which may cause osteolytic lesions may affect the foramina of the skull base [30,31].

### Conclusion

The skull base is very complicated in means of its structural and numerous foramina content. The variations concerning the region are substantial in the interventions of the area [19]. Presumably, the measurements of cranial asymmetries may help describe anomalies encountered in radiological evaluations and may contribute to the surgical interventions related to the region. The current study is the first to comprehensively demonstrate the middle and posterior cranial fossae foramina to the midline measurements in 3D reconstructions of high-resolution CT images.

### Compliance with the Ethical Standards

**Ethical Approval:** The study was approved by the Clinical Research Ethics Committee of Marmara University, School of Medicine, Istanbul with the protocol number 09.2019.477. The study was conducted in accordance with the principles of the Declaration of Helsinki.

**Financial Support:** The authors have no relevant financial information to close.

**Conflict of Interest:** The authors have no potential conflicts of interest to disclose

**Author Contributions:** UV: Study conception, design, data analysis, interpretation of results, draft manuscript preparation, OB: Design, data analysis, SDY: Data gathering and analysis, EO: Data gathering and analysis, NB: Data analysis, statistical analysis, and design, OO: Study conception, design, interpretation of results. All authors reviewed the results and approved the final version of the manuscript.

### REFERENCES

- [1] Teul I, Czerwiński F, Gawlikowska A, Konstany-Kurkiewicz V, Sławiński G. Asymmetry of the ovale and spinous foramina in mediaeval and contemporary skulls in radiological examinations. *Folia Morphol (Praha)* 2002;61:147-52.
- [2] Shah SM, Joshi MR. An assessment of asymmetry in the normal craniofacial complex. *Angle Orthod* 1978;48:141-8. doi: 10.1043/0003-3219(1978)048<0141:AAOAIT>2.0.CO;2.
- [3] Bishara SE, Burkey PS, Kharouf JG. Dental and facial asymmetries: a review. *Angle Orthod* 1994;64:89-98. doi: 10.1043/0003-3219(1994)064<0089:DAFAAR>2.0.CO;2.
- [4] Khairnar KB, Bhusari PA. An anatomical study on the foramen ovale and the foramen spinosum. *J Clin Diagn Res* 2013;7:427-9. doi: 10.7860/JCDR/2013/4894.2790.
- [5] Di Ieva A, Bruner E, Haider T, et al. Skull base embryology: a multidisciplinary review. *Childs Nerv Syst* 2014;30:991-1000. doi: 10.1007/s00381-014-2411-x.
- [6] Choi JW, Ra YS, Hong SH, et al. Use of distraction osteogenesis to change endocranial morphology in unilateral coronal craniosynostosis patients. *Plast Reconstr Surg* 2010;126:995-1004. doi: 10.1097/PRS.0b013e3181e6c4b7.
- [7] Sandu K, Monnier P, Pasche P. Anatomical landmarks for transnasal endoscopic skull base surgery. *Eur Arch Otorhinolaryngol* 2011;269:171-8. doi: 10.1007/s00405-011-1698-4.
- [8] Marques SR, Ajzen S, D' Ippolito G, Alonso L, Isotani S, Lederman H. Morphometric analysis of the internal auditory canal by computed tomography imaging. *Iran J Radiol* 2012;9:71-8. doi: 10.5812/iranjradiol.7849.
- [9] Rai AL, Gupta N, Rohatgi R. Anatomical variations of foramen spinosum. *Innovative J Med Health Sci* 2012;2:86-8.
- [10] Palacios E, MacGee EE. The radiographic diagnosis of trigeminal neurinomas. *J Neurosurg* 1972;36:153-6. doi: 10.3171/jns.1972.36.2.0153.
- [11] Krayenbuhl N, Isolan GR, Al-Mefty O. The foramen spinosum: a landmark in middle fossa surgery. *Neurosurg Rev* 2008;31:397 – 401. doi: 10.1007/s10143.008.0152-6.
- [12] Ustun ME, Buyukmumcu M, Seker M, Karabulut AK, Uysal II, Ziylan T. Possibility of middle meningeal artery-to-petrous internal carotid artery bypass: an anatomic study. *Skull base* 2004;14:153-6. doi: 10.1055/s-2004-832258.
- [13] Ustun ME, Buyukmumcu M, Ulku CH, Guney O, Salbacak A. Transzygomatic-subtemporal approach for a middle meningeal-to-P2 segment of the posterior cerebral artery bypass: an anatomical and technical study. *Skull base* 2006;16:39-44. doi: 10.1055/s-2006-931622.
- [14] Krmpotić-Nemanić J, Vinter I, Kelovizć Z, Marusić A. Postnatal changes of the clivus. *Ann Anat* 2005;187: 277-80. doi: 10.1016/j.aanat.2004.11.005.
- [15] Oliveira E, Rhoton AL, Peace D. Microsurgical anatomy of the region of the foramen magnum. *Surg Neurol* 1985;24:293-352. doi: 10.1016/0090-3019(85)90042-4.
- [16] Pieper DR, LaRouere M, Jackson IT. Operative management of skull base malignancies: Choosing the appropriate approach. *Neurosurg Focus* 2002;12:1-8. doi: 10.3171/foc.2002.12.5.7.
- [17] Gurdal E, Cakmak YO, Ozdogmus O, et al. Morphometric measurements of the caudal cranial nerves in the petroclival

- region. *J Neurol Surg A Cent Eur Neurosurg* 2007;68:47-49. doi: 10.1055/s-2007-981463.
- [18] Sharma NA, Garud RS. Morphometric evaluation and a report on the aberrations of the foramina in the intermediate region of the human cranial base: A study of an Indian population. *Eur J Anat* 2011;15:140-9.
- [19] Sharma NA, Garud RS. Foramina of the posterior cranial base: a study of adult Indian skulls. *Rev Arg de Anat Clin* 2011;3:89-98.
- [20] Russo PP, Smith RL. Asymmetry of human skull base during growth. *Int J Morphol* 2011;29:1028-32.
- [21] Jain KK, Jain BK. Asymmetry in the skull. *Acta Anat* 1979;104:349-52. doi: 10.1159/000145082.
- [22] Sejrsen B, Jakobsen J, Skovgaard LT, Kjaer I. Growth in the external cranial base evaluated on human dry skulls, using nerve canal openings as references. *Acta Odontol Scand* 1997;55:356-64. doi: 10.3109/000163.59709059200.
- [23] Lang J, Maier R, Schafhauser O. Postnatal enlargement of the foramina rotundum, ovale et spinosum and their topographical changes. *Anat Anz* 1984;156:351 – 87.
- [24] Gupta T, Gupta SK. Original landmarks for intraoperative localization of the foramen ovale a radio-anatomical study. *Surg Radiol Anat* 2012;34:767-72. doi: 10.1007/s00276.011.0846-2.
- [25] Patil J, Kumar N, Mohandas Rao KG, Swamy Ravindra S. The foramen ovale morphometry of sphenoid bone in South Indian population. *J Clin Diagn Res* 2013;7:2668-70. doi: 10.7860/JCDR/2013/7548.3727.
- [26] Unver Dogan N, Fazliogullari Z, Uysal II, Seker M, Karabulut AK. Anatomical examination of the foramen of the middle cranial fossa. *Int J Morphol* 2014;32: 43-8.
- [27] Some MS, Murlimanju BV, Krishnamurthy A, Sridevi HB. An Anatomical Study of foramen spinosum in South Indian dry skulls with its emphasis on morphology and morphometry. *Int J Anat Res* 2015;3:1034-1038.
- [28] Tewari S, Gupta C, Palomar V, Kathur SG. Morphometric Analysis of Foramen Spinosum in South Indian Population. *Acta Med Iran* 2018;56:113-8.
- [29] Mohebbi A, Rajaeih S, Safari M, Omidian P. The sphenoid sinus, foramen rotundum and vidian canal: a radiological study of anatomical relationships. *Braz J Otorhinolaryngol* 2017;83:381-7. doi: 10.1016/j.bjorl.2016.04.013.
- [30] Rossi M, Ribeiro E, Smith R. Craniofacial asymmetry in development: an anatomical study. *Angle Orthod* 2003;73:381-5. doi: 10.1043/0003-3219(2003)073<0381:CAIDAA>2.0.CO;2.
- [31] Chen J, Xiao J. 2015. Morphological study of the pterygoid canal with high-resolution CT. *Int J Clin Exp Med* 2015;8:9484–90.