

A RARE COMPLICATION OF EPIDURAL CATHETERIZATION

(Received 11 January, 1993)

F.Y. Göğüş, M.D.* / M.N. Pamir, M.D. / K.Toker, M.D.*****

- * *Professor, Department of Anesthesiology and Reanimation, Faculty of Medicine, Marmara University, İstanbul, Türkiye.*
- ** *Professor, Department of Neurosurgery, Faculty of Medicine, Marmara University, İstanbul, Türkiye.*
- *** *Associate Professor, Department of Anesthesiology and Reanimation, Faculty of Medicine, Marmara University, İstanbul, Türkiye.*

SUMMARY

In this paper a case report with a rare complication of continuous epidural catheterization for postoperative pain treatment is presented.

Epidural space had been identified by the help of a syringe filled with air. On the 4 th postoperative day, the patient began to complain of a pain on her right thigh. On the CT scan an air bubble at L2-L3 level on the right spinal root was diagnosed. The following week her complaints diminished. After 16 days the patient was discharged without pain.

In conclusion, we have decided that maximum care should be taken not to inject any amount of air into the epidural space during the injection.

Key Words : Postoperative pain treatment, Epidural catheterization, Epidural block, Morphine sulphate, Complication.

INTRODUCTION

The epidural space has been proved useful not only for injection of local anesthetic agents to achieve surgical anesthesia, but also for availability to provide a route for therapy. With all forms of anesthesia complications are inevitable and epidural block is no exception to this. For example, epidural abscess is an extremely rare condition but still a few cases have been reported (1,2). Another complication is strangled catheters (3,4).

In this paper, a case report with a rare complication of continuous lumbar epidural catheterization was presented.

CASE REPORT

A 66 years old woman was scheduled for left total hip replacement because of osteoarthritis. Surgery was performed under general anesthesia and a lumbar epidural catheter was inserted before the cessation of anesthesia. The catheter was placed through a 18 G Tuohy needle under sterile conditions at L4 level. The epidural space had been identified using the loss of resistance technique by the help of a 10 ml syringe filled with air. The catheter was advanced approximately 2 cm cephalad. 3 mg morphine sulphate with 5 cc physiological saline was injected through the catheter when the patient complained of pain. The injection intervals were approximately 9 hours. On the fourth postoperative day, immediately after the last epidural injection the patient began to complain for a severe pain on her right thigh. The patient's physical and neurological examination was normal and for pain relief she was scheduled for TENS. Due to the persistence of the pain neurosurgical consultation was asked for. An air bubble measuring 9x4 mm in diameter at L2-L3 level on the right spinal root where it leaves the foramen was diagnosed on the CT scan (Fig. 1). It was decided that the pain was caused by the pressure by this bubble exerted on the nerve root and she was put under close observation until the bubble was completely resorbed. The following week her complaints gradually diminished. Control CT taken 16 days after the first one revealed that the bubble was completely resorbed (Fig. 2). The patient was discharged.

DISCUSSION

To achieve preoperative analgesia or to treat postoperative pain by the epidural route, the epidural

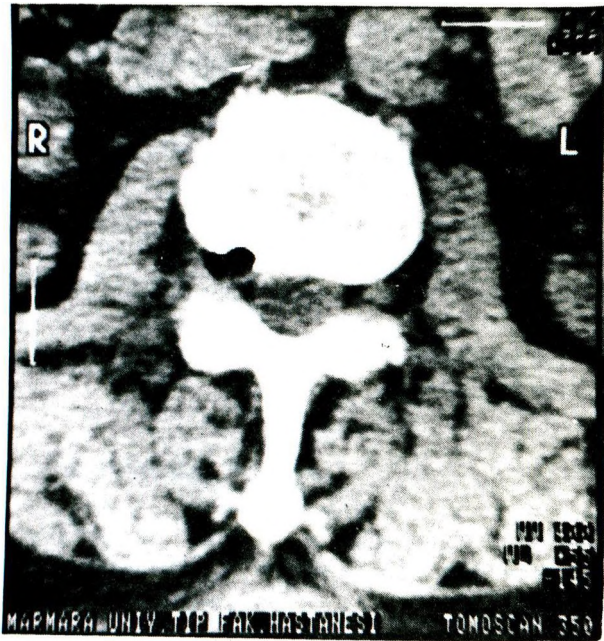


Fig. 1. The air bubble at L2 - L3 level on the right spinal root.

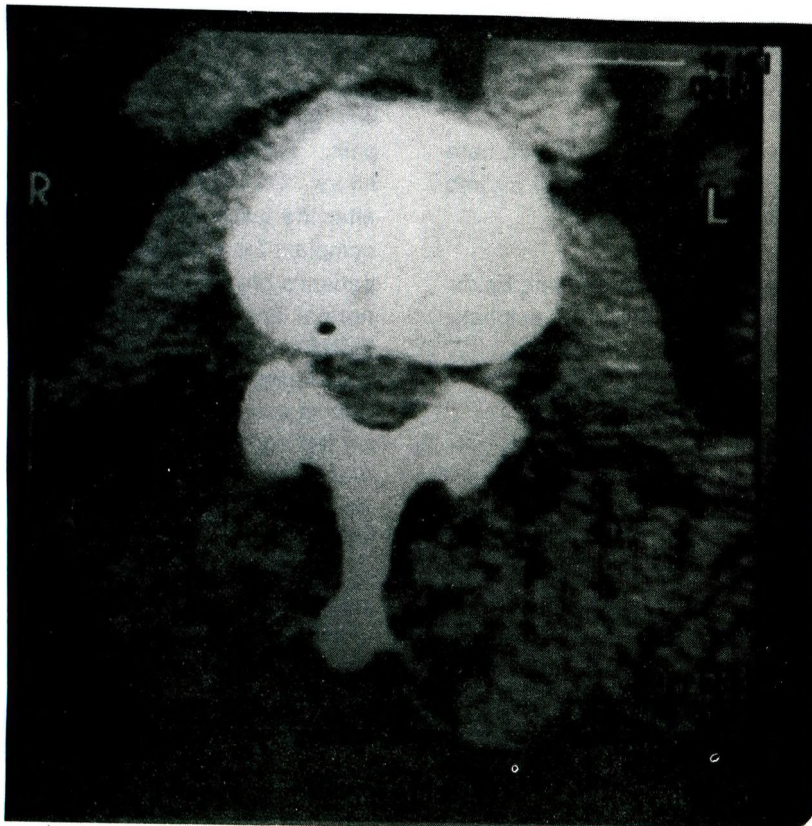


Fig. 2. CT scan of the same level after completely resorption of the air bubble.

space is usually identified by the loss of resistance technique using an air or physiological saline filled syringe. It is obvious that the complication we have observed is very rare and we did not come across a similar report in literature. We think that if the only air injected occurred when the epidural space was located, it would appear that the air should have been absorbed during the four day period. So we have come to a conclusion that, air was injected through the catheter during the last morphine sulphate and physiological saline injection.

In conclusion, we have to say that maximum care should be taken not to inject any amount of air into the epidural space during the injections via an epidural catheter in order to prevent such a hard pain giving complication.

REFERENCES

1. Baker AS, Ojemann RG, Swartz MN, Richardson EP. Spinal epidural abscess. *New England J Med* 1975; 293 : 463 - 468.
2. Saady A. Epidural abscess complicating thoracic epidural analgesia. *Anesthesiology* 1976; 44 : 244 - 246.
3. Bromage PR. *Epidural Analgesia*. Philadelphia : WB Saunders Co, 1978 : 23.
4. Nicholson MJ. Complication associated with use of extradural catheter in obstetric anesthesia. *Anesth Analg* 1965 ; 44 : 245.