

## A CASE OF MERKEL CELL CARCINOMA WITH PAROTID LYMPH NODE METASTASIS

(Received 12 January, 1993)

**Ç. Batman, M.D.\*\* / A.Sav, , M.D.\* / B.Mamıkoğlu, M.D.\*\*\*\*  
C. Üneri, M.D.\*\***

- \* Associate Professor, Department of Pathology, Faculty of Medicine, Marmara University, İstanbul, Türkiye.
- \*\* Associate Professor, Department of Otorhinolaryngology, Faculty of Medicine, Marmara University, İstanbul, Türkiye.
- \*\*\* Assistant Professor, Department of Otorhinolaryngology, Faculty of Medicine, Marmara University, İstanbul, Türkiye.
- \*\*\*\* Research Assistant, Department of Otorhinolaryngology, Faculty of Medicine, Marmara University, İstanbul, Türkiye.

### SUMMARY

We report a case of Merkel cell carcinoma with parotid lymph node metastasis. The pathology, clinical presentation and management of this rare tumor has been discussed.

**Key Words :** Merkel cell carcinoma, Ipsilateral parotid lymph node metastasis.

### INTRODUCTION

Merkel cell carcinoma was described as an unusual skin tumor and up to date more than 300 cases have been reported (1). Most of these carcinomas occur in the elderly with a mean age of sixty to seventy. Approximately fifty percent of the tumors occur in the head and neck region. This tumor typically presents as a rapidly growing, intracutaneous nodule that is firm and non-tender. We report a Merkel cell carcinoma arising in an upper eyelid with ipsilateral parotid lymph node metastasis.

### CASE REPORT

A seventy year old male was seen in the ophthalmology outpatient clinic with a two month history of a 1 cm diameter exophytic growth on his left upper eyelid. The lesion was subsequently excised and interpreted as a Merkel cell carcinoma by histopathologic examination (Fig. 1). Immunohistochemical panel for testing neuron-specific enolase was positive (Fig. 2) in which

leukocyte common antigen (LCA) other than the reactive peritumoral lymphocyte positivity was negative, kappa, lambda, cytokeratin, S-100 reactions were negative. Only individual tumor elements showed focal mild positivity with neurofilament proteins (NFP). The margins of the excised tissue were all negative for tumor infiltration. Postoperative radiotherapy was advised, but the patient refused.

Six months later the patient was admitted to our outpatient clinic because of a 1.5 x 1.5 cm nodule in the region of the left parotid gland. Computerized axial tomography scan (CT) and magnetic resonance imaging (MRI) of the neck at that time were both negative. Following left superficial parotidectomy, histopathologic examination revealed the nodule to be a Merkel cell carcinoma metastasis to a parotid lymph node. Postoperative radiation therapy to the neck was initiated and the patient was disease-free twelve months after completing radiation therapy by both clinical and CT examinations.

### DISCUSSION

Although the exact pathogenesis of Merkel cell carcinoma remains unknown, cutaneous neuroendocrine carcinoma, small cell carcinoma, primary undifferentiated carcinoma, and trabecular carcinoma of the skin have all been used to describe this tumor. Histopathologically, Merkel cell carcinoma cells are typically round to polygonal with abundant, poorly outlined cytoplasm and round, centrally located vesicular nuclei lacking conspicuous nucleoli.

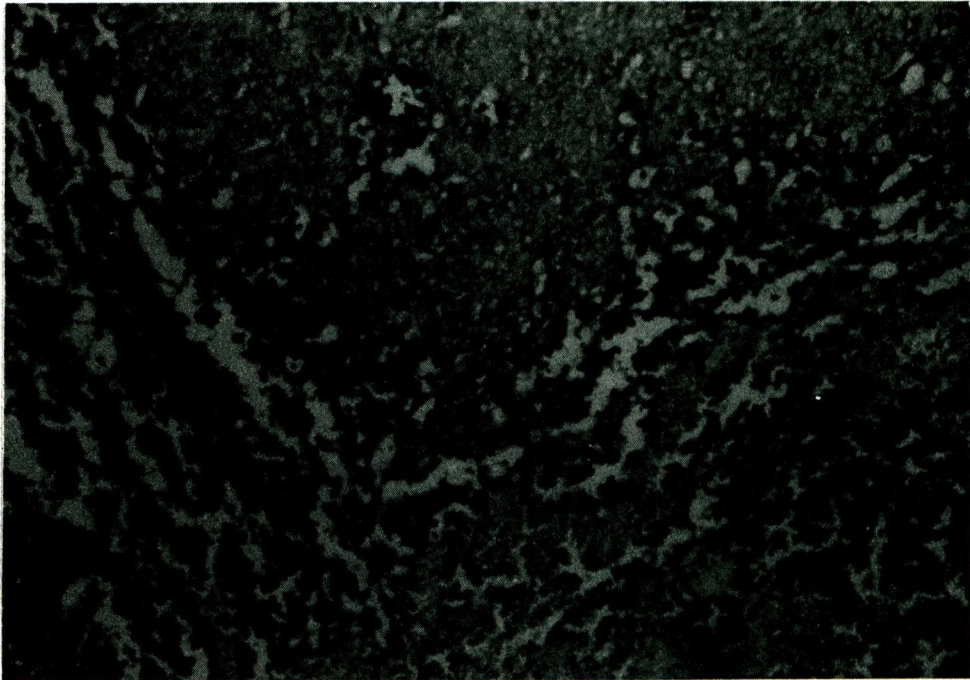


Fig. 1. Tumor tissue showing small undifferentiated elements without any nucleoli, ill-defined cytoplasmic borders. Note the absence of necrotic foci and clear cut delineation from the surrounding tissue. (Hematoxylin-eosin, x 100 original magnification).




Fig. 2. Antibodies directed against neuron-specific enolase showing diffuse positive reaction with tumor cells (Avidin-biotin complement, x 100 original magnification)

Occasional cellular pleomorphism, abundant mitotic figures, and focal necrosis involving individual or small clusters of cells are also seen (2).

For differentiating the Merkel cell carcinomas, it requires an immunohistochemical panel for the accurate diagnosis. High grade lymphomas and metastatic undifferentiated small cell carcinomas should be ruled out.

Immunohistochemically, tumor tissue stains positive for antibody directed against neuron-specific enolase.

Because the Merkel cell is the only cell in the skin that is known to contain neurosecretory granules (containing abundant neuron-specific enolase), these tumors have been named Merkel cell carcinomas. The embryologic origin of the Merkel cell is controversial, and evidence exists suggesting origin from either a neural crest or a transitional cell type in the basal layer of the epidermis (3). These tumors are very aggressive, rapidly growing, and local recurrence occurs almost fifty percent of the time, despite surgical intervention. Lymphatic and hematogenous disseminations are frequent and typically occur simultaneously. Nodal metastases occur in fifty percent of patients. On average, nodal and distant metastases occur eight months after

resection of the primary tumor. Distant metastases, whose occurrence has been suggested as the most important factor predicting survival, are noted in 34% of patients (4).

Surgical therapy should be followed by primary site and regional lymph node irradiation. Prophylactic neck dissection following confirmed diagnosis is controversial, although prophylactic chemotherapy may have merit in preventing distant metastases.

## REFERENCES

1. Toker C. *Trabecular carcinoma of the skin. Arch Dermatol* 1972; 105 : 107 - 110.
2. Andrew J E, Silvers D N, Latters R. *Merkel Cell carcinoma. In : Friedman R, et al, eds. cancer of the skin. W.B. Saunders, 1991 : 288 - 295*
3. Camisa C, Weisman A. *Frederich Sigmund Merkel. Part 2 : The Cell. Am J Dermatopathol* 1982 ; 4 : 527 - 535.
4. Pitale M, Sessions R B, Husain S. *An analysis of prognostic factors in cutaneous neuroendocrine carcinoma. Laryngoscope* 1992; 102 (3) : 244 - 249.