

PANCREATIC HYDATIC CYST

(Received 16 July, 1993)

S.Saydam, M.D.^{*} / H.Bakır, M.D.^{****} / K.Astarçioğlu, M.D.^{*}
D.Özaksoy, M.D.^{****} / A.Küpeliöğlü, M.D.^{**} / M.Karaaslan, M.D.^{*****}**

- * Professor, Department of General Surgery, Faculty of Medicine, Dokuz Eylül University, İzmir, Türkiye.
- ** Associate Professor, Department of Pathology, Faculty of Medicine, Dokuz Eylül University, İzmir, Türkiye.
- *** Assistant Professor, Department of General Surgery, Faculty of Medicine, Dokuz Eylül University, İzmir, Türkiye.
- **** Specialist, Department of Radiology, Faculty of Medicine, Dokuz Eylül University, İzmir, Türkiye.
- ***** Research Assistant, Department of General Surgery, Faculty of Medicine, Dokuz Eylül University, İzmir, Türkiye.

SUMMARY

Hydatid cysts arising from the pancreas are very rarely encountered. Such cysts may often perplex the clinician because they cause symptoms and signs simulating various diseases of this region. Obstructive jaundice due to extrinsic compression of the distal common duct by a hydatid cyst located in the head of pancreas, was found in a 60 year old man. Successful surgical treatment consisted of transduodenal cystoduodenostomy and choledochoduodenostomy. Diagnosis and treatment options for pancreatic hydatid cysts are discussed.

Key Words: Hydatid cyst, obstructive jaundice

INTRODUCTION

True cysts, cystic neoplasms, and parasitic cysts of the pancreas are rare lesions. The clinical and radiologic characteristics, pathologic features, and natural history of any of these type of lesions are not fully documented (1). Pancreatic localization of hydatidosis is exceedingly rare, occurring in 0.5-3.0% of all hydatid cases. Symptoms are variable and the diagnosis is rarely made before surgery (2). Complete collection of epidemiological, clinical, immunofluorescence, and echographic data may allow more accurate pre-operative diagnosis of these lesions (2,3).

CASE REPORT

A 60 year old native of eastern Turkey, where the prevalence of echinococcus is high, was admitted to our hospital for evaluation of 5 months of abdominal pain, jaundice, itching and weight loss. On physical examination we palpated a 5 cm. mass in the right upper quadrant. Laboratory values were; total bilirubin 3.9 mg/dl, direct bilirubin 3.5 mg/dl, SGOT (Serum glutamic oxaloacetic transaminase) 186 U/L, SGPT (serum glutamic pyruvic transpeptidase) 192 U/L, alkaline phosphatase 799 U/L. Ultrasonographic evaluation showed that he had a hydropic gall bladder and 8 cm. diameter cystic mass in the pancreatic head region. The common duct was dilated to

diameter of 12 mm. and his liver was enlarged. By computerized tomography, the encapsulated cyst was found to have a diameter of 10 cm. and the intrahepatic biliary channels were slightly dilated (Fig 1). Pre-operatively this patient was thought most probably to have a pseudocyst because of the obstructive signs. On exploration of the abdomen a dilated common bile duct (20 mm.), and a mass originating from the pancreatic head was found. This mass adhered firmly to the third part of the duodenum.

A clear serous fluid was aspirated from the mass, which was suggestive of hydatid cyst. Then 0.5% silver nitrate was introduced into the cyst to kill the scolices. Because the mass was very large and adherent to the third part of the duodenum, duodenotomy and then cystoduodenostomy was performed. After this procedure because we could not visualize the distal common bile duct with cholangiography, a side to side choledochoduodenostomy was performed. Post-operatively the patient had no problems and has continued to remain asymptomatic 15 months after the surgery. Pathologic examination confirmed our diagnosis of hydatid cyst.

DISCUSSION

Hydatid cysts are most commonly (60%) located in the liver (4). Splenic, renal, cerebral, ocular and osseous hydatids have also been described (4). Hydatidosis in the pancreas occurs in only 0.5-3% of all cases (5-7,3). Hydatid cysts can be found in all regions of the pancreas, and consequently may result in a variety of clinical presentations. Pancreatic tissue adjacent to the cyst shows evidence of congestion and atrophy and can lead to pancreatitis (6,8). If located in the head of the pancreas, obstructive jaundice due to extrinsic compression of the distal part of common bile duct may occur (9). Pinchuk, et al. reported a patient with a hydatid cyst in the pancreatic tail with portal hypertension and gastric varices (4). Making the diagnosis of pancreatic hydatid cyst pre-operatively is very difficult. Complement fixation hemagglutination, latex agglutination and bentonite flocculation tests are available for the general diagnosis of hydatidosis.

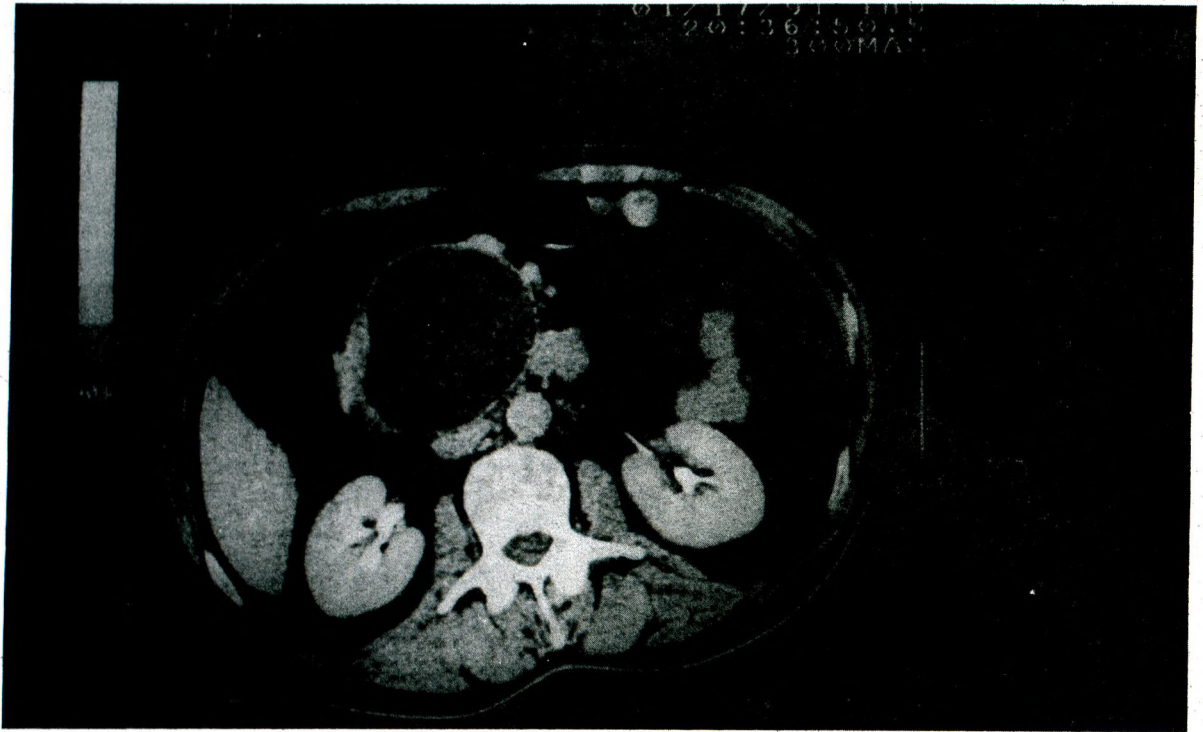


Fig 1. CT scan examination of pancreas after contrast enhancement shows a well defined, thin walled cystic mass in the head of pancreas.

In different case reports, authors reported various surgical procedures for the treatment of pancreatic hydatid cyst. No procedure can be called 'standard'; rather the procedure is selected on the basis of the specific location of the cyst and consequent secondary problems. Some of the recent procedures performed in these patients include external drainage, pancreatic resection and marsupialization. Because of the cyst attachment to the third part of the duodenum, our initial surgical treatment consisted of transduodenal cystoduodenostomy. Excision was felt not to be possible because of the cyst's size and location. Afterwards, an intraoperative cholangiogram was performed and it showed only minimal passage of contrast material to the duodenum. As a result, a choledochoduodenostomy was performed.

REFERENCES

1. Gradinaru V, Seicaru T, Ionescu M, Lotnearu J. Hydatid cyst of the pancreas. *Rev Chir Chir* 1980;29(2):129-133.
2. Lebon J, Baurjeon R, Claude R, et al. Cyste hydatique de la tete du pancreas avec ictere et ouverture du canal de wirsung: conception moderne. *Presse Med* 1957; 65:949.
3. Howard J M. Cystic neoplasms and true cysts of the pancreas. *Surg Clin North Am* 1989;69:651-655.
4. Pinchuk L, Calderon A C, Rubio H. Primary hydatid cyst of the tail of the pancreas, segmental portal hypertension. *Acta Gastroenterol Latinoam* 1980;10(3):203-206.
5. Chifan M, Strat V, Tircoveanu E, Niculescu D, Georgescu S, Dobrescu G, et al. Clinical and therapeutic aspects of some rare forms of pancreatic tumors. *Rev Chir Chir* 1989;38(1):19-26.
6. du Toit D F, Loxton A J, Laker L, et al. Hydatid cyst of the pancreatic tail: A case report. *S Afr Med J* 1984;66:781-782.
7. Golematis B, Feretis C, Strigaris K, et al. Hydatid cyst of pancreas: case report. *Mt Sinal J Med* 1983;50:76-80.
8. Thomas C J. Cestodes (Tape Worms) In: Mendell G L, Dauglas R G, Bennet J E, eds. *Principles and practice of Infectious diseases*. New York: Churchill Livingstone, 1990:2151-2156.
9. Bellakhdar A, Mokhtari M, Kadiri R, Mensouri A, Bouzidi A. Hydatid cyst of pancreas. A propose of 2 case reports. *Acta Chir Belg* 1987;87 (47):225-227.