

## COLOR DOPPLER SONOGRAPHY IN THE DIFFERENTIAL DIAGNOSIS OF OVARIAN MASSES

(Received 27 September, 1994)

**M. Üstün, M.D.\*\* / Ş. Erkıılınç, M.D. \*\*\* / A. Gülkılık, M.D.\*  
N. Solak, M.D.\*\* / E. Erdiř, M.D.\*\***

- \* *Assistant Professor, Department of Obstetrics and Gynecology, Bakırkõy Maternity Hospital, İstanbul, Türkiye.*  
 \*\* *Specialist, Department of Obstetrics and Gynecology, Bakırkõy Maternity Hospital, İstanbul, Türkiye.*  
 \*\*\* *Resident, Department of Obstetrics and Gynecology, Bakırkõy Maternity Hospital, İstanbul, Türkiye.*

### SUMMARY

Color Doppler sonography is a new method that has begun to be used in the screening and early detection of ovarian malignancies. In this study the impedance to blood flow was examined by color Doppler sonography in 28 ovarian masses before exploratory laparotomy. After demonstrating the blood flow spectrum of vessels in the neovascularization area in the mass, the resistance index (RI) was measured.

RI values were compared with the pathology reports of each mass after surgery. In five of the six malignant cases the RI was less than 0.40 (the limit value). All of the 22 benign cases had an RI greater than 0.40. The sensitivity and specificity of the preoperative RI in detecting ovarian malignancy were 83 % and 100 % respectively.

Our results suggest that color Doppler sonography is a useful clinical tool in the preoperative evaluation of ovarian masses.

**Key Words:** Color Doppler Sonography, Ovarian Mass.

### INTRODUCTION

The most common cause of death from gynecological malignancy is a malignant ovarian neoplasm (1). By the time it is detected, disease had spread beyond the ovaries in 70-90% of the cases when detected (2-4).

In view of the discouraging results of treatment for late stage disease, attempts are being made to develop effective screening methods for asymptomatic women in the early stages of disease and to accurately distinguish malignant ovarian masses from the benign ones. CA 125 is used as a marker for nonmucinous ovarian adenocarcinoma (5). The positive and negative predictive values of this marker for ovarian malignancy are generally low, so it is mainly used in the postoperative follow-up of patients undergoing chemotherapy (6,7).

The use of ultrasonography to screen for ovarian cancer was first proposed by Campbell and

colleagues in 1982 (8). Subsequently, in a large prospective trial, transabdominal ultrasound was used to screen over 5000 women for the presence or absence of ovarian pathology (9). This study suggests that, while transabdominal ultrasound is a sensitive technique for the detection of small lesions suggestive of cancer, it is difficult to discriminate between malignant and benign lesions on the basis of B-mode imaging alone. There are now reports on the use of transvaginal ultrasound for the same purpose (10-13). The consensus is that transabdominal and transvaginal ultrasonography are sensitive to first stage screening tests for detecting nearly all ovarian lesions suggestive of malignancy. What is needed is a second-stage test that will discriminate between benign and malignant masses.

Color Doppler sonography is a recent development among the current diagnostic imaging modalities. Several studies have shown the capabilities of transabdominal and transvaginal color Doppler sonography in discriminating between malignant and benign neoplasms (14-17). It is a non-invasive method and can be used in early and late stages of ovarian malignancies.

The purpose of this study was to evaluate the accuracy of color Doppler sonography in predicting the malignancy of ovarian masses.

### MATERIALS AND METHODS

Twenty-eight patients in the study were referred for transabdominal color Doppler sonography after an ovarian mass was identified by conventional transabdominal and transvaginal sonography. The age ranged from 23 to 68 years of age with a mean of 37.7 years.

Examinations were made using a PVF 357 MT 3.75 MHz probe attached to a Toshiba SSA - 270 A scanner. The B-mode was used to evaluate the morphology of both ovaries, and then color flow imaging was superimposed to detect vascularized areas. Finally, pulsed Doppler was used to analyze blood velocity in the area of interest, and the resistance index (RI) was calculated to quantify the impedance to blood flow using the formula (18):

$$RI = \frac{\text{systolic peak} - \text{maximum end-diastolic velocity}}{\text{systolic peak}}$$

Measurements were repeated for at least three separate cardiac cycles.

The lowest resistance index was taken as representative of the mass, and vessels closest to the center of the mass were examined carefully for areas of increased diastolic flow.

Masses examined were removed surgically 1-2 days after color Doppler sonographic examination. The benign or malignant nature of the ovarian mass was confirmed by histopathology.

The sensitivity, specificity and both positive and negative predictive values for detecting malignant ovarian tumors were determined. Chi-square test was also used to compare the RI values of the six histopathologically malignant masses with the 22 benign masses.

## RESULTS

Twenty-two women had benign and six had malignant ovarian tumors by histopathologic examination (Tables I and II).

Neovascularization area was detected sonographically in all of the malignant masses. The RI was less than 0.40 in 5 (80%) of these malignant masses (Figs 1 and 2). RI was 0.58 in the mass that had the histopathological diagnosis of epidermoid carcinoma.

Neovascularization area was detected sonographically in 18 (82%) of the 22 benign masses. The RI was greater than 0.40 in all of these cases (Figure 3).

In general, the average RI of benign ovarian masses (0.76 + 0.08) was statistically different from malignant masses (0.40 + 0.10) (p 0.001).

The sensitivity of color Doppler sonography in detecting ovarian malignancy was 83 % , specificity 100%, positive predictive value 100%, and negative predictive value 95 %.

## DISCUSSION

The concept that tumor growth is restricted in the absence of the vascular response was developed in

**Table I - Color Doppler assessment of benign ovarian masses.**

Histopathology	No.	Neovascularization present	RI
Serous cyst	7	6 (86%)	0.72
Mucinous cyst	2	- -	-
Simple ovarian cyst	1	1 (100%)	0.79
Dermoid cyst	1	1 (100%)	0.80
Fibrothecoma	2	2 (100%)	0.77
Tubo - ovarian abscess	3	3 (100%)	0.80
Endometriosis cyst	4	3 (75%)	0.79
Ectopic pregnancy	2	2 (100%)	0.76
	22	18 (82%)	0.76 + 0.08

**Table II - Color Doppler assessment of malignant ovarian masses.**

Histopathology	No.	Neovascularization present	RI
Adenocarcinoma	3	3 (100%)	0.38
Undifferentiated carcinoma	1	1 (100%)	0.32
Endodermal sinus tumor	1	1 (100%)	0.38
Epidermoid Ca	1	1 (100%)	0.58
	6	6 (100%)	0.40 + 0.02

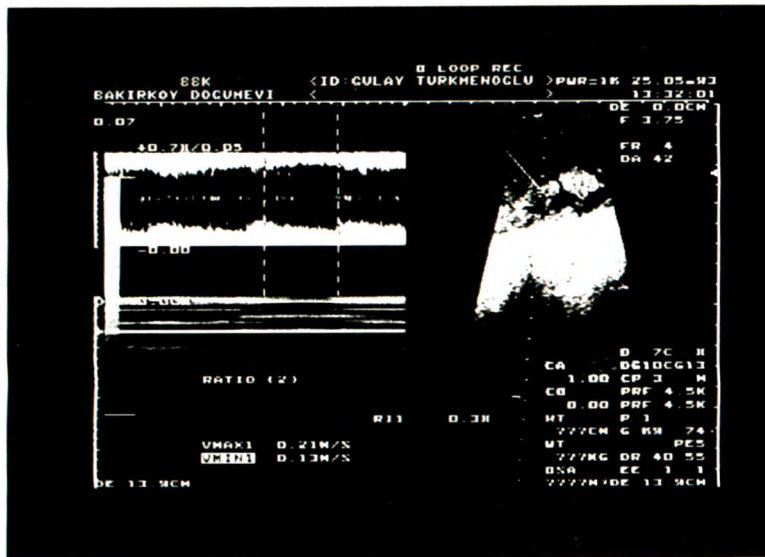


Fig.1. The RI of the vessels at the neovascularization area was measured as 0.38 in this irregular ovarian mass. The histopathological diagnosis was endodermal sinus tumor.

Fig.2. The RI of the vessels on the septa of this ovarian tumor was measured as 0.37. The histopathological diagnosis was mucinous adenocarcinoma.

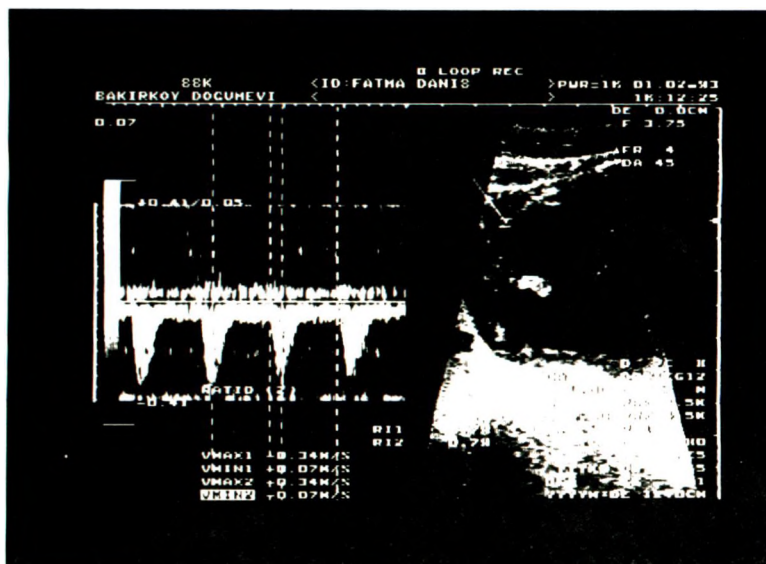
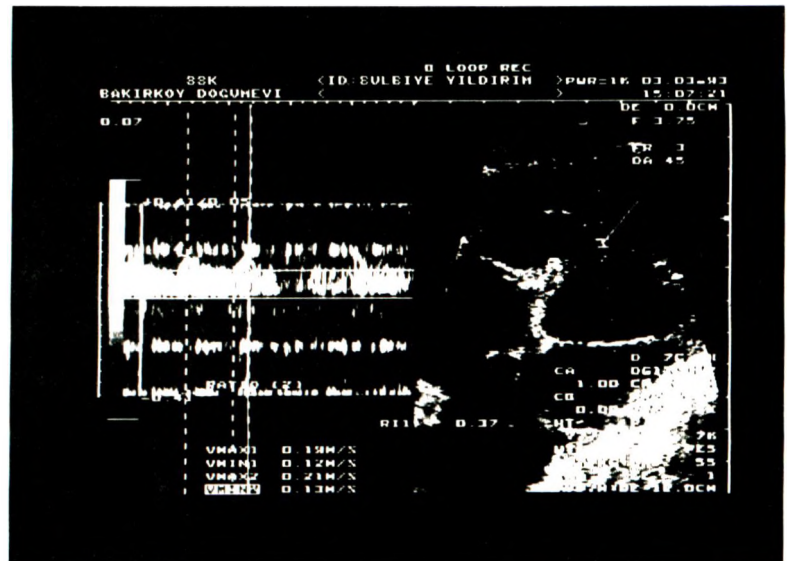


Fig.3. The RI of the vessels of the mass in the right adnexial region was measured as 0.78. The histopathological diagnosis was ectopic pregnancy.



the 1960's (19,20). Studies have shown that viable tumor cells release diffusible angiogenic factors which stimulate new capillary growth and endothelial mitosis in vivo (21,22), even when tumor cell proliferation has been arrested by irradiation (23). Folkman hypothesized that "once tumor take occurs every further increase in tumor cell population must be preceded by an increase in new capillaries which converge upon the tumor" (22).

Tumor induced vessels are often dilated and saccular and may even contain tumor cells within the endothelial lining (24). Tumor microvasculature does not conform to the microvasculature of normal tissues (artery to arteriole to capillary to postcapillary venule to venule to vein) (24). Tumors may contain giant capillaries and arteriovenous shunts without intervening capillaries. Newly formed vessels contain no smooth muscle in their walls, but instead contain only a small amount of fibrous connective tissue (21,25). Since most of the resistance to flow occurs at the level of the muscular arterioles, vessels deficient in these muscular elements offer reduced resistance to blood flow and transmit larger volume flow than vessels with high resistance.

Evaluation of several types of tumors by color Doppler has been reported (14-17, 26). Although there are different opinions about cut-off values, in most of the studies a cut-off point of 0.40 for the resistance index as well as 1.00 for the pulsatility index were established and used as an indicator of malignancy (27-32). All authors agree that recognition of angiogenesis as a reference point for malignant changes within the ovary has proved to be a highly sensitive parameter (15, 16, 27-31).

Kurjak et al studied pelvic masses and observed a low impedance in the intratumoral blood flow (resistance index below 0.41) in malignant ovarian lesions (27). One false positive result (a granulosa cell tumor) among 15 benign cystic masses was found. In benign ovarian masses the RI was always above 0.40.

Bourne et al had similar results. In 18 women with ovarian tumors, 8 cases were malignant (16). The pulsatility index (PI) values of the malignant tumors were below 1.00. One false positive (a dermoid cyst) and one false negative result (a borderline serous cystadenoma) were obtained.

In a later study by Kurjak et al, a larger group of patients were examined (28). Among 680 pelvic masses, 624 benign and 56 malignant ovarian lesions were found. In all but one benign lesions the RI was above 0.40, while the RI was below 0.40 in 54 of 56 malignant lesions.

Weiner et al found the pulsatility index of intraovarian or intratumoral blood vessels to be greater than 1.0 in 35 of 36 benign tumors, and a pulsatility index below 1.0 all malignant cases (32).

Kawai et al suggested a pulsatility index cut-off value of 1.25 (31). This was suggested after the results of 13 benign and 11 malignant lesions were compared.

In our study all of the benign cases had an RI above 0.40. All malignant ovarian masses had an area of neovascularization and the RI values were below 0.40 in 5 of the 6 malignant cases. However, histopathological examination of the sixth case whose RI value was 0.58, revealed that it was an epidermoid carcinoma that has arisen from part of a benign dermoid cyst. It might be that the vessels examined belonged to the benign part of the tumor since neovascularization was not considered present in the epidermoid carcinoma (33, 34). It was speculated that newly formed vessels of the non-advanced epidermoid carcinoma were too small and the velocity and the volume flow were below equipment resolution (33).

We obtained a high sensitivity and specificity (83 % and 100% respectively) in detecting ovarian malignancy by using resistance index values alone and taking 0.40 as the cut-off separating malignancy from non-malignancy. Our study suggests that color Doppler sonography is a useful clinical tool in the preoperative evaluation of ovarian masses.

## REFERENCES

1. Borling C, Squires T, Tang T. *Cancer statistics. Cancer J Clin* 1991; 41: 19-36.
2. Sigurdsson K, Alm P, Qulldberg B. *Prognostic factors in malignant epithelial ovarian tumors. Gynecol Oncol* 1983;15: 370 - 380.
3. Einhorn N, Nilsson B, Sjoval K. *Factors influencing survival in carcinomas of the ovary. Cancer* 1985;55: 2019-2025.
4. Yancik R, Gloeckler RL, Yates JW. *Ovarian cancer in the elderly: an analysis of surveillance, epidemiology, and end results program data. Am J Obstet Gynecol* 1986;154:639-647.
5. Klug TL, Bast RC, Niloff JM, Knapp RC, Zurawski VR. *Monoclonal antibody immunoradiometric assay for antigenic determinant CA 125 associated with human epithelial ovarian carcinoma. Cancer Res* 1984;44:1048-1053.
6. Di-Xia C, Schwartz PE, Xinguo L, Zhan Y. *Evaluation of CA 125 levels in differentiating malignant from benign tumors in patients with pelvic masses. Obstet Gynecol* 1988; 72:23-27.
7. Jacobs IJ, Bast RC. *The CA 125 tumor associated antigen; a review of the literature. Hum Reprod* 1989;4:1.
8. Campbell S, Goessens L, Goswamy R, Whitehead MI. *Real-time ultrasonography for determination of ovarian morphology and volume - a possible new screening test for early ovarian cancer. Lancet* 1982;1:425-426.
9. Campbell S, Bhan V, Royston P, Whitehead MI, Collins WP. *Transabdominal ultrasound screening for early ovarian cancer. Br Med J* 1989;299:1363-1367.
10. Van Nagell JR, Higgins RV, Donaldson ES, Gallon HH. *Transvaginal sonography as a screening method for ovarian cancer: a report of the first 1000 cases screened. Cancer* 1990;65:373-377.
11. Bourne TH, Campbell S, Whitehead MI, Collins WP. *Ultrasound screening for sporadic and familial early ovarian cancer. J Ultrasound Med* 1991;10:43.
12. Andolf E, Svalenius E, Astedt B. *Ultrasonography for early detection of ovarian carcinoma. Br J Obstet Gynecol* 1986; 93:1286-1289.
13. Sassone AM, Tritsch IE, Artner A, Westhoff C,

- Warren WB. Transvaginal sonographic characterization of ovarian disease: evaluation of a new scoring system to predict ovarian malignancy. *Obstet Gynecol* 1991; 78:70.
14. Hata T, Hata K, Yamane Y, Kitao M. Real-time two-dimensional and pulsed Doppler ultrasound detection of intrapelvic neoplastic tumor and abnormal pathogenic changes: preliminary report. *J Cardiovasc Ultrasonog* 1988;7:135.
  15. Fleischer AC, Rogers WH, Rao BK, Kepple DM, Jones HW. Transvaginal color Doppler sonography of ovarian masses with pathological correlation. *Ultrasound Obstet Gynecol* 1991;1:275-278.
  16. Bourne T, Campbell S, Steer C, Whitehead MI, Collins WP. Transvaginal colour flow imaging: a possible new screening technique for ovarian cancer. *Br Med J* 1989; 299: 1367-1371.
  17. Kurjak A, Zalud I. Transvaginal color Doppler imaging and ovarian cancer (Letter). *Br Med J* 1990; 300: 330-334.
  18. Thompson RS, Trudinger BJ, Cook CM. Doppler ultrasound wave analysis: A/B ratio, pulsatility index and Pourcelot ratio. *Br J Obstet Gynaecol* 1988;95:581-588.
  19. Folkman J, Long D, Becker F. Growth and metastasis of tumor in organ culture. *Tumor Res* 1963;16:453-467.
  20. Folkman J, Cole P, Zimmerman S. Tumor behavior in isolated perfused organs: in vitro growth and metastasis of biopsy material in rabbit thyroid and canine intestinal segment. *Ann Surg* 1966; 164:491-502.
  21. Folkman J, Shing Y. Mini review. *J Biol Chem* 1992; 267: 10931-10934.
  22. Folkman J, Melrel E, Abernethy C, Williams G. Isolation of a tumor factor responsible for angiogenesis. *J Exp Med* 1971; 133:275-278.
  23. Auerbach R. Angiogenesis - Inducing factors: a review. In: Pick E, ed. *Lymphokines*. London: Academic Press, 1981:69-88.
  24. Jain RK. Determinants of tumor blood flow. *Cancer Res* 1988;48:2641-2658.
  25. Grammill SL, Shipkey FH, Himmelfarb EH, Parvey LS, Rabinowitz JG. Roentgenology - pathology correlation study of neovascularization. *Am J Radiol* 1976;126:376-385.
  26. Shimamoto K, Sakuma S, Ishigaki T, Makino N. Intratumoral blood flow: Evaluation with color Doppler echography. *Radiology* 1987;165:683-685.
  27. Kurjak A, Zalud I, Jurkovic D, Alfrevic Z, Miljan M. Transvaginal color Doppler for the assessment of pelvic circulation. *Acta Obstet Gynecol Scand* 1989;68:131-134.
  28. Kurjak A, Zalud I, Alfrevic A. Evaluation of adnexal masses with transvaginal color ultrasound. *J Ultrasound Med* 1991;10:295-297.
  29. Kurjak A. Screening for ovarian malignancy by transvaginal color flow mapping. *Ultrasound Obstet Gynecol* 1991; 1 (Suppl 1) : 85.
  30. Fleischer AC, Rodgers WH, Rao BK, Kepple DM, Worrel JA, Williams L. Assessment of ovarian tumor vascularity with transvaginal color Doppler sonography. *J Ultrasound Med* 1991;10:563-568.
  31. Kawai M, Kano T, Kikkawa F, Maeda O, Oguchi H, Tomoda Y. Transvaginal Doppler ultrasound with color flow imaging in the diagnosis of ovarian cancer. *Obstet Gynecol* 1992;79:163-167.
  32. Weiner Z, Thaler I, Beck D, Rottem S, Deutchs M, Brandes JM. Differentiating malignant from benign ovarian tumors with transvaginal color flow imaging. *Obstet Gynecol* 1992;79:159-162.
  33. Hata T, Hata K, Senoh D, Makihara K, Aoki S, Takamiya O. Doppler ultrasound assessment of tumor vascularity in gynecologic disorders. *J Ultrasound Med* 1989;8:309.
  34. Kurjak A, Zalud I. Uterine masses. In: Kurjak A, ed. *Transvaginal Color Doppler*. New Jersey: The Parthenon Publishing Group, 1991:123-135.