

# THE IMPORTANCE OF MOTOR EVOKED POTENTIAL FINDINGS IN ACUTE-SUBACUTE ODONTOID DISLOCATIONS

Amber Eker<sup>1</sup>, Bahar Kaymakamzade<sup>2</sup>, Kubilay Varli<sup>3</sup>

<sup>1</sup> Eastern Mediterranean University Faculty of Medicine, Famagusta, Northern Cyprus

<sup>2</sup> Department of Neurology, Dr. Burhan Nalbantoglu State Hospital, Nicosia, Northern Cyprus

<sup>3</sup> Hacettepe University Faculty of Medicine Department of Neurology, Ankara, Turkey

ORCID: A.E. 0000-0001-9997-4662; B.K. 0000-0001-9495-6203; K.V. 0000-0002-5474-1774

**Corresponding author:** Amber Eker, **E-mail:** amber.eker@emu.edu.tr

**Received:** 09.03.2022; **Accepted:** 12.07.2023; **Available Online Date:** 30.09.2023

©Copyright 2021 by Dokuz Eylül University, Institute of Health Sciences - Available online at <https://dergipark.org.tr/en/pub/jbachs>

**Cite this article as:** Eker A, Kaymakamzade B, Varli K. The Importance of Motor Evoked Potential Findings in Acute-Subacute Odontoid Dislocations. J Basic Clin Health Sci 2023; 7: 188-191.

## ABSTRACT

**Purpose:** Motor-evoked potentials (MEPs) evaluated with transcranial magnetic stimulation (TMS) allow functional evaluation of corticospinal conduction. The aim of this study is to evaluate the value of MEPs for the assessment of spinal cord transmission in clinically minimally symptomatic or asymptomatic patients with acute-subacute odontoid pathologies.

**Material and Methods:** The MEPs were measured from five cases with acute-subacute odontoid dislocations by using TMS. Demographic features, neurological examinations, and neuroimaging findings of the patients have also been recorded.

**Results:** The central motor conduction times (CMCTs) and MEP latencies were prolonged bilaterally in all patients with acute-subacute odontoid dislocation. Additionally, MEP amplitudes were also found to be decreased in all cases.

**Conclusions:** MEP is quite valuable to show involvement in clinically and radiologically silent cases. Our findings in acute-subacute cases without myelopathy showed us that the CMCTs were prolonged especially in the cases who had motor deficits but also in asymptomatic cases.

**Keywords:** motor evoke potentials, odontoid, acute, subacute, electrophysiology, adult

## INTRODUCTION

Magnetic stimulation has been commonly used for the examination of the descending motor pathways. Motor-evoked potentials (MEPs) evaluated with transcranial magnetic stimulation (TMS) allow functional assessment of corticospinal conduction. [1]. In spite of that, there are limited TMS studies focused on acute odontoid pathologies other than common cervical spondylosis. The purpose of this study is to evaluate the value of MEPs in the assessment of dysfunction in spinal cord transmission in acute-subacute odontoid pathologies. Therefore we summarized the clinical, radiological,

and MEP findings of five patients and present the clinical, electrophysiological, and radiological features of a case who underwent surgery.

## MATERIALS AND METHODS

The electrophysiology unit records were reviewed for cases with acute-subacute odontoid dislocations. MEPs have been obtained by TMS. TMS was performed by the MagPro stimulator (Medtronic, Denmark) with a round coil. Cortical stimulation has been applied over the motor cortex at an optimum position for eliciting MEPs. The MEPs were recorded from the abductor digiti minimi (ADM) muscles at rest.

The shortest latencies of motor responses with brain stimulation (central latency–CL) and root stimulation (root latency–RL) and peak-to-peak amplitudes of the largest MEP after cortical stimulation were measured. Central motor conduction time (CMCT) was calculated by subtracting the RL from the CL. Demographic features, neurological examination, and neuroimaging findings of the patients have also been noted.

**RESULTS**

The ages of the patients were between 20-43. All the patients were female. Neurological examination was normal in two patients. Mild weakness in the upper extremities was observed in two of the other patients and hemihypoesthesia in one patient. Neuroimaging based on magnetic resonance imaging (MRI) revealed an odontoid fracture in four out of five, and odontoid pannus-related instability and upward dislocation in one patient. There weren't any intensity changes in the spinal cord in all these acute/subacute cases. (Table 1) The CMCTs and MEP latencies were prolonged bilaterally in all patients with acute-subacute odontoid

dislocation. Additionally, MEP amplitudes were also found to be decreased in all cases. One patient underwent stabilization surgery and the MEP was repeated in the second week after surgery. The most notable change was observed in CMCT. Postoperative calculated CMCT was shorter than the previous one.

**Case presentation:**

A 20-year-old female was admitted to our clinic with the chief complaint of neck and arm pain which started two months ago after she fell down from a height. Her neurological examination revealed bilateral slight weakness in both proximal upper extremities. Motor strength was determined as 4/5 in bilateral arm flexion and abduction. There weren't any Babinski signs and increased deep tendon reflexes. Her cervical spinal MRI showed odontoid Type 2 fracture and posterior dislocation (Figure 1). Electrophysiological assessment (Table 1) showed bilaterally and significantly prolonged CMCT in ADM. Additionally MEP amplitudes, which were obtained after cortical stimulation were reduced (Figure 2). All these findings resemble severe deterioration of

**Table 1.** Clinical, electrophysiological and radiological features of the cases

	Age-Sex	Etiology	Neurologic examination	Stimulus-Record area	Right			Left		
					Latency ms	Amplitude mV	CMCT ms	Latency ms	Amplitude mV	CMCT ms
Case 1	20-F	Odontoid fracture	Motor strength is 4/5 in bilateral upper extremity proximal muscles	C8-ADM	10.6	4.6		11.0	3.9	
				Ctx-ADM	20.5	1.7	9.9	21.6	1.9	10.6
				Postoperative C8-ADM	10.6	2.6		11.0	1.9	
				Postoperative Ctx-ADM	19.4	0.5	8.8	19.7	0.4	8.7
Case 2	43-F	Odontoid pannus dislocation	Right sided hemihypoesthesia	C8-ADM	10.2	8.0		11.0	7.1	
				Ctx-ADM	19.6	1.1	9.4	21.0	0.6	10.0
Case 3	33-F	Odontoid fracture	Normal	C8-ADM	12.3	8.9		12.3	6.9	
				Ctx-ADM	20.8	3.3	8.5	22.2	1.1	9.9
Case 4	43-F	Odontoid fracture	Motor strength is 4/5 in bilateral upper extremity distal muscles	C8-ADM	10.6	8.8		10.6	11.9	
				Ctx-ADM	25.5	0.6	14.9	26.1	0.8	15.5
Case 5	37-F	Odontoid fracture	Normal	C8-ADM	13.5	4.3		13.9	1.9	
				Ctx-ADM	21.8	2.8	8.3	21.8	2.1	7.9

cervical central motor conduction and also probable slight axonal loss in the cervical pyramidal tracts. The patient underwent surgery for cervical stabilization. The MEP investigation was repeated two weeks after the surgery. The investigation revealed a decrease in MEP latencies and CMCTs with cortical stimulation. Besides, the MEPs amplitudes were slightly lower than the former preoperative ones.

**DISCUSSION**

Radiological investigations which are commonly used in the suspected spinal pathologies demonstrate morphological abnormalities of the spine and the spinal cord but not functional impairment. Motor evoke potentials evaluation by TMS is a non-invasive method for assessing descending motor pathway function. MEP is commonly used in a wide range of spinal cord pathologies to localize the lesion and defines the severity of involvement and is accepted as a highly sensitive and reliable test [1,2]. TMS provides objective and quantitative information for motor pathways and can easily be compared across individuals [3]. Results obtained from different studies reveal that CMCT is correlated with clinical findings

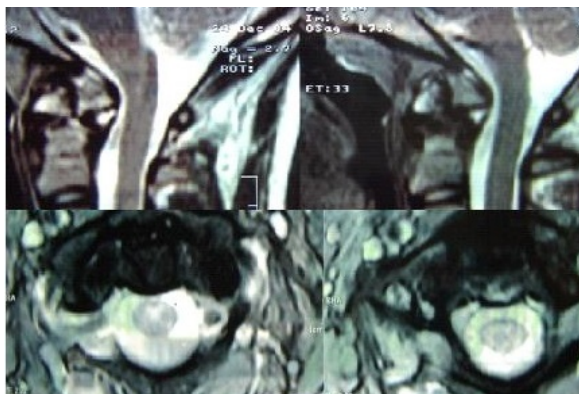
and radiographic parameters [1-5]. MEP is additionally sensitive to exhibiting corticospinal tract involvement which has not already been clinically evident [4].

TMS has some other additional advantages in neurology, neurosurgery, and orthopedic surgery clinics. It really has important advantages by being a quick, easy, and noninvasive test. Furthermore, this test method has also benefited in the evaluation of patients who have difficulty in transportation such as in the setting of trauma [1,6,7]. Additionally, this technic is very helpful to evaluate patients who have coexisting and confusing symptoms and pathologies [1,3].

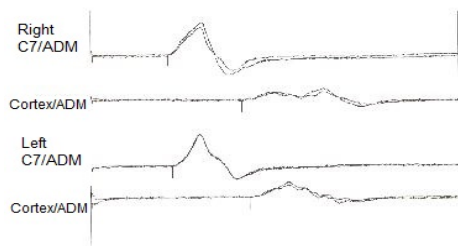
Previous studies have indicated that MEPs might be a valuable tool in the functional assessment of different etiologies including spinal cord disorders, hereditary spastic paraplegia, and motor neuron disorders [4]. TMS mostly has been studied in chronic segmental compression of the spinal cord especially related to common spondylotic changes and disc herniations. It is accepted as a valuable tool in the functional assessment of subclinical cases [1,6,8]. The MEP investigation relevance was also investigated in acute spinal cord injury patients in one study and it revealed the same significance as in chronic cases [6].

Our findings in acute-subacute cases without myelopathy showed us that the CMCTs were prolonged especially in the cases who had motor deficits but also in asymptomatic cases. In addition, the cases who had motor deficits had more prolonged CMCTs. Our results in acute-subacute cases were compatible with the findings of all other research that studied different etiologies. MEP is quite valuable to show involvement in clinically and radiologically silent cases and the severity of dysfunction detected by MEP is correlated with the clinical severity. The main parameter that reflects the involvement of the corticospinal tract is CMCT. Recovery in CMCT can be observed even soon after the surgery for odontoid dislocation.

The clinical manifestations of odontoid dislocation-related pathologies are highly variable, being relatively asymptomatic to unstable with significant neurological deficits [9]. The Type II fractures that are the most common form observed in our patients are traditionally considered unstable and often require immediate surgical stabilization [7,9]. Although neurological assessment can be difficult in patients with unstable odontoid pathologies, MEP is effective



**Figure 1.** Axial and sagittal T2 cervical MRI scenes of case 1.



**Figure 2.** Case 1 bilateral MEPs elicited by TMS

in clarifying the functional situation of the motor pathways.

Odontoid-related pathologies are rare and their electrophysiological features were mainly discussed for the pediatric age groups and intraoperative period in the literature [10]. Our study aims to discuss the value of perioperative electrophysiological evaluation of this rare condition in adult cases.

## CONCLUSION

Early diagnosis and treatment of odontoid pathologies are actually important owing to their critical neighborhood of important areas of the central nervous system. Early diagnosis could be difficult in cases with no or mild clinical symptoms. MEP is a valuable tool for the assessment of functional involvement in these patients.

**Acknowledgments:** None.

**Author contribution:** Study conception and design: AE,BK,KV; data collection: AE, BK, KV; analysis and interpretation of results: AE,BK,KV; draft manuscript preparation: AE,BK ; supervision: KV. All authors reviewed the results and approved the final version of the manuscript

**Conflict of interests:** All the authors represent their consent for publication

**Ethical approval:** The study followed the Declaration of Helsinki Ethical Principles for Medical Research.

**Funding:** None.

**Peer-review:** Externally peer-reviewed.

## REFERENCES

1. Nakamae T, Tanaka N, Nakanishi K, Fujimoto Y, Sasaki H, Kamei N et al. Quantitative assessment of myelopathy patients using motor evoked potentials produced by transcranial magnetic stimulation. *Eur Spine J.* 2010;19(5):685–690.
2. Mut M, Cila A, Varli K, Akalan N. Multilevel myelopathy in Maroteaux-Lamy syndrome and review of the literature. *Clinical Neurology and Neurosurgery.* 2005;107(3):230-235.
3. Mazur MD, White A, McEvoy S, Bisson EF. Transcranial magnetic stimulation of the motor cortex correlates with objective clinical measures in patients with cervical spondylotic myelopathy. *Spine (Phila Pa 1976).* 2014;39(14):1113-20.
4. Di Lazzaro V, Oliviero A, Profice P, Ferrara L, Saturno E, Pilato F et al. The diagnostic value of motor evoked potentials. *Clin Neurophysiol.* 1999;110(7):1297-307.
5. Kameyama O, Shibano K, Kawakita H, Ogawa R. Transcranial magnetic stimulation of the motor cortex in cervical spondylosis and spinal canal stenosis. *Spine (Phila Pa 1976).* 1995;20(9):1004-10.
6. Dhall SS, Haefeli J, Talbott JF, Ferguson AR, Readdy WJ, Bresnahan JC et al. Motor Evoked Potentials Correlate With Magnetic Resonance Imaging and Early Recovery After Acute Spinal Cord Injury. *Neurosurgery.* 2018;82(6):870-876.
7. O'Brien WT Sr, Shen P, Lee P. The Dens: Normal Development, Developmental Variants and Anomalies, and Traumatic Injuries. *J Clin Imaging Sci.* 2015;5:38.
8. Nakanishi K, Tanaka N, Kamei N, Ohta R, Fujioka Y, Hiramatsu T et al. Electrophysiological evidence of functional improvement in the corticospinal tract after laminoplasty in patients with cervical compressive myelopathy: clinical article. *J Neurosurg Spine.* 2014;21(2):210-6.
9. AlEissa SI, Alhandi AA, Bugis AA, Alsalamah RK, Alsheddi A, Almubarak AK et al. The incidence of odontoid fractures following trauma in a major trauma center, a retrospective study. *J Craniovert Jun Spine.* 2020;11( 2): 71-74
10. Fox, S., Allen, L. & Norton, J. Neurophysiological monitoring of displaced odontoid fracture reduction in a 3-year-old male. *Spinal Cord Ser Cases* 4, 52 (2018).