

Endoscopic Sinus Surgery- Surgical Steps with Implications in Intraoperative Complications

Hakan Korkmaz¹([ID](#)), Mukadder Korkmaz²([ID](#))

¹Ordu University, Faculty of Medicine, Department of Otorhinolaryngology Head and Neck Surgery, Ordu, Turkey

²Private Clinics, Otorhinolaryngology, Ordu, Turkey

Received: 10 February 2022, Accepted: 14 April 2022, Published online: 31 May 2022
© Ordu University Institute of Health Sciences, Turkey, 2022

Abstract

Objective: Endoscopic sinus surgery is a worldwide performed operation which has gained acceptance as the primary treatment modality in paranasal sinus diseases. Any surgeon performing this surgery needs a valid treatment algorithm. Inappropriate surgical techniques may lead to failure and complications. Proximity of the surgical field to the critical structures poses difficulties to the surgeon. Too much removal of the normal structures and too little removal of the diseased tissues can have undesirable consequences. Although several techniques have been defined for each step, highlighting critical points in a concise manner will be beneficial.

Methods: This review article aimed to enlighten the complex paranasal sinus and relevant anatomy, define the intraoperative maneuvers to achieve a successful sinus surgery while avoiding surgeon-related complications. Books and journals were reviewed comprehensively. Classic techniques and contemporary aspects of the endoscopic sinus surgery were assembled.

Results: Paranasal sinus surgical anatomy and diseases show great variations. Endoscopic sinus surgery is performed in ameliorating paranasal sinus diseases. Improving the efficiency and safety of this surgery remains an important matter. There is a narrow border between suggested surgical steps and perilous complications. A thorough surgical anatomy knowledge and meticulous surgical methods need to be defined.

Conclusion: Sinus surgeon must carefully evaluate the underlying disease process, apply a precise surgical method, avoid possible complications, and should take necessary measures in case of a complication. A systematic surgical technique is mandatory for success.

Keywords: endoscopic sinus surgery; optic nerve injury; internal carotid artery injury; cerebrospinal fluid leak; Draf classification

Suggested Citation: Korkmaz H, Korkmaz M. Endoscopic sinus surgery- surgical steps with implications in intraoperative complications. Mid Blac Sea Journal of Health Sci, 2022;8(2): 320-331.

Copyright © Author(s) - Available online at <https://dergipark.org.tr/en/pub/mbsjohs>

Content of this journal is licensed under a Creative Commons Attribution-NonCommercial 4.0 International License.



E-mail: hakankorkmaz@hotmail.com

Address for correspondence/reprints:

Hakan Korkmaz

Telephone number: +90 (452) 225 23 42.

INTRODUCTION

Endoscopic sinus surgery (ESS) is a worldwide performed surgery. It is indicated for those patients with intractable chronic sinusitis or its complications, mucoceles, nasal poliposis, fungal diseases and neoplasms (1). There are studies aiming at identification of endotype and pathophysiology of the chronic sinusitis. These findings can lead to integrated treatment pathways of medical and surgical methods (2). Despite beneficial effects of medical therapy in nasal poliposis patients, combination of medical and surgical therapies in these patients have been found to be more efficacious with respect to general nasal symptoms (3).

It was reported that, ESS was not free of complications, even if the surgery was executed by an experienced surgeon. There was a direct relationship between the occurrence of complications and the extend of the surgery, presence and the grade of the polyposis, and if it was performed as a revision surgery (4). These complications comprise a great source of litigation facing otolaryngologists (5). While the occurrence of the minor complications is about 6 %, the risk of major complications varies between 0.5 to 1 % (4,6,7). A study analyzing the ESS complications in Japan evaluated 50734 patients and the incidences of cerebrospinal fluid leakage, orbital injury, bleeding requiring surgery and blood transfusion were 0.09%, 0.09%, 0.10% and 0.18% respectively, whatever the extent of surgery (8). The fear of causing complication causes many surgeons to perform incomplete surgeries, partial clearance of the diseased cells, with residual bony partitions. Incomplete removal of cells during ESS is an important reason for disease recurrence and poor outcome (9-11). Applying a precise surgical method

will improve the success rate and help to avoid complications. In an attempt to lessen complications, frameless stereotaxic surgery has been developed. Nevertheless, image guidance cannot be a substitute for a competent knowledge of the anatomy and meticulous use of instruments (12).

The goal of this article is to elucidate the surgical steps of a comprehensive endoscopic sinus surgery which will improve the mucociliary function and paranasal sinus ventilation, while highlighting critical points to avoid complications and methods of handling complications. The aim is to establish a practicable and valid surgical technique, enhancing the ease and safety of the ESS.

A range of methods from minimally invasive surgery to comprehensive ESS have been described. The degree to which extend the surgery should be performed varies from patient to patient. Operative procedure should be tailored to the pathology of the patient.

Given the closeness of the surgical area to the intracranial structures, orbital cavity, internal carotid artery and other vascular structures, optic nerve, and considering their relevant risks, ESS must be accomplished with utmost care, anatomical knowledge, appropriate surgical techniques. To avoid intraoperative complications and postoperative morbidities, critical points must be recognized. In case of an unfortunate trauma, appropriate steps to correct it must be undertaken without any hesitation.

To accomplish appropriate surgery and avoid intraoperative complications, preoperative assesment and preparation carry indispensable value. General medical condition should be determined. Scrutinizing axial and coronal paranasal sinus computed

tomography (CT) scans helps to identify the extend of the disease and defines the areas of technical difficulty (1). Structure of the paranasal sinuses, anatomical variations, deficient areas of the revision cases should be evaluated. Position of the cribriform plate, anterior ethmoid artery, dimensions of the infundibulum, presence of Onodi cells should be carefully assessed.

ESS is a challenging surgery because of neighborhood to the intracranial and orbital structures. Although having a detailed anatomic knowledge is prerequisite, distorted structures because of intranasal pathology, altered anatomy of revision surgeries, intraoperative bleeding may be misleading. Image guided surgery (IGS) provides detailed topographic localization of the surgical instruments within 2 mm (13). IGS is valuable especially in risky areas such as frontal sinus, skull base, anterior ethmoid artery.

ESS procedures can be performed using cold instruments or microdebriders. Microdebriders are powered tools that permit tissue removal and suction functions simultaneously. Specifically designed blades give the opportunity of precise soft tissue cutting in difficult to reach areas, such as frontal recess.

All paranasal sinuses except frontal sinus can be operated on using 0 degree and 30-degree rigid endoscopes. Using 0-degree endoscope yields minimal distortion of the vision and the spatial orientation will be better. The position of the anatomic landmarks, including uncinat process, ethmoid bulla, maxillary sinus ostium and basal lamella should always be considered throughout the

surgery. 70-degree endoscopes are helpful in acute angle areas, such as frontal recess.

METHODS

Surgical Technique:

Following the administration of oxymetazoline soaked cottonoids into both nasal cavities, vasoconstriction is obtained for endoscopic examination. After withdrawal of these cottonoids, nose is evaluated with a 0-degree 4 mm diameter endoscope. Topical anesthesia and additional vasoconstriction are achieved by using 1 % xylocaine with 1:100000 epinephrine injection into the lateral nasal wall, uncinat process and middle turbinate (1).

Middle turbinate is of utmost importance with respect to spatial orientation. Levin M et al concluded that middle turbinate is a significant landmark of the maxillary sinus ostium. Maxillary antrostomy through the inferior middle turbinate and 16.4mm posterior to its anterior border is secure in 98.5% of patients (14).

Uncinectomy: The first step of the endoscopic sinus surgery is uncinectomy, which is the excision of the uncinat process. Uncinectomy exposes the infundibulum. It is the key step in resolving pathologies affecting anterior sinus complexes (frontal, anterior ethmoid sinus and maxillary sinuses). The middle and lower posteroinferior parts of the uncinat process are resected while keeping the most upper part intact.

Medialization of the middle concha with Freer elevator displays the middle meatus and uncinat process. Several instruments can be used to excise the uncinat process, such as back-biters, through cutting forcepses, microdebrider or sickle knife. Initially, the uncinat process is palpated laterally using a ball-

tipped probe. It is applied to pull the uncinate process medially. Back-biter removes the uncinate process in a retrograde approach. Movable jaw of the backbiter is passed to the infundibulum and uncinate process is removed piece by piece. Remaining parts of the uncinate process can be trimmed with back-biter or through cutting forceps. Care should be given not to harm anteriorly placed nasolacrimal duct. Any resistance should alert the physician since the uncinate process has a thin structure (15).

At times, microdebrider can be used to take out the uncinate process instead of back-biters. If the microdebrider blade is forced against the orbital wall, orbital damage may ensue.

Sickle knife is used to incise the anterior attachment of the uncinate process to the nasolacrimal duct. Incision starts at the upper part and goes down and posteriorly along the sagittal plane. Alternatively, incision may be placed at the middle part, and can be extended up and down. Sharp edge of the freer elevator may be used instead of sickle knife. The depth of the incision more than 1 mm carries the risk of penetration of the lamina papyracea, especially when the maxillary sinus is hypoplastic and infundibulum is shallow. This trauma results in intraorbital bleeding or orbital fat exposure.

After a successful uncinectomy, maxillary sinus ostium can be visualized in most cases. When it is not clear, an angled sucker or a ball probe can be used to palpate the ostium. Usually, ostium lies at the level of the inferior edge of the middle turbinate. Minimal pressure should be applied in order to avoid entering the orbital cavity. For patients with limited disease, exposure of the natural ostium may be sufficient. Depending on the degree of the pathology, natural

ostium may be enlarged from 1 cm up to a wide antrostomy (Figure 1). The level of the wide antrostomy may extend to the posterior antral wall and inferior turbinate. Maximum enlargement is preferred in pathologies requiring wide access to the sinus cavity, such as cystic fibrosis, antrochoanal polyp, foreign body, fungus ball. When widening the maxillary ostium, pulling mucosa roughly should be avoided since this maneuver denudes the underlying maxillary sinus bone. Loose pieces of mucosa around the ostium should be trimmed carefully.

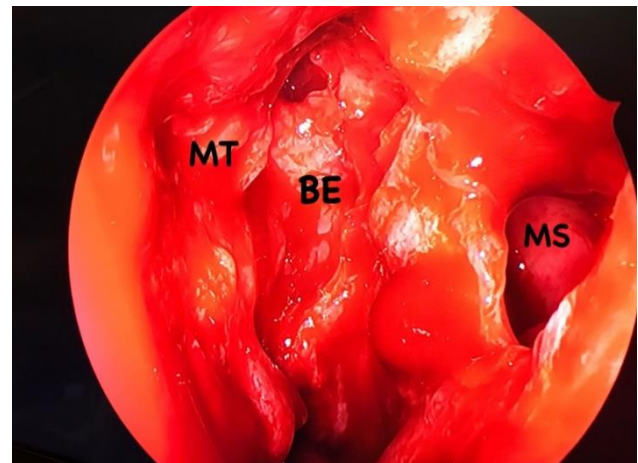


Figure 1. Left nasal cavity demonstrating middle meatus after removal of the nasal polyps and uncinuate process. Maxillary sinus ostium enlarged. MT:middle turbinate BE:bulla ethmoidalis MS: maxillary sinus

Primary surgical preference is adenoidectomy in refractory sinusitis cases in children. However sometimes ESS is needed in this age group. Main objective is the dilation of the natural ostia. Balloon catheter sinuplasty is an effective method in children. Mostly maxillary ostium is dilated since frontal sinus is not fully developed in most pediatric patients (16).

Maxillary sinus ostium is mostly enlarged to ameliorate antral diseases. Also, this procedure exposes the roof of the maxillary sinus so the level of the orbital floor is identified for the rest of the procedure. It is used as anatomic landmark during

entry and opening the posterior ethmoid cells to avoid penetration of the skull base.

Because of long standing chronic sinus infections, identification of the maxillary sinus ostium may not be possible. In this case, a right- angled probe can be used to palpate posteriorly located fontanelle. This mucosa is punctured and widened creating an accessory ostium. It can be enlarged far enough forward to connect to natural ostium. Any accessory ostium should be connected to the natural ostium to prevent recirculation of the mucus back into the maxillary sinus.

Aggressive widening of the ostium anteriorly may harm anteriorly placed nasolacrimal duct, causing nasolacrimal duct stenosis or collection of the tears in the maxillary sinus. In most cases it remains asymptomatic and no therapy is necessary. If it results in drainage problems in the postoperative period, dacryocystorhinostomy is recommended.

When the maxillary sinusotomy is extended to within the 0.5 cm of the posterior wall, a branch of the sphenopalatine artery is encountered and it may need cautery.

During uncinectomy and exploration of the maxillary sinus ostium, if the lamina papyracea is entered and orbital fat is exposed, eyelid ecchymosis and edema may ensue in the early postoperative period. Orbital fat tissue should not be removed. Repositioning of any orbital fat tissue is not necessary. Usually, it heals without any intervention.

Lateralization of the middle turbinate postoperatively may cause recurrence of sinus problems. Providing medialization and scar adhesion of the middle turbinate by decortication of the head of

the turbinate and septal mucosa prevent such sequelas (17).

Anterior Ethmoidectomy: Following uncinectomy and opening maxillary sinus ostium, ethmoid bulla is opened.

The initial point of entry into the bulla ethmoidalis is the medial and inferior aspect. Upon feeling the sinus cavity with an instrument, removal advances superiorly and laterally. Anterior wall of the bulla ethmoidalis is removed disclosing the posterior basal lamella. Its lateral border is the lamina papyracea. It is better not to touch the anterior superior wall of the bulla ethmoidalis in order to keep it as a landmark to help localize the frontal recess and anterior ethmoid artery.

Posterior Ethmoidectomy: The posterior wall of the bulla ethmoidalis, which is called the basal (third) lamella, forms the anterior boundary of the posterior ethmoid cells. Posterior ethmoid cells are entered through the basal lamella (Figure 2). This part of the surgery is important since careless instrumentation may lead to inadvertant skull base injury. Both the location and the direction of the removal of the basal lamella are important. Working medially and inferiorly is safe generally. The axial limit of the opening the posterior ethmoids should be below the level of the orbital floor and sagittal plane should be medial to the medial wall of the maxillary sinus. When this space is opened, superior concha and anterior wall of the sphenoid sinus are exposed.

Lamina papyracea is a very thin structure and can be breached easily. Its integrity ought be controlled by Stankiewicz maneuver in suspicious cases: Under endoscopic observance of the test area, pressing the globe will move the orbital fat. Halting additional

tissue removal in this area will prevent any muscle or nerve damage.

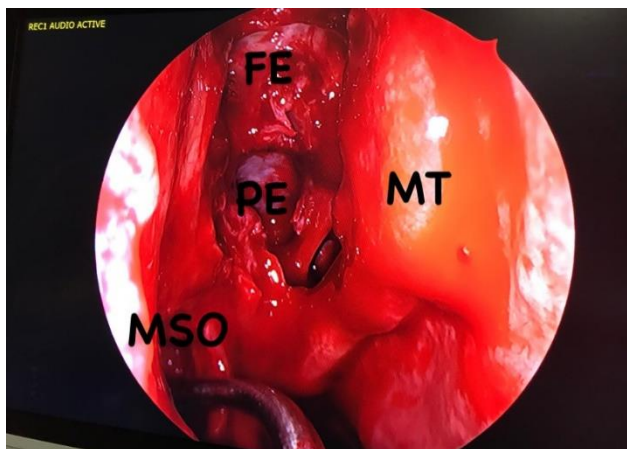


Figure 2. Right middle meatus following ethmoidectomy. MT:middle turbinate FE:fovea ethmoidalis PE: posterior ethmoidal cells MSO: maxillary sinus ostium and suction device

Sphenoidotomy and sphenoidectomy: The sphenoid sinus ostium can be identified by either the transethmoid or transnasal approach. Entering the sphenoid sinus by way of the posterior ethmoid cells is risky. It is best to find the sphenoid sinus ostium medial to the middle turbinate. Sphenoid sinus ostium is 1 cm above the posterior choana, medial to the superior turbinate, just lateral to the septum. By following the choana superiorly with a ball point probe, sphenoid ostium can be identified. An instrument placed between the anterior nasal spine and the anterior wall of the sphenoid sinus at an angle of 30 degrees will measure 7 cm (18). When the anterior wall of the sphenoid sinus is thick because of hyperostosis, anterior wall can be drilled under the control of CT evaluation (Figure 3).

The transethmoid approach is preferred when concurrent disease occurs in the ethmoid sinus that requires treatment. Once the posterior ethmoid cell has been identified, dissection proceeds inferiorly and medially. Superior turbinate and meatus are exposed. Sometimes, removing posterioinferior end of the

superior turbinate facilitates identification of the sphenoid sinus ostium. This removal exposes the sphenoid ostium, which is medial to the resection area. This maneuver should be limited. It is wise to avoid unnecessary superior turbinate resection since there resides olfactory epithelium.

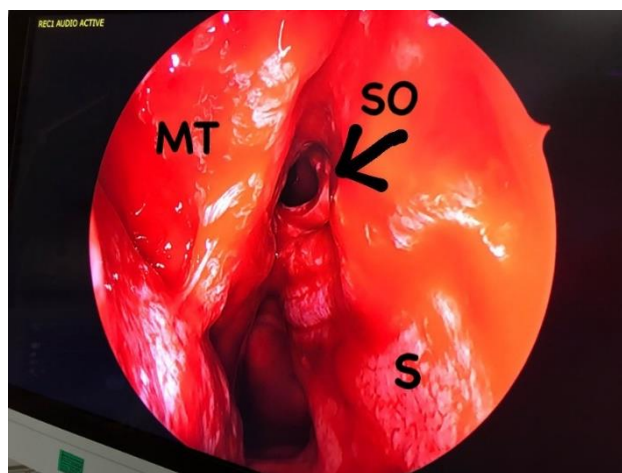


Figure 3. Enlarged right sphenoid sinus ostium. MT:middle turbinate SO: sphenoid sinus ostium S:septum

After the sphenoid sinus ostium is visualized, it can be enlarged. At the anterior surface, septal branch of the sphenopalatine artery runs horizontally inferior to the ostium. So, widening of the ostium inferiorly should be limited. If this artery bleeds, it can be safely cauterized. Anterior wall is removed superiorly until it is flush with the skull base. The roof of the sphenoid sinus represents the lowest point of the skull base.

Once the sphenoid sinus ostium is enlarged, the medial- inferior aspect of the posterior ethmoid cells can be punctured just lateral to the superior turbinate in order to join the sphenoid sinus and posterior ethmoid cells. This partition can be enlarged laterally up to the lateral wall of the sphenoid sinus.

Both the optic nerve and the internal carotid artery are situated along the posterolateral wall of the sphenoid sinus. At times, bone overlying these structures may be dehiscent. Mostly, sphenoid

sinuses are not symmetric and intersinus septum shows variable connections to surrounding structures. It is not uncommon that intersinus septum attaches to internal carotid artery making its manipulation dangerous (19). Medial and superior wall of the sinus leads to the sella turcica and pituitary gland in it. Superior wall of the sphenoid sinus is extremely thin. Manipulations within the sphenoid sinus deserves utmost care in order to avoid catastrophic complications.

Sometimes, sphenothmoid (Onodi) cells extend laterally and superiorly to the sphenoid cells. These cells can be identified in the CT scan. Onodi cell may embrace or completely surround the optic nerve. The internal carotid artery may also bulge through posterolateral wall of this cell. Approaching to the sphenoid sinus through Onodi cell may damage the optic nerve and the internal carotid artery.

Injury of the internal carotid artery is the most dreaded complication of the ESS. Anomalies of the artery, aggressive manipulation of the lateral intersinus sphenoid septations or greater extend of surgery increase the likelihood of this trauma. This injury requires immediate tamponade of the sphenoid sinus and balloon occlusion of the artery. There is a high probability of neurologic sequelae and death.

Most injuries of the optic nerve occur in the presence of the Onodi cell. In the event of optic nerve injury, repair is not helpful and it results in irreversible blindness.

Total ethmoidectomy: Once the level of fovea ethmoidalis is established, posterior ethmoid dissection can be commenced from posterior to anterior, from known to unknown, up to the anterior ethmoid artery. The fovea ethmoidalis is followed

anteriorly along the posterior ethmoids first and anterior ethmoids later. The width of the ethmoid cavity decreases from posterior to anterior. During dissection of both anterior and posterior ethmoidal cells, the level of the fovea ethmoidalis (superior wall), lamina papyracea (lateral wall) and cribriform plate (medial wall) should be taken into consideration. The level of the fovea ethmoidalis is usually above the roof of the sphenoid sinus. Mostly, the angle of the surgical instruments is perpendicular to the skull base. Fovea ethmoidalis seems like a white plate of bone, while lamina papyracea has a yellow reflection. The junction of the fovea ethmoidalis and middle turbinate (lateral cribriform lamella) is especially vulnerable to injury. While the thickness of the ethmoid roof next to the lateral lamella is about 0.5 mm, thickness of the lateral lamella of the cribriform plate is about 0.05 mm (20). A deeper olfactory fossa (cribriform plate) relative to the fovea ethmoidalis increases the risk of lateral lamella injury with resultant cerebrospinal fluid (CSF) leak (21).

Ethmoid cells should be removed close to the skull base, trying to keep the mucosa intact. Each bony lamella should be checked carefully before removal. If the area behind the bony lamella is empty, it can be removed safely, preferably using through cutting instruments. Ethmoid cells medial to the lamina papyracea are removed.

Despite adequate precautions, cases of CSF leak will still be encountered. Repairing any CSF leak at the time of surgery avoids serious complications. First of all, extent of the injury should be evaluated. Neighbouring bone partitions and nasal mucosa are removed to facilitate contact of the graft with the skull

base. When the bony defect size is large, underlay bone or cartilage graft can be used to occlude the gap. The nasal side of the injury is closed with a variety of grafts, such as nasal or turbinate mucosa, temporalis fascia, fascia lata, temporalis muscle, abdominal fat, acellular dermal grafts, perichondrium. The graft is secured with gelfoam and nasal cavity is packed (22).

If the lamina papyracea is breached, medial rectus and superior oblique muscles may be injured. Immediate treatment of the laceration is recommended since late interventions are ineffective. Muscle must be repaired by an ophthalmologist through an external approach.

Frontal sinus surgery: If there is opacification of the frontal recess, it is best to perform anterior ethmoidectomy as the first step surgery and reserve frontal recess surgery if this fails. Anterior ethmoidectomy can be adequate to resolve the frontal recess pathology. In the case of osteoma, mucocele, fungal infection, frontal recess is operated on at the first step.

Computer assisted navigation system is valuable in ESS, especially in revision cases and advanced surgeries. Frontal recess approach is the most challenging part of the ESS. Navigation of the frontal sinus surgery reduces the disease process and improves the patient satisfaction (23).

Access into the frontal recess is technically demanding and potentially dangerous step of the ESS. Frontal recess surgery is susceptible to high failure rate, postoperative stenosis and major complications. Especially when the dimensions of the frontal recess is small, any attempt to open it is more risky. Manipulation of the frontal sinus is critical since the frontal sinus is close to the anterior cranial cavity,

orbit and anterior ethmoid artery. Before commencing to the frontal sinus surgery, the neighborhood of this narrow space should be taken into account to avoid unwanted complications (24). Lateral lamella of the cribriform plate is very thin and easily injured with resultant cerebrospinal fluid leak, so pressure should not be applied medially. Again, when the agger nasi cells are absent or rudimentary, probing laterally may damage orbital cavity. Additionally, inadvertant trauma to the frontal recess mucosa may cause stenosis. The obscure location of the frontal recess and its close proximity to the eye and brain may dissuade the surgeon from performing appropriate surgery (25).

Insertion site of the anterior uncinat process should be considered from the CT scan. If uncinat process inserts to the lamina papyracea, frontal recess drains to the middle meatus. If uncinat process attaches to the skull base or middle turbinate, frontal recess opens to the infundibulum.

Switching to the 45 degrees endoscope gives better visualization at this level of the surgery. The anterior ethmoid artery usually lies posteroinferior to the frontal recess (Figure 4). It is mostly posterior to the supraorbital ethmoid cells but may be situated between supraorbital cells and frontal sinus. It runs along the roof of the ethmoid from the orbital cavity to the anterior cranial cavity. If there is a supraorbital cell, frontal sinus ostium will be more medially located.

Leading a ball probe gently lateral to the anterior middle turbinate reveals the frontal recess. Anterior wall of the ethmoid bulla helps to define the frontal recess (Figure 5). This part of the ethmoid bulla is removed. This will reveal the suprabullar recess.

Agger nasi cells are opened anteroinferiorly with curettes. Bone fragments are removed. Removal of the agger nasi cells is safe since they are away from the eye and intracranial cavity (25).

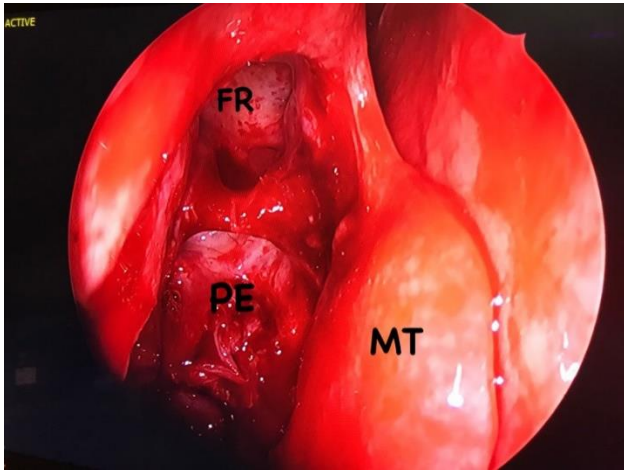


Figure 4. 45-degree view of the frontal recess in the right nasal cavity. Note that anterior ethmoidal artery is located just posterior to the recess. MT:middle turbinate FR:frontal recess PE: posterior ethmoidal cell

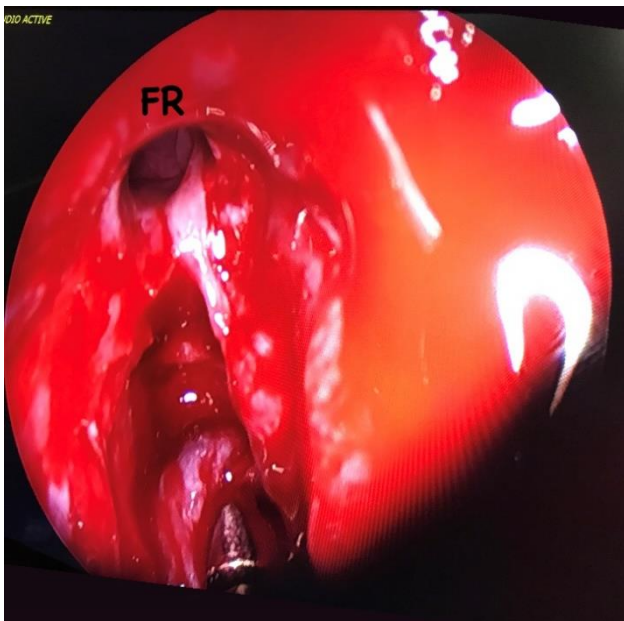


Figure 5. 45-degree view of the frontal recess in the right nasal cavity of a different patient. Suction device is pointing the posterior ethmoidal cell. FR: frontal recess

Endoscopic light can be used to delineate the borders of the frontal sinus in case of frontal sinus obliteration surgery. Transillumination of the frontal recess area intranasally demonstrates the extension of

the frontal sinus at the level of dark and bright zone intersection.

Additionally, frontal sinus transillumination can be used to assess the patency of the frontal recess. Intranasal application of the endoscopic light can be seen as brightness in the frontal area if the frontal sinus is patent. (26).

The Draf classification of the frontal recess surgery consists of 3 steps (27). In a Draf I surgery, after dissection of the anterior ethmoid cells, frontal sinus drainage pathway is palpated with a probe and its patency is confirmed. Any obstructive pathology inferior to the frontal sinus ostium is removed. Anterosuperior ethmoid cells and frontal cells are dissected from posterior to anterior, remaining anterolaterally. Care is taken to avoid stripping and removing surrounding mucosa. Bony fragments are removed taking care to keep the mucosa undisturbed. The Draf II and III are extended frontal sinusotomies. They are preferred when more conservative surgeries fail or in recalcitrant frontal sinus diseases. The extent of the Draf II surgery includes the cells removed in Draf I surgery and also obstructing structures extending to the frontal sinus ostium. Nasofrontal beak or frontal recess cells protruding into the frontal sinus are removed. In a Draf IIa surgery, the frontal sinus ostium is opened between the lamina papyracea and the middle turbinate. Draf IIb involves the opening of the frontal sinus ostium between the lamina papyracea and the nasal septum. First, Draf IIa procedure is performed and additionally anterior attachment of the middle turbinate to the skull base is removed. Draf IIb is indicated when the Draf IIa fail, especially if the frontal sinus ostium is narrow. The Draf III frontal sinusotomy, also known as

endoscopic modified Lothrop procedure, is bilateral Draf IIb procedure with the addition of removal of the part of the superior nasal septum and part of the inferior frontal intersinus septum creating one common recess. To form the common recess by this method, the size of the frontal recess should be adequate. The minimum anterior-posterior distance of the frontal recess should be 5-6 mm on the CT scan. The risk of CSF leak is 10 % with this technique (28).

The anterior ethmoid artery crosses the roof of the anterior ethmoid cells posterior to the frontal recess. Anterior and posterior ethmoid arteries are branches of the ophthalmic artery, passing from the orbital cavity to the nasal cavity. The anterior ethmoid artery travels anteromedially to the anterior cranial cavity. It may be at the level of skull base or may be placed inferiorly, tenting in bony mesenteries. Posterior ethmoid artery lies within the skull base anterior to the sphenoid sinus and it is difficult to identify. When the anterior ethmoid artery is severed, it may retract into the orbital cavity with resultant orbital hematoma. Ligation of this vessel is very difficult since it will retract into the orbit. A sudden onset of increased intraorbital pressure and proptosis occurs. If this high pressure is not relieved within 60 to 90 minutes, blindness may ensue (29). An ophthalmology consultation is necessary. Steroid and mannitol administration are helpful. Intraocular pressure greater than 40 mm Hg is an absolute indication for lateral canthotomy and cantholysis (22). If these are not sufficient, medial orbital decompression may be needed additionally. Bleeding of the posterior ethmoid artery is rarely encountered. It can be identified after posterior ethmoidectomy and

sphenoidotomy, coursing anteroposteriorly. Bleeding can be controlled with bipolar electrocautery.

Avoidance of nose blowing after surgery is recommended as these attempts can cause subcutaneous or orbital emphysema. Intranasal packing can be considered if there is a bleeding tendency, overmobile middle turbinate, or in cases of simultaneous septoplasty surgery cases.

Postoperative care of the nasal cavity has considerable importance with respect to optimum healing. Irrigation of the operative field using hypertonic or isotonic solutions and periodic debriment of clots, mucous plugs improve rapid healing and decrease any synechia formation. Debriment can begin in the postoperative first or second weeks and performed several times as needed. Following surgery, irrigation of the nasal cavity by diluted baby shampoo was shown to reduce crusting and synechia and improved SNOT-22 scores (30).

REFERENCES

1. Clemente MP (2005) Combined microscopic and endoscopic technique (COMET surgery). In: Levine HL, Clemente MP (eds) Sinus surgery, endoscopic and microscopic approaches, Thieme, New York, pp 162-206.
2. Xu Z, Huang Y, Delemarre T, Cavaliere C, Zhang N, Bachert C. Advances in chronic rhinosinusitis in 2020 and 2021. *J Allergy Clin Immunol.* 2021 Dec 29:S0091-6749(21)02744-5. doi: 10.1016/j.jaci.2021.12.782. Epub ahead of print. PMID: 34973298.
3. Lourijzen ES, Reitsma S, Vleming M, Hannink G, Adriaansen GFJPM, Cornet ME, et al. Endoscopic sinus surgery with medical therapy versus medical therapy for chronic rhinosinusitis with nasal polyps: a multicentre, randomised, controlled trial. *Lancet Respir Med.* 2022;7:2213-2600(21)00457-4. doi:

- 10.1016/S2213-2600(21)00457-4. Epub ahead of print. PMID: 35012708.
4. Ribeiro RB, Reis CP, Castro SS, Ferreira JP, Sousa CA. Endoscopic sinus surgery: A safe procedure among the less experienced surgeons? *Auris Nasus Larynx* 2012;39:490-95.
 5. Bolger W, Kennedy D. Complications of surgery of the paranasal sinuses. In: Eisele D, ed. *Complications in Head and Neck Surgery*. St. Louis: Mosby Yearbook, 1993:458-70.
 6. May M, Levine HL, Mester SJ, Schaitkin B. Complications of endoscopic sinus surgery. Analysis of 2108 patients: incidence and prevention. *Laryngoscope* 1994;104:1080-3.
 7. Kennedy DW, Shaman P, Han W, Selman H, Deems DA, Lanza DC. Complications of ethmoidectomy: a survey of fellows of the American Academy of Otolaryngology- Head and Neck Surgery. *Otolaryng Head Neck Surg* 1994;111:589-99.
 8. Suzuki S, Yasunaga H, Matsui H, Fushimi K, Kondo K, Yamasoba T. Complication rates after functional endoscopic sinus surgery: analysis of 50,734 Japanese patients. *Laryngoscope* 2015;125:1785-91.
 9. Okushi T, Mori E, Nakayama T, Asaka D, Matsuwaki Y, Ota K, et al. Impact of residual ethmoid cells on postoperative course after endoscopic sinus surgery for chronic rhinosinusitis. *Auris Nasus Larynx* 2012;39:484-489.
 10. Bradley DT, Kountakis SE. The role of agger nasi air cells in patients requiring revision endoscopic frontal sinus surgery. *Otolaryngol Head Neck Surg* 2004;131:525-7.
 11. Wormald PJ. The agger nasi cell: the key to understanding the anatomy of the frontal recess. *Otolaryngol Head Neck Surg* 2003;129:497-507.
 12. Chu ST. Endoscopic sinus surgery under navigation system- Analysis report of 79 cases. *J Chin Med Assoc* 2006;69(11):529-533.
 13. Labadie RF, Davis BM, Fitzpatrick JM. Image-guided surgery: what is the accuracy? *Curr Opin Otolaryngol Head Neck Surg* 2005;13(1):27-31.
 14. Levin M, Chan TJ, Hua G, Sommer DD. The middle turbinate as an anatomical landmark for a safe maxillary antrostomy during endoscopic sinus surgery: A computed tomography study. *Operative Techniques in Otolaryngology* 32 (2021) e6-e11.
 15. Simmon D, Jones N (2005) How? Operative procedures: A step-by-step safe and logical approach. In: Simmon D, Jones N (eds) *Manual of endoscopic sinus surgery and its extended applications*, 1st edn. Thieme, Stuttgart, New York, pp: 50-105.
 16. Rose AS, Thorp BD, Zanation AM, Ebert CS Jr. Chronic rhinosinusitis in children. *Pediatr Clin North Am*. 2013 Aug;60(4):979-91. doi: 10.1016/j.pcl.2013.04.001. Epub 2013 May 13. PMID: 23905832.
 17. Brescia G, Contro G, Frasconi S, Marioni G. Middle turbinate handling during ESS. Our experience. *Am J Otolaryngol*. 2021 Jul-Aug;42(4):102980. doi: 10.1016/j.amjoto.2021.102980. Epub 2021 Feb 16. PMID: 33621766.
 18. Casiano RR. A stepwise surgical technique using the medial orbital floor as the key landmark in performing endoscopic sinus surgery. *Laryngoscope* 2001;111:964-974.
 19. Sareen D, Agarwal AK, Kaul JM, Sethi A. Study of sphenoid sinus anatomy in relation to endoscopic surgery. *Int J Morphol* 2005;23(3):261-266.
 20. Kainz J, Stammberger H. Das Dach des vorderen Siebbeins: ein Locus minoris resistentia an der Schadelbasis. *Laryngorhinootologie* 1998;67:142-149.
 21. Tewfik MA, Wormald PJ. Ten pearls for safe endoscopic sinus surgery. *Otolaryngol Clin n Am* 2010;43:933-944.
 22. Welch KC, Palmer JN. Intraoperative emergencies during endoscopic sinus surgery: CSF leak and orbital hematoma. *Otolaryngol Clin n Am* 2008;41:581-596.

23. Galletti B, Gazia F, Freni F, Sireci F, Galletti F. Endoscopic sinus surgery with and without computer assisted navigation: A retrospective study. *Auris Nasus Larynx*. 2019 Aug;46(4):520-525. doi: 10.1016/j.anl.2018.11.004. Epub 2018 Dec 6. PMID: 30528105.
24. Huang BY, Lloyd KM, DelGaudio JM, Jablonowski E, Hudgins PA. Failed endoscopic sinus surgery: spectrum of CT findings in the frontal recess. *Radiographics*. 2009;29(1):177-95.
25. Friedman M, Landsberg R. Frontal sinus surgery: endoscopic technique. *Operative Techniques in Otolaryngol- Head Neck Surg* 2001;12(2):60-65.
26. Friedman M, Landsberg R, Tanyeri H. Intraoperative and postoperative assessment of frontal sinus patency by transillumination. *Laryngoscope*. 2000 Apr;110(4):683-4. doi: 10.1097/00005537-200004000-00027. PMID: 10764019.
27. Weber R, Draf W, Kratzsch B, Hosemann W, Schaefer SD. Modern concepts of frontal sinus surgery. *Laryngoscope* 2001;111(1):137-46.
28. Govindaraj S, Agbetova A, Becker S. Revision sinus surgery. *Oral Maxillofacial Surg Clin N Am* 2012;24:285-293.
29. Stankiewicz JA, Chow JM. Two faces of orbital hematoma in intranasal (endoscopic) sinus surgery. *Otolaryngol- Head Neck Surg* 1999;120:841-7.
30. Tulaci KG, Arslan E, Tulaci T, Yazici H. Comparison of effects of baby shampoo vs. saline irrigation on endoscopic sinus surgery outcomes and quality of life. *Auris Nasus Larynx*. 2021 Jun;48(3):408-414. doi: 10.1016/j.anl.2020.08.009. Epub 2020 Aug 26. PMID: 32859445