



2-Year follow-up of bilateral immediate autotransplantation

Bilateral immediyat ototransplantasyon olgusunun 2 yıllık takibi

Ferhat AYRANCI 
Hasan AKPINAR 

Department of Oral and
Maxillofacial Surgery, Ordu
University, Faculty of Dentistry,
Ordu, Turkey



ABSTRACT

Tooth missing in children and young adults can be congenital or caused by tooth decay, periodontal disease and trauma. This situation can be rehabilitated with implant supported prosthetic treatments, crown bridge prostheses or removable partial dentures. However, the mentioned treatments are postponed to later periods, considering the growth and development period in children and young adults. When implant-supported prosthetic treatments are applied during the growth and development period, implant-supported prostheses may remain in infra-occlusion. Therefore, the dominant opinion in the literature is that implant surgery is contraindicated in children and young adults. For this reason autotransplantation surgery has been used frequently in recent years as an alternative treatment option. In this case report, a 2-year follow-up of bilaterally transplanted mandibular 3rd molar teeth is presented. A 17-year-old female patient, who had no systemic disease, was admitted to our clinic with pain in the right lower jaw. In the clinical examination of the patient, a fistula was observed in the right lower first molar tooth area. As a result of the radiological examination, periapical lesions were observed in both lower molar teeth. Orthodontic and prosthetic treatment options and autotransplantation surgery as an alternative treatment option were explained to the patient. Bilateral autotransplantation was performed 2 weeks apart. During the 2-year follow-up, it was observed that the teeth were vital and no periapical pathology developed. Autotransplantation is an alternative treatment option that should be considered in single tooth missing, especially in young adults. In addition to its low cost, the improvement of the proprioceptive sensation and the ability to be applied in one session are among the important advantages of the procedure.

Keywords: Autotransplantation, young adult, molar tooth

ÖZ

Çocuklar ve genç erişkinlerde görülen diş eksiklikleri implant destekli protetik tedaviler, kron-köprü protezler veya hareketli bölümlü protezlerle rehabilite edilebilmektedir. Ancak belirtilen tedaviler çocuklar ve genç erişkinlerde büyüme gelişim dikkate alındığında daha sonraki dönemlere ertelenmektedir. Özellikle implant cerrahisinin, büyüme gelişim döneminde implantın infraoklüzyonda kalması nedeniyle diş eksikliklerinin tedavisinde kontrendike olduğu görüşü literatürde hakimdir. Bu nedenle alternatif tedavi seçeneği olarak ototransplantasyon cerrahisi son yıllarda sıklıkla uygulanmaktadır. Bu vaka sunumunda çift taraflı olarak transplante edilmiş mandibular 3.molar dişlerin 2 yıllık takibi sunulmuştur. Sistemik olarak herhangi bir rahatsızlığı bulunmayan 17 yaşında kadın hasta kliniğimize sağ alt çenede ağrı şikayetiyle başvurdu. Hastanın yapılan klinik muayenesinde sağ alt 1. molar diş bölgesinde fistül olduğu gözlemlendi. Yapılan radyolojik muayene sonucunda her iki alt molar dişte de periapikal lezyon olduğu görüldü. Hastaya ortodontik ve protetik tedavi seçenekleri ile birlikte alternatif tedavi seçeneği olarak ototransplantasyon cerrahisi anlatıldı. 2 hafta arayla çift taraflı ototransplantasyon yapıldı. 2 yıllık takipte dişlerin vital olduğu, herhangi bir periapikal patolojinin gelişmediği gözlemlendi. Ototransplantasyon özellikle genç erişkinlerde görülen tek diş eksikliklerinde düşünülmesi gereken alternatif tedavi seçeneğidir. Maliyetinin uygun olmasının yanı sıra, proprioseptif duyunun yeniden kazanılması ve tek seansta uygulanabilmesi prosedürün önemli avantajlarındandır.

Anahtar Kelimeler: Ototransplantasyon, genç erişkin, molar diş

INTRODUCTION

Tooth missing in children and young adults can be congenital or caused by tooth decay, periodontal disease and trauma.^{1,2} This situation can be rehabilitated with implant supported prosthetic treatments, crown bridge prostheses or removable partial dentures.³ However, these treatments are postponed to later periods, because of growth and development period in children and young adults. When implant-supported prosthetic treatments are applied during the growth and development period, implant-supported prostheses may remain in infra-occlusion. Therefore, the dominant opinion in the literature is that implant surgery is contraindicated in children and young adults.⁴ On the other hand, atrophy develops during the waiting period in edentulous alveolar crests and may cause the need for additional grafts for ideal treatment.⁴

The autotransplantation protocol defined in 1956 is considered as an alternative treatment options.⁵ Autotransplantation, which is generally applied in the above-mentioned tooth loss indications; It can

Received/Geliş Tarihi: 27.10.2020

Accepted/Kabul Tarihi: 18.03.2021

Sorumlu Yazar/Corresponding Author:
Hasan Akpinar
E-posta: hsnakpinar03@gmail.com

Cite this article: Ayrancı F, Akpinar H.
2-Year follow-up of bilateral immediate
autotransplantation. *Curr Res Dent Sci.*
2022; 32(1): 128-131



Content of this journal is licensed
under a Creative Commons
Attribution-NonCommercial 4.0
International License.

also be applied to bring ectopic or impacted teeth to their normal position.² Autotransplantation is the process of transplanting the impacted or semi-impacted teeth to edentulous space.² Patient selection is an important issue in autotransplantation. The patient's oral hygiene, general health status, the level of cooperation of the patient and the patient's desire for treatment are factors that affect the success of the treatment.⁷

The success of autotransplantation depends on the following factors; root development level of the transplanted tooth, root morphology, surgical technique, extraoral time before transplantation, socket shape and blood supply of the recipient socket and the vitality of the periodontal ligament cells.⁹ In addition, the roots of transplanted tooth should be at least 1 mm between the neighboring roots and transplanted tooth roots should not be in close contact with the bone in the socket.⁴ Long-term success criteria are the absence of progressive root resorption and the absence of periodontal pathology.⁹

Ankylosis, root resorption and attachment loss can be seen in the transplanted teeth.^{5,10} External resorption is observed when the periodontal ligament and root surface are damaged during transplantation, and inflammatory resorption is observed in cases of injury to the pulpal tissues.¹

In this case report, a 2-year follow-up of bilaterally transplanted mandibular 3rd molar teeth is presented.

CASE PRESENTATION

A 17-year-old female patient, who had no systemic disease, was admitted to our clinic with pain in the right lower jaw. In the clinical examination of the patient, a fistula was observed in the right lower first molar tooth area. As a result of the radiological examination, periapical lesions were observed in both lower molar teeth (Figure 1). As a result of the endodontic consultation, it was predicted that the prognosis would be suspicious if the root canal treatment was retreatment, and it was decided to extract the teeth. Orthodontic and prosthetic treatment options were explained to the patient. Autotransplantation surgery was described as an alternative treatment option because the patient was young, the root forms of the lower wisdom teeth were appropriate and the root formations were incompleting. After obtaining informed consent, the decision was made for immediate autotransplantation of bilateral mandibular 3rd molar teeth. The patient was prescribed antibiotics for 1 week before the operation. After local anesthesia, the full-thickness flap was reflected in accordance with the impacted 3rd molar surgery. Some bone was removed for atraumatic extraction of the first molar tooth. After atraumatic extraction of the tooth, the periapical lesion was curetted. The socket entrance was covered with gauze sponges until transplantation. Then, the bone areas providing retention were removed and the impacted 3rd molar tooth was extracted atraumatically. Since the extracted tooth roots should not be in tight contact with the bone, minor corrections were made in the recipient socket. Later, the tooth was transplanted without touching the root surface in order not to damage the periodontal ligament cells. Then, occlusion was controlled and 1 mm occlusal reduction was performed to prevent contact (Figure 2). The stability of the tooth was achieved by cross-suturing the tooth. Later, full-thickness flap was primarily closed. Antibiotics, analgesic and mouthwash were prescribed to the patient. The same procedure was performed for the transplantation of the impacted molar tooth in the left lower jaw after 2 weeks (Figure 3). During

the 2-year follow-up, it was observed that the teeth were vital and no periapical pathology developed (Figure 4,5,6).

DISCUSSION

Because of the functional and morphological characteristics of first molar tooth, they are often affected by caries, so early extraction may be required.¹¹ Although there are many different treatment options in single tooth missing, autotransplantation

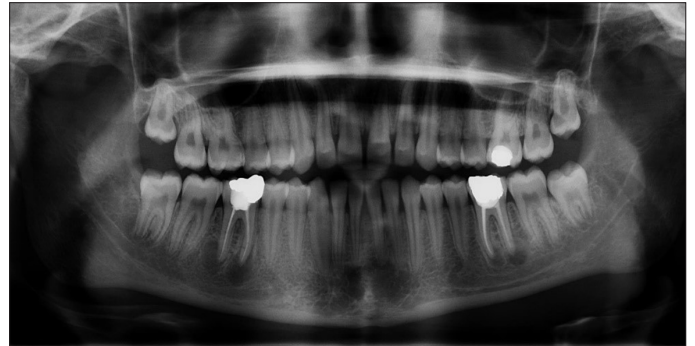

Figure 1. Preoperative panoramic radiography.

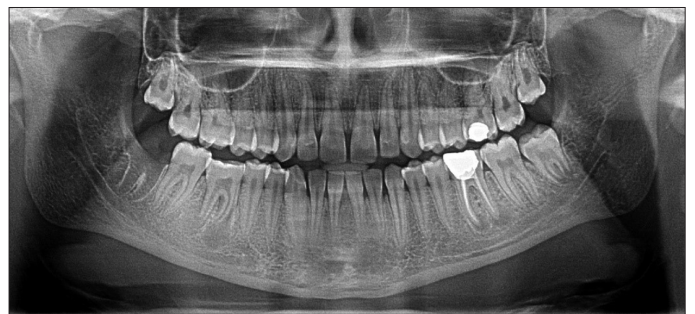


Figure 2. After transplantation to the lower right jaw.

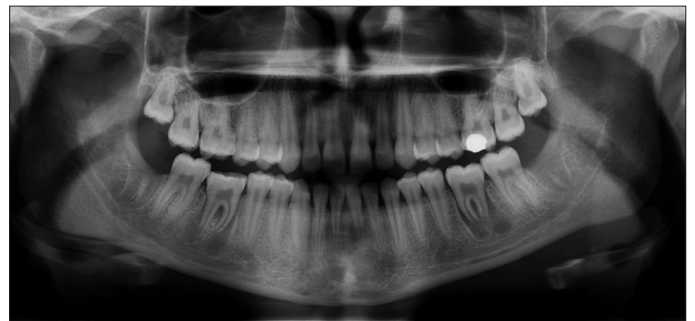

Figure 3. After transplantation to the lower left jaw.

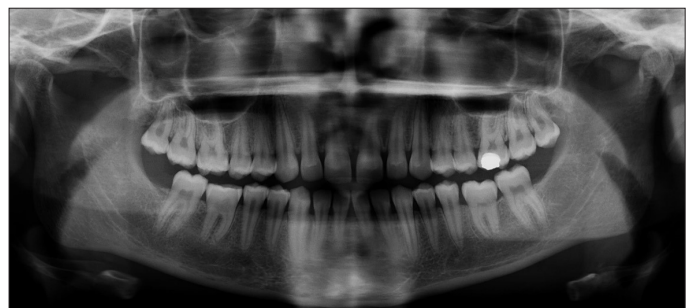

Figure 4. 2-year follow-up panoramic radiograph.

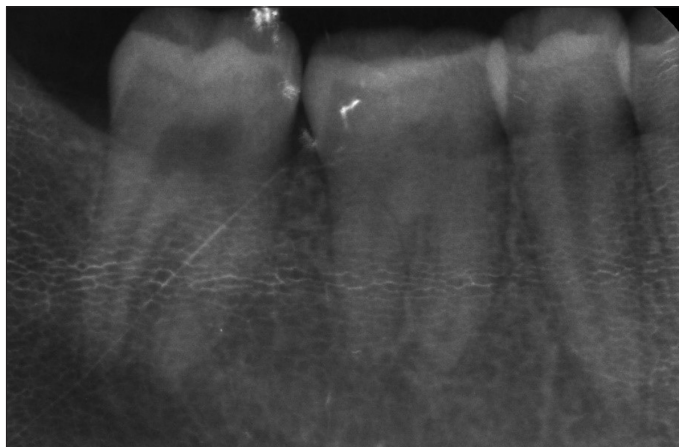

Figure 5. 2-year follow-up periapical radiograph for right tooth.

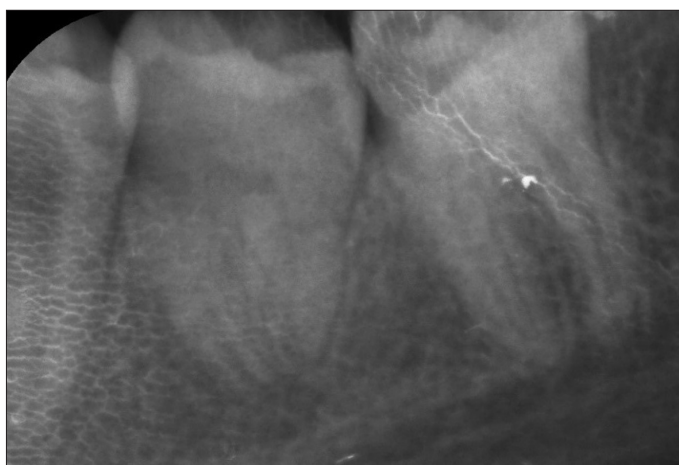


Figure 6. 2-year follow-up periapical radiograph for left tooth.

has been applied frequently in recent years due to its low cost, ability to be applied in a single session and regaining proprioceptive functions.^{2,12}

Although autotransplantation has been applied procedure since the 1950s, the success rate remained at 50% due to the difficulties in determining the level of root growth, so root resorption was seen after transplantation.⁵ The success rate in publications reported in recent years has reached 93%.¹³ The extraoral time of the transplanted tooth also affects this success rate. It has been reported that the viability of periodontal tissues will decrease significantly in cases where this extraoral time is longer than 18 minutes.¹⁴ In our case, in order to shorten this time as much as possible, the tooth was extracted after all the recipient area preparations, and the total extraoral time was limited to 2-3 minutes. Bae et al.¹⁴ in his study, in order to shorten this time, a 3-dimensional prototype of the transplanted tooth was created and the receiver socket was prepared.

An other important factor for success is the root development level of the tooth.² It has been reported that the pulpal healing rate, which is 15% in mature teeth, increases up to 96% in immature teeth.¹⁵ There is no consensus on the ideal root development level among immature teeth. Although there are studies that find root development sufficient until furcation, also different studies reported that at least 1/3 of the root should be formed.¹⁵

Panoramic and periapical radiographs are generally used in treatment planning.^{2,4} In recent years, the use of 3D imaging methods in treatment planning has increased. Plotino et al.¹⁶ emphasizes that especially in multi-rooted teeth, donor teeth can be extracted atraumatically thanks to preoperative tomography evaluation. After tooth extraction, transplantation can be done to fresh sockets, as well as late autotransplantation by creating sockets with implant drills for edentulous space and congenital deficiencies.⁷ Comparing immediate and late autotransplantation, Yu et al.¹³ success rates were found as late autotransplantation with guided bone regeneration (GBR), immediate autotransplantation and late autotransplantation without GBR, respectively.¹³

Although it is reported that root canal treatment is necessary for mature teeth after transplantation, different opinions have been reported for ideal treatment timing.⁷ There are studies that require endodontic treatment within 7-14 days, as well as studies suggesting that, it should be performed extraoral before transplantation.^{16,17} Since the tooth in our case was immature, the patient was followed up without endodontic treatment. During the 2-year follow-up, it was observed that the tooth was vital and no periapical pathology occurred in the tooth.

Complications reported in the literature are; hypermobility, pulp necrosis, pulp obliteration, root resorption and ankylosis.^{18,19} Pulp obliteration, which is the most frequently reported complication, usually occurs after revascularization (1). It has been reported that only a minority of the root resorption cases observed progressively.²⁰ Progressive root resorption occurs due to the following reasons; damage to periodontal tissues during transplantation, long extraoral time of the tooth, insufficient recipient socket preparation and pressure insertion of the tooth.¹⁸ It has been reported that ankylosis and inflammatory root resorption may develop when rigid fixation is applied to the transplanted tooth. It is also stated that fixation devices can adversely affect oral hygiene and delay healing.¹⁵ Therefore Armstrong et al.⁷ suggested short-term flexible splinting and reported that sutures could be used for this purpose.

CONCLUSION

Autotransplantation is an alternative treatment option that should be considered in single tooth missing, especially in young adults. It is an extremely successful method if it is performed in the appropriate indication. In addition to being affordable, the recovery of the proprioceptive sensation and the ability to be applied in a single session are among the important advantages of the procedure. On the other hand, patients feel better psychologically as they do not use additional prosthetic restorations.

Informed Consent: Written informed consent was obtained from the patients who agreed to take part in the study.

Peer-review: Externally peer-reviewed.

Author Contributions: Concept – F.A., H.A.; Design – F.A., H.A.; Supervision – F.A., H.A.; Resources – F.A., H.A.; Materials – F.A., H.A.; Data Collection and/or Processing – F.A., H.A.; Analysis and/or Interpretation – F.A., H.A.; Literature Search – F.A., H.A.; Writing Manuscript – F.A., H.A.; Critical Review – F.A., H.A.

Conflict of Interest: The authors have no conflict of interest to declare.

Financial Disclosure: The authors declared that this study has received no financial support.

Hasta Onamı: Hastadan Yazılı olarak onam alınmıştır

Hakem Değerlendirmesi: Dış bağımsız.

Yazar Katkıları: Fikir – F.A., H.A.; Tasarım – F.A., H.A.; Denetleme – F.A., H.A.; Kaynaklar –F.A., H.A.; Veri Toplanması ve/veya İşlemesi – F.A., H.A.; Analiz ve/veya Yorum – F.A., H.A.; Literatür Taraması – F.A., H.A.; Yazıyı Yazan – F.A., H.A.; Eleştirel İnceleme – F.A., H.A.

Çıkar Çatışması: Yazarlar çıkar çatışması bildirmemişlerdir.

Finansal Destek: Yazarlar bu çalışma için finansal destek almadıklarını beyan etmişlerdir.

REFERENCES

- Machado L, Do Nascimento R, Ferreira D, Mattos C, Vilella O. Long-term prognosis of tooth autotransplantation: a systematic review and meta-analysis. *Int J Oral Maxillofac Surg.* 2016;45(5):610-617.
- Yavuz MS, Ömezli MM. İmmatür mandibüler 3. moların ototransplantasyonu: iki yıllık olgu takibi. *Türk Klinik J Dental Sci.* 2010;16(1):74-78.
- Schmidt SK, Cleverly DG. Tooth autotransplantation: an overview and case study. *Northwest Dent.* 2012;91(4):29-34.
- Güven Y, Kasımoğlu Y, Aksakal SD, Aktören O, Gençay K. Farklı konumlanmış dişlerde Ototransplantasyon ile tedavi. *Türk Klinik J Dental Sci.* 2019;5(1):28-34.
- Ravi PK, Jyothi M, Sirisha K, Racca K, Uma C. Autotransplantation of mandibular third molar: a case report. *Case Rep. Dent.* 2012;2012:629180.
- Saruhan N, Ertaş Ü, Tepecik T. Ototransplantasyon: vaka serisi. *Curr Res Dent Sci.* 2015;25:45-50.
- Armstrong L, O'Reilly C, Ahmed B. Autotransplantation of third molars: a literature review and preliminary protocols. *Br Dent J.* 2020;228(4):247-251.
- Asif JA, Noorani TY, Alam MK. Tooth auto-transplantation: an alternative treatment. *Bull Tokyo Dent Coll.* 2017;58(1):41-48.
- Czochrowska EM, Stenvik A, Bjercke B, Zachrisson BU. Outcome of tooth transplantation: survival and success rates 17-41 years post-treatment. *Am J Orthod Dentofacial Orthop.* 2002;121(2):110-119.
- Chung WC, Tu YK, Lin YH, Lu HK. Outcomes of autotransplanted teeth with complete root formation: a systematic review and meta-analysis. *J Clin Periodontol.* 2014;41(4):412-423.
- Bello SA, Adeoye J, Ighile N. Short-term survival of molar to molar transplantation in adolescents. *Ann AfSurg.* 2020;17(1): DOI: 10.4314/aas.v17i1.4.
- Ong DV, Dance G. Posterior tooth autotransplantation: a case series. *Aust Dent J.* 2020.
- Yu H, Jia P, Lv Z, Qiu L. Autotransplantation of third molars with completely formed roots into surgically created sockets and fresh extraction sockets: a 10-year comparative study. *Int J Oral Maxillofac Surg.* 2017;46(4):531-538.
- Bae J-H, Choi Y-H, Cho B-H, Kim Y-K, Kim S-G. Autotransplantation of teeth with complete root formation: a case series. *J Endod.* 2010;36(8):1422-1426.
- Mendes RA, Rocha G. Mandibular third molar autotransplantation—literature review with clinical cases. *J Can Dent Assoc.* 2004;70(11):761-766.
- Plotino G, Abella Sans F, Duggal M, Grande N, Krastl G, Nagendraba-bu V, et al. Clinical procedures and outcome of surgical extrusion, intentional replantation and tooth autotransplantation—a narrative review. *Int Endod J.* 2020;53:1636-1652.
- Azevedo PC, Moura CCG, Zanetta-Barbosa D, Bernadineli N. Time of endodontic treatment in autogenic transplants of mature teeth: histological study in dogs. *Oral Surg Oral Med Oral Pathol Oral Radiol Endod.* 2007;104(2):287-293.
- Tsukiboshi M. Autotransplantation of teeth: requirements for predictable success. *Dent Traumatol.* 2002;18(4):157-180.
- Mena-Álvarez J, Riad-Deglow E, Quispe-López N, Rico-Romano C, Zubizarreta-Macho A. Technology at the service of surgery in a new technique of autotransplantation by guided surgery: a case report. *BMC Oral Health.* 2020;20(1):1-8.
- Ashurko I, Vlasova I, Yaremchuk P, Bystrova O. Autotransplantation of teeth as an alternative to dental implantation. *BMJ Case Rep.* 2020;13(6):e234889.