

# Surgical treatment of an extraoral fistula developing due to the left maxillary first molar tooth of which endodontic treatment was performed and infection could not be eliminated

Endodontik tedavisi yapılmış enfeksiyonun giderilemediği sol maksiller birinci molar dişe bağlı gelişen ekstraoral fistülün cerrahi tedavisi

Büşra KOÇ<sup>1</sup>   
Büşra Melda KENGEL<sup>2</sup>   
Esra MAVİ<sup>1</sup> 

<sup>1</sup>Department of Oral And Maxillofacial Surgery, Sivas Cumhuriyet University, Faculty of Dentistry, Sivas, Turkey  
<sup>2</sup>Department of Endodontics, Sivas Cumhuriyet University, Faculty of Dentistry, Sivas, Turkey



## ABSTRACT

Extraoral fistulas are confused with many different formations, especially skin lesions, tuberculosis, and osteomyelitis, and as a result, ineffective treatment can be applied to patients. Differential diagnosis should be made very carefully in these cases to prevent wrong diagnosis and treatment. This study's goal is to summarize the dental diagnosis and treatment options of extraoral fistulization developing due to odontogenic infection. A 22-year-old male patient with no systemic disease applied to Sivas Cumhuriyet University Faculty of Dentistry due to the extraoral fistula in the left maxillary region. According to the dental history of the patient, he had undergone a root canal treatment in tooth number 26 in another institution two years ago. The patient primarily applied to the dermatology clinic. The patient was not treated in the dermatology clinic and was referred to the plastic surgery department. But when it was observed that healing could not be achieved despite three operations, the patient was referred to the dentist. It should definitely be taken into consideration that skin lesions in the face and neck region may be caused by odontogenic infections. The clinical and radiographic examination should be performed carefully in the differential diagnosis, and the appropriate diagnosis should be made. Thus, when a tooth related to the lesion is detected, the use of unnecessary medications and wrong interventions may be avoided by performing the appropriate treatment.

**Keywords:** Extraoral, fistula, chronic, abscess, periradicular tissues.

## ÖZ

Ekstraoral fistüller özellikle deri lezyonları, tüberküloz, osteomyelit gibi birçok farklı oluşumla karıştırılmakta ve bunun sonucunda hastalara etkisiz tedaviler uygulanabilmektedir. Bu olgularda yanlış teşhis ve tedavinin önlenmesi amacıyla ayırıcı tanı çok dikkatli yapılmalıdır. Bu çalışmanın amacı, odontojenik enfeksiyon kaynaklı ağız dışı fistülizasyonun dental teşhis ve tedavi seçeneklerini özetlemektir. Sistemik hastalığı bulunmayan 22 yaşındaki erkek hasta sol üst çene bölgesinde gelişen ekstraoral fistül nedeniyle Sivas Cumhuriyet Üniversitesi Diş Hekimliği Fakültesi'ne başvurmuştur. Kliniğimize başvuran hastadan alınan dental anamnezde 26 numaralı dişine 2 yıl önce başka bir kurumda kök kanal tedavisi yaptırdığı öğrenilmiştir. Hasta öncelikli olarak dermatoloji kliniğine başvurmuştur. Dermatoloji kliniğinde herhangi bir tedavi uygulanmayan hastanın plastik cerrahiye yönlendirildiği öğrenilmiştir. Plastik cerrahide ise yara bölgesinin temizlenerek dikiş atıldığı ancak 3 kere opere edilmesine rağmen iyileşmenin sağlanamadığı görüldüğünde, hasta diş hekimine yönlendirilmiştir. Yüz ve boyun bölgesindeki deri lezyonlarının odontojenik enfeksiyonlardan kaynaklanabileceği mutlaka göz önünde bulundurulmalıdır. Ayırıcı tanıda klinik ve radyografik muayene dikkatlice yapılmalı ve uygun tanı konulmalıdır. Böylece lezyon kaynağı diş tespit edilip, uygun tedavi yapıldığında gereksiz ilaç kullanımı ve yanlış müdahalelerden kaçınılmış olunur.

**Anahtar kelimeler:** Ekstraoral, fistül, kronik, abse, periradiküler dokular.

Received/Geliş Tarihi: 14.10.2020

Accepted/Kabul Tarihi: 19.08.2021

Sorumlu Yazar/Corresponding Author:  
Büşra Melda KENGEL  
E-posta: melda.kengel@gmail.com

Cite this article: Koç B, Kengel MB, Mavi E. Surgical treatment of an extraoral fistula developing due to the left maxillary first molar tooth of which endodontic treatment was performed and infection could not be eliminated. *Curr Res Dent Sci* 2022; 32(1): 124-127



Content of this journal is licensed under a Creative Commons Attribution-NonCommercial 4.0 International License.

## INTRODUCTION

Odontogenic infections are pathological formations that develop due to pulp necrosis. The opening of the fistula into the intraoral or extraoral region depends on the region of the tooth and the localization of the perforation caused by inflammation in the cortical bone.<sup>1</sup> Bacterial virulence, the patient's defense mechanism, the low resistance of connective tissues in the facial region, the relationship of muscle attachments and the infected tooth affect the progression of the fistula.<sup>2</sup> When an infected or necrotic pulp tissue is not treated, the infection in the canal can spread to the periradicular tissues through the apical opening and then to the bone. The location of the opening area of abscesses to the

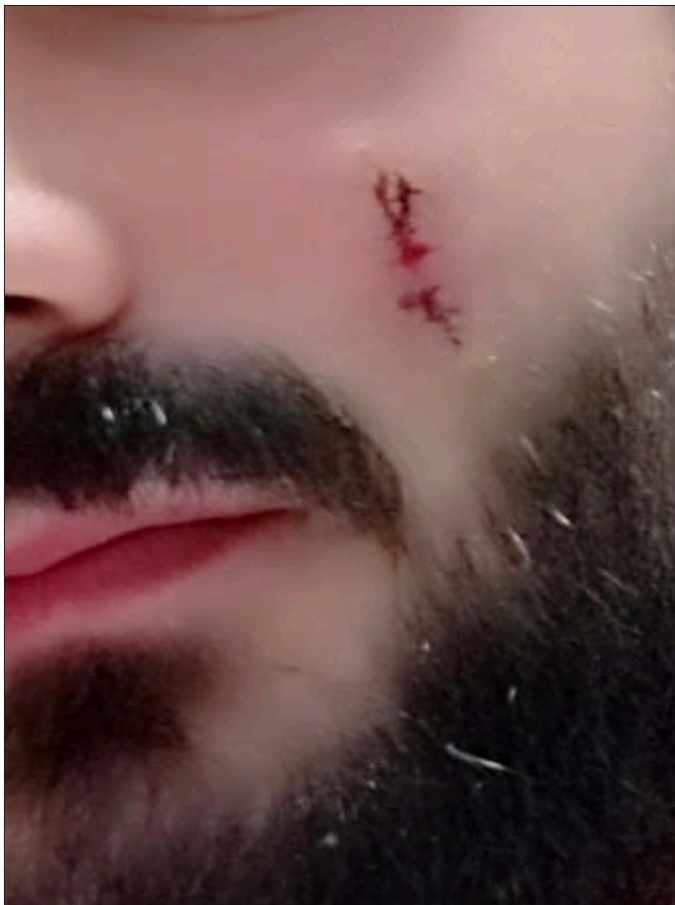extraoral area differs depending on the region where inflammation progresses in the bone and the location of the region where it perforates the cortical layer.<sup>3</sup> Extraoral fistulas are often confused with many formations such as skin lesions, traumatic injury, carcinoma, osteomyelitis, tuberculosis, and actinomycosis, and as a result, ineffective treatment can be applied to patients.<sup>4</sup> Defining this lesion as a fistula tract caused by an odontogenic infection plays a crucial role in making an accurate diagnosis. Faults in diagnosis result in unnecessary surgical treatments and biopsies, long-term antibiotic therapy, and even radiation therapy.<sup>5</sup> In this case report, the diagnosis and treatment of odontogenic infection, in which the infection could not be eliminated and healing could not be achieved as a result of the wrong diagnosis and treatment plan applied by the dermatology and plastic surgery departments to the patient with an extraoral fistula, were discussed.

### CASE PRESENTATION

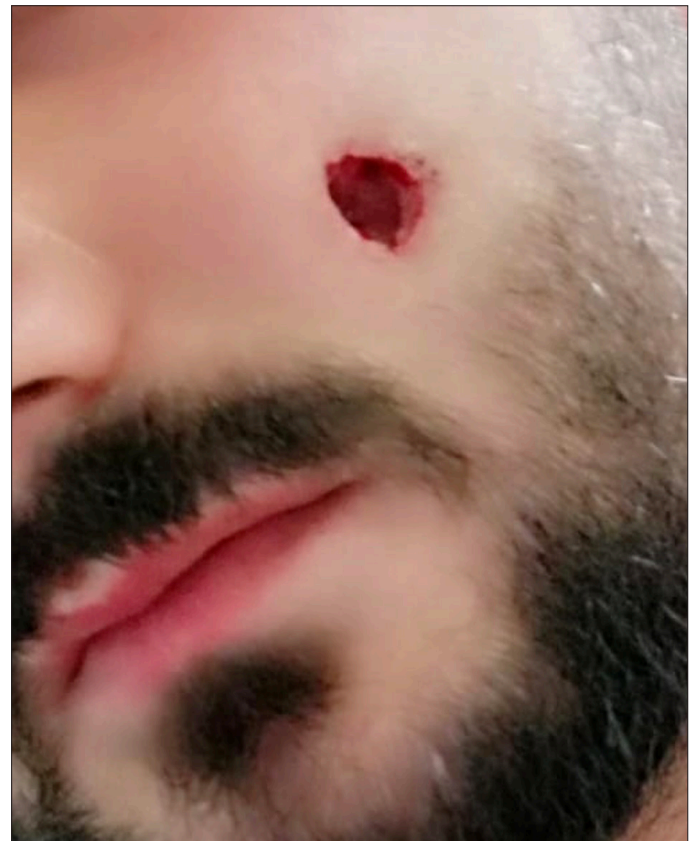
A 22-year-old male patient with no systemic disease applied to Sivas Cumhuriyet University Faculty of Dentistry due to the extraoral fistula in the left maxillary region. According to the dental history of the patient, he had undergone a root canal treatment in tooth number 26 in another institution two years ago. After the root canal treatment, the patient did not have any pain complaints, but swelling developed on the face 3 months ago, and then fistulization occurred. The patient primarily applied to the dermatology clinic. The patient was not treated in the derma-

tology clinic but was referred to the plastic surgery department. In the plastic surgery department, the wound site was cleaned and sutured, but when it was observed that healing could not be achieved despite three operations, the patient was referred to the dentist (Figure 1).

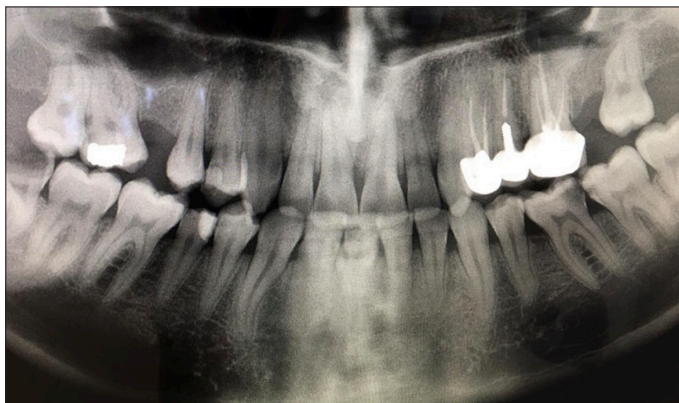
When the extraoral examination of the patient who applied to our clinic was performed, an erythematous and edematous fistula opening, approximately 5 mm in diameter, was detected in the upper left buccal region (Figure 2). During palpation to the center of the fistula tract, exudate outflow from the opening was observed. The radiological examination of the patient was performed primarily with a panoramic film, and it was observed that a lesion developed in the apical region of teeth number 25 and 26 (Figure 3). The perforation area was determined by a more detailed radiological examination of the patient, and cone-beam computed tomography (CBCT) was obtained from the patient to make the correct diagnosis (Figure 4). It was observed that the continuity of the cortical bone was impaired, and the perforation area developed in the region of tooth 26 of the patient whose CBCT was evaluated. It was observed that restoration could not be performed in the patient, whose intraoral examination was performed, due to the loss of material in the relevant tooth, and its extraction was decided to eliminate the focus of infection and provide healing. After the extraction of the tooth, the region was curetted and cleaned and primarily closed with Vicryl suture (Sterilized non-absorbable surgical suture usp, JINHUAN MEDICAL PRODUCTS LTD/P.C.R ), and the dressing was made with Batticon in the fistula region. The patient was prescribed amoxicillin/clavulanic (AMX/CLV) acid 875/125 mg, twice a day (BID)



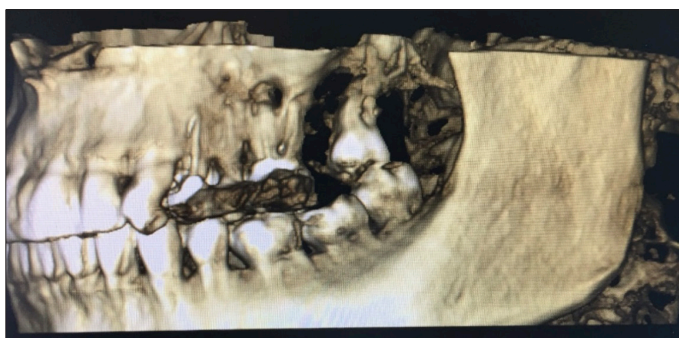**Figure 1.** The first Figure of the patient operated in the plastic surgery clinic.



**Figure 2.** Erythematous extraoral fistula Figure of the patient, 5 mm in diameter, referred to our clinic.



**Figure 3.** In the panoramic film obtained from the patient, it was determined that a lesion developed after the unsuccessful root canal treatment in the left maxillary first molar.

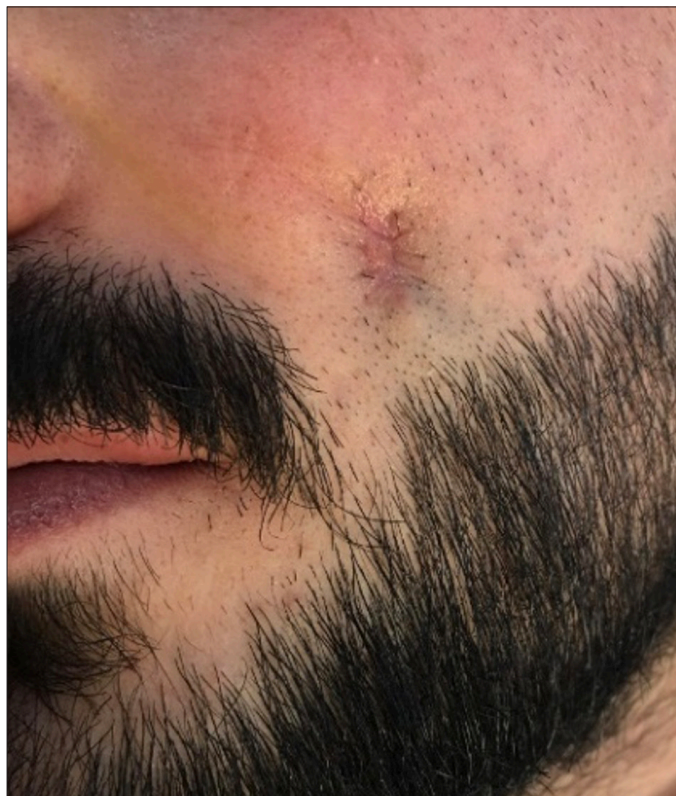

**Figure 4.** CBCT section obtained from the patient.

(Augmentin 1 g 14 tablets, GlaxoSmithKline, Istanbul, Turkey), and analgesic (Arveles 25 mg film tablets, (Menarini, L'Aquila, Italy)) and mouthwash, and postoperative information and recommendations were given to him. An appointment was scheduled one week later to make the control and remove the sutures. One week later, the extraction site healed in the intraoral control of the region, and the sutures were removed. During the extraoral examination, exudate outflow was not observed in the fistula region. In this session, the dressing was made to the region with Batticon (Poviodeks Batikon, Kimpa), and the patient was given a control appointment again two weeks later. When the patient came to the hospital two weeks later, it was observed in the extraoral examination that the fistula closed. There was no pain and swelling in the patient between the control sessions. The patient was given a new control appointment three months later, and during this session, it was observed that the fistula region healed with scar formation and closed completely (Figure 5). After these controls, the patient was referred to the plastic surgery clinic for an aesthetic evaluation of the skin region that healed with scar formation. The plastic surgeon started treatment with Dermatrix silicone gel for the patient and aimed to treat the immature apparent scar with this gel.

## DISCUSSION

The causes of the failure of root canal treatment are now shown as necrotic pulp tissue, broken instruments, flooded root canal filling, mechanical perforations, root fractures, periradicular lesion and periodontal disease, while the most significant reason for the failure is microorganisms in the root canal system. While an apical inflammation caused by bacteria becomes chronic in one individ-



**Figure 5.** The patient's fistula region healed with scar formation and closed.

ual, it can continue with bacteremia, septicemia, and suppuration, which may spread in another individual and pose life threats.<sup>6</sup> Periapical inflammation can remain silent for years, degenerate, heal as a result of root canal treatment, or may become abscessed and spread to various tissues by neighborhood relations. In chronic periapical abscess cases, the patient does not complain of pain because the pressure created by the suppuration resulting from the drainage formed by the fistula tract is eliminated. It is characterized by the presence of a fistula, which is clinically drained to the oral mucosa or, rarely, to the facial skin.<sup>7</sup> Facial areas may be affected when the dental infection spreads to the soft tissue rather than advancing through the oral or cutaneous routes to the surface. Infection may spread to areas far from the dental source by following the path of least resistance across the connective tissue and facial areas.<sup>8-10</sup> Non-surgical approaches should be considered before attempting to surgery.<sup>11</sup> In the case reported in this study, as a result of the unsuccessful root canal treatment of the left maxillary first molar tooth, the infection spread from the periapical region, disrupted the continuity of the cortical bone and resulted in the formation of an extraoral fistula. Medical (antibiotics), surgical or dental treatment (incision and drainage, tooth extraction, or root canal treatment) included in the treatment of odontogenic infections or a combination of these are applied in the treatment of facial area infections.<sup>12</sup> Antibiotic treatment should not be considered as the first treatment option alone but should be used as an adjunct to dental treatment.<sup>13</sup> Antibiotics are indicated to prevent secondary infections and bacteremia in systemically unhealthy cases with fever, malaise, lymphadenopathy, progressive diffuse swelling, and trismus.<sup>14, 15</sup> Therefore, in complicated cases, it is recommended to start empirical treatment with antibiotics, in addition to rapid and aggressive surgical drainage.<sup>16, 17</sup> It is re-

ported that dental fistula openings to the skin may heal spontaneously, and the opening may close within a few weeks when the primary factor is eliminated. This site usually heals by forming a small pit and hyperpigmentation, which decrease over.<sup>18, 19</sup> In this case report, as a result of a detailed dental anamnesis, radiographic examination, and examination of clinical symptoms, the differential diagnosis of the fistula was made, and it was found to be of dental origin. The fact that these cases are asymptomatic or prone to misdiagnosis in some situations necessitates multidisciplinary communication in diagnosis.

## CONCLUSION

It is necessary to always keep in mind that lesions in the extraoral region may be of dental origin. Furthermore, in the case of early diagnosis, the difficulty of the treatment process and the duration of treatment decrease. In this sense, physicians working in endodontics, oral, dental and maxillofacial surgery and dermatology, which are the disciplines associated with the lesion, should cooperate from diagnosis to long-term follow-up in the management of these cases.<sup>4</sup>

**Informed Consent:** Written informed consent was obtained from patient who participated in this study.

**Peer-review:** Externally peer-reviewed.

**Author Contributions:** Concept – B.K., B.M.K.; Design – B.K., B.M.K.; Supervision – B.K.; Resources – B.M.K.; Materials – B.K., B.M.K., E.M.; Data Collection and/or Processing – B.K., B.M.K.; Analysis and/or Interpretation – B.K., B.M.K.; Literature Search – B.K., B.M.K., E.M.; Writing Manuscript – B.K., B.M.K.; Critical Review – E.M.

**Conflict of Interest:** The authors have no conflict of interest to declare.

**Financial Disclosure:** The authors declared that this study has received no financial support.

**Hasta Onamı:** Yazılı hasta onamı bu çalışmaya katılan hastadan alınmıştır.

**Hakem Değerlendirmesi:** Dış bağımsız.

**Yazar Katkıları:** Fikir – B.K., B.M.K.; Tasarım – B.K., B.M.K.; Denetleme – B.K.; Kaynaklar – B.M.K.; Veri Toplanması ve/veya İşlemesi – B.K., B.M.K.; Analiz ve/veya Yorum – B.K., B.M.K., E.M.; Literatür Taraması – B.K., B.M.K., E.M.; Yazıyı Yazan – B.K., B.M.K.; Eleştirel İnceleme – E.M.

**Çıkar Çatışması:** Yazarlar çıkar çatışması bildirmemişlerdir.

**Finansal Destek:** Yazarlar bu çalışma için finansal destek almadıklarını beyan etmişlerdir.

## REFERENCES

- Zan R, Kanmaz F, Akpınar KE, Hubbezoğlu I. Treatment of an extraoral cutaneous sinus tract with endodontic intervention: a case report. *Turk Endod J.* 2016;1(1):39-42.
- Akpınar KE, Er DK, Kuştarcı DA, Özcan DÜ. Odontojenik Fistüllerin Prevalansı ve Tedavi Sonuçları. *Cumhuriyet Üni Dış Hek Fak Derg.* 2004;7(2):6-10.
- İlhan K. Dental Kaynaklı Enfeksiyona Bağlı Cilt Fistülünün Cerrahi Tedavisi: Olgu Sunumu. *Ankara Üni Dış Hek Fak Derg.* 2018;45(3):165-169.
- Işık V, Ersev H. Ekstraoral fistül: Bir olgu sunumu Extraoral fistula: A case report. *Yeditepe Üni Klinik Derg.* 2018;137-139.
- Uysal A, Sezer B, Akay Mc, Ertürk S. Odontojenik Fistüller. *Ege Uni Tıp Derg.* 2004;43(2):121-125.
- Aydın M. Endodontik mikrobiyoloji. *Ed Alaçam T Endodonti.* 2000;13.
- Aşçı SK. *Quintessence Yayıncılık, Endodonti,* 2014;185-205.
- Topazian RG, Goldberg MH, Hupp JR. *Oral and Maxillofacial Infections. 2002. 4th Edition, WB Saunders Company, Philadelphia.*
- Topazian R, Goldberg M. Odontogenic infections and deep fascial space infections of dental origin. *Oral and Maxillofacial Infections.* 2002;3:198-251.
- Fragiskos F. Odontogenic infections. *Oral surgery, Springer.* 2007;205-241.
- Arslan Dh, Topçuoğlu Dhs, Barutçugil Ç, Karataş De, Aladag H, Köseoğlu M ve Ark. Geniş Periapikal Lezyonlu Dişlerin Cerrahi Girişimsiz Kök Kanal Tedavileri. *Curr Res Dent Sci.* 2012;22(1):61-65.
- Peker E, Karaca İR. Odontojenik enfeksiyon kaynaklı fasyal alan apseleri. *Gazi Üni Dış Hek Fak Derg.* 2012;29(2):129-137.
- Bayındır Y. Dental enfeksiyonlarda doğru antibiyotik kullanımı. *İnönü Üni Tıp Fak Derg.* 2003;10(4):213-216.
- Henry M, Reader A, Beck M. Effect of penicillin on postoperative endodontic pain and swelling in symptomatic necrotic teeth. *J Endod.* 2001;27(2):117-123.
- Pickenpaugh L, Reader A, Beck M, Meyers WJ, Peterson LJ. Effect of prophylactic amoxicillin on endodontic flare-up in asymptomatic, necrotic teeth. *J Endod.* 2001;27(1):53-56.
- Gill Y, Scully C. Orofacial odontogenic infections: review of microbiology and current treatment. *Oral Surg Oral Med, Oral Pathol.* 1990;70(2):155-158.
- Daramola OO, Flanagan CE, Maisel RH, Odland RM. Diagnosis and treatment of deep neck space abscesses. *Otolaryngology Head Neck Surg.* 2009;141(1):123-130.
- Sheehan DJ, Potter BJ, Davis LS. Cutaneous draining sinus tract of odontogenic origin: unusual presentation of a challenging diagnosis. *South Med J.* 2005;98(2):250-253.
- Cantatore JL, Klein PA, Lieblich LM. Cutaneous dental sinus tract, a common misdiagnosis: a case report and review of the literature. *Cutis.* 2002;70(5):264-275.