



## CASE REPORT

### Coligranuloma in a pigeon

Reza Kheirandish<sup>1\*</sup>, Mahmood Salehi<sup>2</sup>, Reza Ghanbarpour<sup>1</sup>, Soodeh Alidadi<sup>3</sup>, Nasrin Askari<sup>3</sup>

#### Özet

**Kheirandish R, Salehi M, Ghanbarpour R, Alidadi S, Askari N.** Bir güvercinde koligranüloma. *Eurasian J Vet Sci*, 2012, 28, 4, 237-239

*Escherichia coli* tarafından oluşturulan koligranüloma barsak duvarları, mezenter ve karaciğerde nodüler granüllerle karakterizedir. Mevcut araştırma bir güvercinde makroskopik ve histopatolojik olarak tanısı konulmuş koligranülomayı tanıtmaktadır. Makroskopik olarak karaciğer, uviduk, pankreas ve barsakların serozal yüzeylerinde çok odaklı nodüler lezyonlar gözlemlendi. Histopatolojik inceleme için etkilene organlardan örnekler alınarak boyamalar yapıldı. Hasta organlardan bakteriyel muayene için incelemeler yapıldı. Etkilenen organlardan *E. coli* izolasyonu gerçekleştirildi. Histopatolojik olarak bakteri kolonilerinin etrafında heterofiller, çok çekirdekli dev hücreler, makrofajlar ile lenfositler gözlemlendi. Ayrıca kazeöz nekrozlu tipik granülomalar gözlemlendi. Makroskopik, histopatolojik ve mikrobiyolojik bulgular koligranülomayı doğrulamaktadır. Bilindiği kadarı ile mevcut araştırma güvercinlerde rapor edilen ilk koligranüloma vakasıdır.

#### Abstract

**Kheirandish R, Salehi M, Ghanbarpour R, Alidadi S, Askari N.** Coligranuloma in a pigeon. *Eurasian J Vet Sci*, 2012, 28, 4, 237-239

Coligranuloma is characterized by nodular granulomas in liver, mesentery and walls of intestine and is caused by *Escherichia coli*. This article describes gross and histopathological characteristics of coligranuloma in a pigeon. Grossly, there were observed multifocal nodular lesions on the serosal surface of the intestine, oviduct, pancreas, gizzard and liver. For the histopathological study, tissue samples from the affected organs were taken and stained. The affected organs were processed for the bacteriological examination. *Escherichia coli* was isolated from affected tissues. Histopathologically, there were found typical granulomas with caseation necrosis and bacterial colonies in central area surrounded by lymphocytes, macrophages, multinucleated giant cells and heterophils. Based on gross, histopathological and microbiological findings, coligranuloma was diagnosed. To the best of our knowledge, this is the first report of coligranuloma in pigeon.

<sup>1</sup>Department of Pathobiology, <sup>2</sup>Department of Clinical Sciences, <sup>3</sup>Student of School of Veterinary Medicine School of Veterinary Medicine, Shahid Bahonar University of Kerman, Kerman, Iran

Received: 01.08.2012, Accepted: 17.08.2012

\*kheirandish@uk.ac.ir

Anahtar kelimeler: Koligranüloma, *Escherichia coli*, güvercin

Keywords: Coligranuloma, *Escherichia coli*, pigeon

Colibacillosis refers to any localized or systemic infection caused entirely or partly by *Escherichia coli* (*E. coli*), including colisepticemia, air sac disease (chronic respiratory disease, CRD), swollen-head syndrome, synovitis, cellulitis, salpingitis, pericarditis, peritonitis, ophthalmitis, yolk sac infection and coligranuloma (Hjarre's disease) (Charlton 2000, Banlunara and Lekdamrongsak 2006, Barnes et al 2008). The causative organism is the normal inhabitant of the intestine of the birds and outbreaks occur in poultry raised below standard sanitation, during the course of respiratory or immunosuppressive diseases like infectious bronchitis, mycoplasmosis, infectious laryngotracheitis, and Newcastle disease (Islam et al 2007, Nouri et al 2011). Coligranuloma is an important, but uncommon form of colibacillosis and often sporadically found in adult birds (Chauhan 2003, Barnes et al 2008). Coligranuloma was first explained by Hjarre and Wramby, in 1945, in Sweden, as a rare disease of chickens and turkeys (Mutalib and Riddell 1982, Thiede and Krone 2001, Banlunara and Lekdamrongsak 2006). The disease was characterized by nodular granulomas in liver, mesentery and serosal surface of intestine. The clinical findings of disease are nonspecific (Charlton 2000, Vegad and Katiyar 2003), but often include diarrhea, soiling of cloaca with semi-solid cheesy materials, and death (Chauhan 2003, Islam et al 2007). Until now, coligranuloma had been report in an Amazon parrot (Raphael and Iverson 1980), a free-living bird (common buzzard, *Buteo buteo*) (Thiede and Krone 2001), a captive juvenile Philippine Eagle (*Pithecophaga jefferyi*) (Matawaran et al 1998), a Hyacinth macaw (*Anodorhynchus hyacinthinus*) (Banlunara and Lekdamrongsak 2006) and a coturnix quail flock (Da Silva et al 1989). The purpose of this study was to report on the occurrence of coligranuloma in a pigeon.

An adult female pigeon with the history of anorexia, lethargy and weakness for 6 days, was referred to the Veterinary Clinic of the School of Veterinary Medicine, Shahid-Bahonar University of Kerman, Kerman, Iran. At necropsy, multifocal grayish-white nodules, 2- 5 mm in diameter, in the abdominal cavity including on the serosal surface of the intestine, oviduct, pancreas, liver and gizzard were found (Figure 1). Bacteriologi-

cal sample was obtained and was streaked onto Mac Conkey agar and bovine blood agar (Biolife Laboratories, Milano, Italy). Plates were incubated at 37 °C for 24 hours under aerobic condition. Standard biochemical and bacteriological methods were used to isolate and identify the suspected bacteria. The isolate was confirmed to be *E. coli* by using biochemical API 20E identification system (BioMe'rieux, Marcy l'Etoile, France). For histopathology, tissue samples were taken, fixed in 10% neutral buffered formalin and processed according to the routine of histopathologic techniques. Paraffin Sections at 5 µm thickness were stained with hematoxylin and eosin (H&E), Periodic acid-Schiff (PAS) and Ziehl-Nielsen methods and studied under light microscope. Microscopic examination of the tissue specimens revealed that the nodules were typical granulomas with caseation necrosis in the center and purple colored bacterial colonies surrounded by a zone of massive inflammatory cell infiltration (Figure 2). The inflammatory cells were composed of lymphocytes, macrophages, multinucleated giant cells and heterophils (Figure 3). PAS and Ziehl-Nielsen (acid fast) staining were negative for mycotic forms and acid-fast organisms, respectively. On the basis of gross, histological and microbiological findings, the diagnosis of coligranuloma was made.

Hjarre's disease appears to be a very rare disease, reported occasionally in birds, also has been described in quails (Da Silva et al 1989, Banlunara and Lekdamrongsak 2006). The pathogenesis is unknown, but the route of infection, seems to be gastrointestinal, skin or respiratory tract. Factors including limited feed intake, vitamin A deficiency, parasitic infections and genetic susceptibility have been suggested to be predisposing risk factors for coligranuloma in poultry (Wray and Davies 2001, Banlunara and Lekdamrongsak 2006, Islam et al 2007, Nouri et al 2011). All of these reports suggest that the presence of coligranulomas cannot be explained by infection with alone. However, must have acted as a primary pathogen when the immune sufficiency of the bird was decreased by an immunosuppressive disease (Nouri et al 2011). Coligranuloma can result in emaciation and reduced production that may not be noticed clinically and often is identified during necropsy (Da Silva et

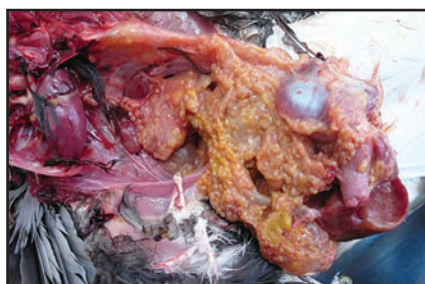

Figure 1. Multifocal small grayish-white nodules in the abdominal cavity the around visceral organs.

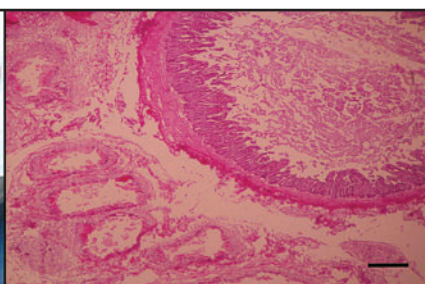


Figure 2. Multiple nodular granulomatous reactions adjacent to the intestines (H&E, Bar=250 µm).

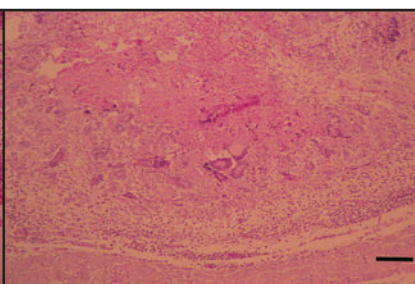


Figure 3. Caseous necrosis is surrounded by chronic inflammatory cells mainly macrophages and giant cells (H&E. Bar=100 µm).

al 1989). This disease can cause mortality as high as 75% when a flock is affected (Shah and Qureshi 2006, Barnes et al 2008). Coligranuloma is explained by multiple granulomas in liver, duodenum, cecum and mesentery but not in the spleen (Mutalib and Riddell 1982, Banlunara and Lekdamrongsak 2006, Shah and Qureshi 2006, Islam et al 2007). Pyogranulomatous typhlitis and hepatitis, which may be related to coligranuloma, have been described in turkeys with ruptured ceca (Morishita and Bickford 1992, Barnes et al 2008). Early in the disease, there is caseation necrosis involving as much as half the liver. At the edge of the necrotic areas are a few giant cells, macrophages and lymphocytes. Subsequently, typical granulomas are present in the affected tissues (Islam et al 2007, Barnes et al 2008).

The tuberculosis and mycotic granulomas are similar to those of coligranuloma, but they must be differentiated by Ziehl-Nielsen (acid fast) and PAS staining, respectively, which are negative for *E. coli* (Banlunara and Lekdamrongsak 2006, Islam et al 2009, Nouri et al 2011). The disease usually is diagnosed on the basis of clinical signs, necropsy findings, histopathological examinations, the isolation and identification of organisms by bacteriological examination, the positive therapeutic response of the affected flocks to antibiotics such as colistin sulphate, oxytetracycline, fluoroquinolones, neomycin, etc (Islam et al 2007, Islam et al 2009).

In case reports of a common buzzard, a captive juvenile Philippine Eagle (*Pithechophaga jefferyi*), an Amazon parrot and a Hyacinth macaw (*Anodorhynchus hyacinthinus*), the granulomas were shown in the liver, intestine, spleen, pancreas, brain and has not been identified in other organs (Raphael and Iverson 1980, Da Silva et al 1989, Matawaran et al 1998, Thiede and Krone 2001, Banlunara and Lekdamrongsak 2006).

This pigeon showed lesions in the liver, oviduct and intestinal tract, pancreas and gizzard. In this report, diagnosis of coligranuloma was made based on histopathologic, gross and microbiological features. This study seems to be the first reported case of coligranuloma in pigeon.

#### ► Acknowledgement

The authors wish to thank Mr. Hassan Zadeh for his technical assistance.

#### ► References

- Banlunara W, Lekdamrongsak T, 2006. Hjarre's disease in a Hyacinth macaw (*Anodorhynchus hyacinthinus*). *AZ-WMP*, 62.
- Barnes HJ, Nolan LK, Vaillancourt JP. 2008. Colibacillosis, in: *Diseases of poultry*, Eds; Saif YM, Fadly AM, Glisson JR, McDougald LR, Nolan LK, Swayne DE, 12th edition, Blackwell Publishing, Ames, IA, USA, pp: 691-732.
- Charlton BR, 2000. Bacterial diseases, in: *Avian Disease Manual*, 5th edition, The American Association of Avian Pathologists, USA, pp: 115-117.
- Chauhan RS, 2003. Bacterial diseases, in: *Illustrated Special Veterinary Pathology*, International Book Distribution Co, UP, India, pp: 245-247.
- Da Silva PL, Coelho HE, Ribeiro SC, Oliveira PR, 1989. Occurrence of coligranulomatosis in coturnix quail in Uberlandia, Minas Gerais, Brazil. *Avian Dis*, 33, 590-593.
- Islam MN, Fatema BZ, Faruk MI, 2007. Hjarre's disease in chickens: Clinical, pathological, microbiological and therapeutic findings. *Bangl J Vet Med*, 5, 49-53.
- Islam MN, Rashid SMH, Juli MSB, Rima UK, Khatun M, 2009. Pneumomycosis in chickens: Clinical, pathological, microbiological and therapeutical investigation. *Int J Sustain Crop Prod*, 4, 16-21.
- Matawaran VA, Endaya BB, Torno CS, Mundita Sison Lim T, 1998. Coligranuloma (Hjarre's disease) in a captive juvenile Philippine Eagle (*Pithechophaga jefferyi*). *Philipp J Vet Med*, 35, 76-79.
- Morishita TY, Bickford AA, 1992. Pyogranulomatous typhlitis and hepatitis of market turkeys. *Avian Dis*, 36, 1070-1075.
- Mutalib AA, Riddell C, 1982. Cecal and hepatic granulomas of unknown etiology in chickens. *Avian Dis*, 26, 732-740.
- Nouri M, Gharagozlou MJ, Azarabad H, 2011. Lymphoid leucosis and coligranuloma in a budgerigar (*Melopsittacus undulatus*). *Int J Vet Res*, 5, 5-8.
- Raphael BL, Iverson WO, 1980. Coligranuloma and psittacosis in an Amazon parrot. *JAVMA*, 177, 927-929.
- Shah KA, Qureshi S, 2006. Clinical study on Hjarre's disease in poultry. *Vet Scan* 1, 2, Article 7. Accessed at: 01.08.2012
- Thiede S, Krone O, 2001. Polygranulomatosis in a common buzzard (*Buteo buteo*) due to *Escherichia coli* (Hjarre's disease). *Vet Rec*, 149, 774-776.
- Vegad JL, Katiyar AK, 2003. Bacterial diseases, in: *A Textbook of Veterinary Special Pathology (Infectious Diseases of Livestock and Poultry)*, International Book Distribution Co, UP, India, pp: 178-181.
- Wray C, Davies RH, 2001. Enterobacteriaceae, in: *Poultry Diseases*, Eds; Jordan F, Pattison M, Alexander D, Faragher T, 5th edition, W. B. Saunders, Philadelphia, PA, USA, pp: 95-130.