



RESEARCH ARTICLE

The prevalence and pathology of ovine coccidiosis in Kerman, Iran

Reza Kheirandish^{1*}, Saeid R Nourollahi-Fard¹, Elham Eslah²

Özet

Kheirandish R, Nourollahi-Fard SR, Eslah E. İran'ın Kerman bölgesi koyun koksidiozisinin patoloji ve prevalansı. *Eurasian J Vet Sci*, 2012, 28, 4, 194-198

Amaç: Araştırma amacı güneydoğu İran'ın Kerman bölgesi koyunlarında *Eimeria* enfeksiyonunun varlığını araştırmaktır.

Gereç ve Yöntem: Toplam 227 koyundan doğrudan dışkı örnekleri alındı. Dışkı örneklerinde ookist varlığı flotasyon tekniği ile araştırıldı. Her bir gram dışkıda ookist varlığı ve *Eimeria* türleri tanımlandı.

Bulgular: Yedi farklı *Eimeria* (*E. crandallis*, *E. ovina*, *E. parva*, *E. ovinoidalis*, *E. faurei*, *E. ahsata* ve *E. intricata*) türü identifiye edildi. Koksidiozun prevalansında koyunların yaş ve cinsiyetinin önemli olmadığı ($p>0.05$) belirlendi.

Conclusion: Koyunlarda *Eimeria* enfeksiyonunun varlığı belirlendi ve antikoksidial uygulamalar önerilebilir.

Abstract

Kheirandish R, Nourollahi-Fard SR, Eslah E. The prevalence and pathology of ovine coccidiosis in Kerman, Iran. *Eurasian J Vet Sci*, 2012, 28, 4, 194-198

Aim: This study was undertaken to determine *Eimeria* infection in sheep in Kerman province.

Material and Methods: Totally 227 faecal samples were collected directly from the rectum of sheep. Faecal samples were analyzed using floatation technique for the presence of coccidian oocysts. Oocysts per gram of feces and *Eimeria* species were identified.

Results: Seven species of *Eimeria* (*E. crandallis*, *E. ovina*, *E. parva*, *E. ovinoidalis*, *E. faurei*, *E. ahsata* and *E. intricata*) were identified. The age and sex of the sheep had no significant ($p>0.05$) effects on prevalence of coccidiosis.

Conclusion: *Eimeria* infection was prevalent in sheep and anticoccidial treatments should be recommended.

¹Department of Pathobiology, ²Graduated Student, Veterinary School of Shahid-Bahonar University of Kerman, Iran

Received: 29.08.2012, Accepted: 12.09.2012

*kheirandish@uk.ac.ir

Anahtar kelimeler: Prevalans, koksidioz, koyun

Keywords: Prevalence, coccidiosis, sheep

► Introduction

Coccidiosis is an economically important disease which is caused by obligate intracellular protozoa, *Eimeria*; with a worldwide distribution (Bastiani et al 2012, Chartier and Paraud 2012). It seems to be a serious threat to animal health and results in economic impact on the animal husbandry due to high morbidity, mortality and costs of treatment (Zachary and McGavin 2011, Bastiani et al 2012). 15 *Eimeria* species considered to have the capability of infecting sheep are *E. ahsata*, *E. bakuensis*, *E. crandallis*, *E. faurei*, *E. granulosa*, *E. gonzalezi*, *E. gilruthi*, *E. intricata*, *E. marsica*, *E. ovinoidalis*, *E. pallida*, *E. parva*, *E. weybridgei*, *E. punctata* and *E. gilruthi* (Silva et al 2008). 14 species infect the sheep intestine and in one species (*E. gilruthi*) the abomasums is target tissue (Kaya 2004). *E. ovinoidalis*, *E. bakuensis* and *E. ahsata* are the most pathogenic species in small ruminants. All ages of sheep are susceptible to *Eimeria* infection but lambs are the most severely affected by clinical coccidiosis and disease outbreaks (Khan et al 2011). Some conditions such as poor hygienic situations, cold and wet weather, dietary changes, prolonged travel and overcrowded conditions may result in the development of higher level of infection (Chartier and Paraud 2012, Tylor 2012). *Coccidia* (*Eimeria* spp.) infection is common in sheep in Iran, but a few data are available about responsible *Eimeria* species and their prevalent of intensity (Yakhchali and Zarei 2008).

Furthermore, the aims of were to determine the prevalence of coccidiosis and effect of age and sex parameters on frequency of disease and variation of *Eimeria* species in different age groups of sheep and pathology of coccidiosis in sheep. To present date, this is the first investigation on prevalence of different *Eimeria* species in affected sheep of Kerman province, the southeast part of Iran.

► Materials and Methods

• Sample collection

A total of 227 faecal samples (58 males, 169 females) were collected directly from the rectum of sheep, in a period of one year (2009-2010) and stored at 4 °C un-

til examination. Sheep were selected randomly from the slaughtered animals in Kerman slaughterhouse and divided to 4 different age groups; less than 12 months, 1-2 years old, 2-3 years old and over 3 years old.

• Parasitological examination

Faecal samples (3-5 g) were analyzed using floatation technique with saturated sucrose for the presence or absence of coccidian oocysts. Quantitative fecal examination was performed by McMaster technique to determine the number of oocysts per gram of feces (OPG). *Eimeria* species were identified following sporulation of faeces in a thin layer of 2.5% potassium dichromate for one or two weeks at 27 °C. Identification of *Eimeria* species was based on the morphological features of the oocysts (size, shape, color, presence or absence of micropyle and its cap).

• Pathologic examination

For pathological study, appropriate tissue samples were taken from the distal duodenum, jejunum, ileum, ileocecal valve, distal cecum, colon and rectum. All samples were fixed in 10% neutral buffered formalin, embedded in paraffin, sectioned at 5 µm thicknesses, and stained with hematoxylin-eosin (H&E) for light microscopic examination.

• Statistical analysis

Data were analyzed using a Chi-square test and a p-value less than 0.05 value of $p < 0.05$ was considered as significant (SPSS 11.5, Inc., Chicago).

► Results

The oocysts of *Eimeria* spp. were found in 197 of the 227 sheep (86.79%). 128 out of 197 infected sheep (56.38%) had mixed infections with at least two species. Seven species of *Eimeria* (*E. crandallis*, *E. ovina*, *E. parva*, *E. ovinoidalis*, *E. faurei*, *E. ahsata* and *E. intricata*) were identified (Figure 1). The sex and age of the sheep had no significant ($p > 0.05$) effect on prevalence of disease. There was no significant difference in OPG during four seasons (Table 1, 2).

At necropsy, gross lesions were seen mostly in the je-

Table 1. Prevalence of coccidial infection (OPG) in different ages and seasons in sheep.

Season	< 1 year		1-2 year		2-3 year		>3 year	
	Total samples	Positive samples (%)	Total samples	Positive samples (%)	Total samples	Positive samples (%)	Total samples	Positive samples (%)
Spring	8	8 (100%)	12	12 (100%)	7	6 (85.7%)	35	32 (91.4%)
Summer	20	19 (95%)	11	10 (90.9%)	15	11 (73.3%)	2	2 (100%)
Autumn	9	9 (100%)	6	6 (100%)	7	7 (100%)	4	4 (100%)
Winter	15	14 (93.3%)	29	20 (68.9%)	27	24 (88.8%)	23	16 (69.5%)
Total	52	50 (96.2%)	58	48 (82.6%)	56	48 (85.7%)	64	54 (84.4%)

Table 2. Intensity of coccidial infection in different ages and seasons in sheep.

Season	< 1 year	1-2 year	2-3 year	>3 year
Spring	325	250	442	1617
Summer	1705	1818	346.6	150
Autumn	8466	7316	7557	6150
Winter	6785	1441	1033	508.6

junum, ileum and sometimes in cecum. Observed findings were including multifocal mucosal thickening of the jejunum, ileum, and lesser the cecum and proximal colon with scattered small white or grey plaques (Figure 2). These foci were nodular form, non-pedunculated in 3 mm to 1 cm diameter that were raised into the intestinal lumen, and sometime were visible from the serosal surface of intestine especially in the cases with larger nodules. In histopathological examination, the affected tissues revealed proliferative enteritis in varied degrees from mild to severe in different cases (Figure 3). In severe cases, multiple discrete, raised polypoid nodules were present in the mucosal surface. These nodules were characterized by remarkable papillary hyperplasia of the epithelium of crypts and villi. Inflammatory cells including lymphocytes, plasma cells, macrophages, and eosinophils were infiltrated in the lamina propria. Mucosa adjacent to polypoid nodules showed no histopathological changes. Numerous intracellular developmental stages of *Eimeria* including trophozoites, schizonts, microgamonts, macrogametes and oocysts were seen in the epithelium of the affected Lieberkuhn glands,

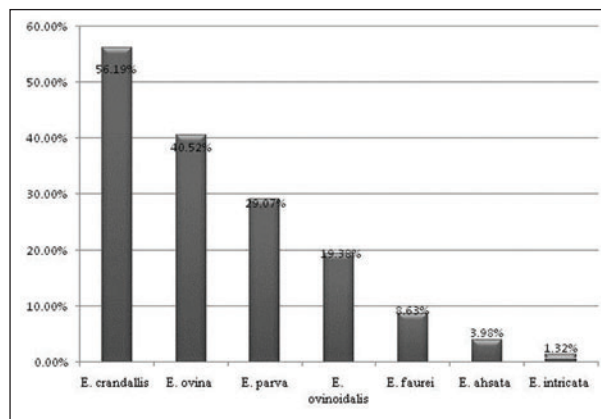


Figure 1. Prevalence of *Eimeria* spp. exhibited by oocysts in sheep.

villi and crypts (Figure 4-7). Immature forms of developmental stages were not easily identifiable.

► Discussion

Coccidial infection in sheep and goats is a protozoan parasitic worldwide disease. On the whole, 15 species of *Eimeria* have been identified in sheep. The prevalence rate and infective species of *Eimeria* is different in various geographical situations in according to the climate, temperature and amount of rain in different seasons, age, immune system of host, unhygienic conditions and rearing systems (Balicka 1999). In current investigation, the prevalence of coccidiosis was obtained 86.79% in sheep. Seven *Eimeria* species including *E. crandallis*, *E. ovina*, *E. parva*, *E. ovinoidalis*, *E. faurei*, *E. ahsata* and *E. intricata* were diagnosed in affected animals (Figure 1). In previous studies in

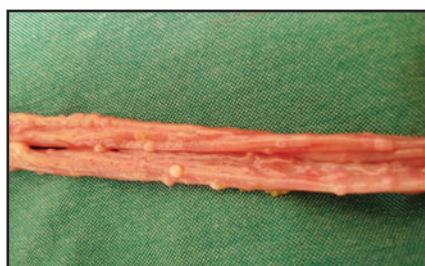

Figure 2. Ileum. Multiple nonpedunculated polyp like lesions.

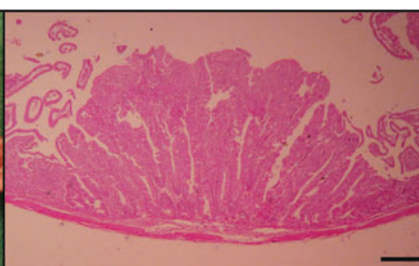


Figure 3. Ileum. Proliferative enteritis. HE. Bar=250µm.

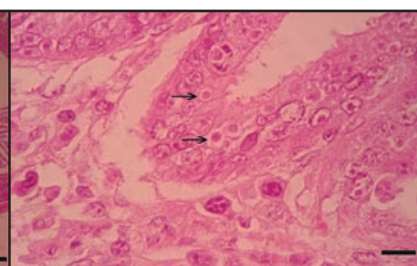


Figure 4. Trophozoites with a round nucleus are located within a parasitophorous vacuoles (arrows) in the cytoplasm of epithelial cell (H&E, Bar=10 µm).

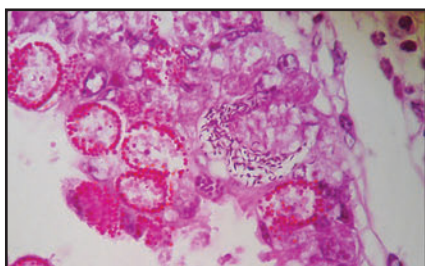


Figure 5. Developmental stages of *Eimeria*. Schizont with numerous crescent-shaped merozoite (arrow) and several macrogametes with peripheral eosinophilic plastic granules are seen (H&E, Bar=25 µm).

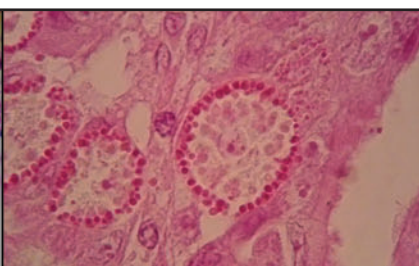


Figure 6. Macrogametes are characterized by a central nucleus and peripheral eosinophilic plastic granules (H&E, Bar=10 µm).

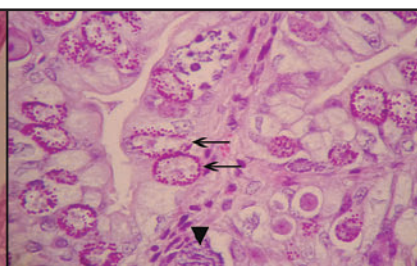


Figure 7. Developmental stages of *Eimeria*. Macrogametes with peripheral eosinophilic plastic granules (arrows) and microgamont with basophilic nuclei (arrowhead) are seen (H&E, Bar=25 µm).

Iran, Yakhchali and Zarei (2008) recognized 6 *Eimeria* species (*E. intricate*, *E. ovina*, *E. faurei*, *E. parva*, *E. ahsata*, *E. pallida*) in sheep of Tabriz province. Also, in other report from Sanandaj, Iran, Yakhchali and Gholami (2008) studied coccidiosis in sheep and detected 6 *Eimeria* species (*E. ovinoidales*, *E. faurei*, *E. ahsata*, *E. parva*, *E. ovina*, *E. intricata*). In Saudi Arabia, Toulah et al (2007) reported 41% infection with coccidiosis in affected sheep and identified 4 *Eimeria* species (*E. parva*, *E. intricate*, *E. arloingi*, *E. ovina*). In a study in Turkey by Kaya (2004), *E. crandallis* reported as predominant infective species in lambs. In Iceland, reported species of coccidian were *E. ahsata*, *E. bakuensis*, *E. crandallis*, *E. faurei*, *E. granulosa*, *E. intricate*, *E. ovinoidales*, *E. pallida*, *E. parva* and *E. weybridgensis* (Reginsson and Richter 1997, Skirnisson 2007). In study of Reginsson and Richter (1997), *E. crandallis* and *E. ovonoidalis* were the most predominant in on one-month-old lambs. Similar to the present study (Figure 1), *E. crandallis* was the most commonly species in affected sheep. In South Africa, 6 *Eimeria* species (*E. crandallis*, *E. bakuensis*, *E. weybridgensis*, *E. ahsata*, *E. intricate*, *E. ovinoidalis*) were recovered from the sheep by Bakunzi et al (2010) that the most frequently occurring species in sheep were *E. crandallis* and *E. bakuensis*. In agreement with our report, the common pathogenic *Eimeria* species was *E. crandallis*. In Brazil, *E. ovina*, *E. ahsata*, *E. crandallis*, *E. faurei*, *E. intricata*, *E. ovinoidalis*, *E. pallid*, *E. parva* and *E. granulose* were reported in sheep (Andrade Junior et al 2012). In Germany, Dittmar et al (2010) identified 12 *Eimeria* species (*E. ahsata*, *E. bakuensis*, *E. crandallis*, *E. faurei*, *E. granulosa*, *E. intricata*, *E. marsica*, *E. ovinoidalis*, *E. pallida*, *E. parva*, *E. punctuate*, *E. weybridgensis*). They stated coccidiosis increased non-significantly with the age of sheep. In the current study, mixed infection with three or four *Eimeria* species was more commonly seen than infection with a single *Eimeria* species, similar to findings of other researchers (Toulah 2007, Yakhchali and Gholami 2008, Yakhchali and Zarei 2008, Wang et al 2010). A study conducted in southern Brazil revealed that 59 % of faecal samples from sheep were positive for the genus *Eimeria* (Silva et al 2008).

In the present study, histopathologic findings of coccidiosis including papillary hyperplasia of intestinal villi and presence of different coccidial stages in epithelial were similar to previous surveys (Brown et al 2007, Khodakaram Tafti and Mansourian 2008, Zachary and McGavin 2011).

► Conclusions

The present survey revealed a high significant prevalence of coccidial infection in sheep and necessity to carry out control programs. Further studies should be performed to reveal more information about the economic effects of this parasite which would be useful

for establishing control and management programs.

► Acknowledgements

This research was financially supported by the research council of Shahid Bahonar University of Kerman, Iran. We wish to thank Mr. Hasanzadeh for their technical assistance.

► References

- Andrade Junior ALF, Silva PC, Aguiar EM, Araujo Santos FG, 2012. Use of coccidiostat in mineral salt and study on ovine eimeriosis. *Rev Bras Parasitol Vet Jaboticabal*, 21, 16-21.
- Bakunzi FR, Thwane SN, Motsei LE, Dzoma BM, 2010. Diversity and seasonal occurrence of *Eimeria* species in a mixed flock of communally reared sheep and goats in Mafikeng in the NorthWest Province, South Africa. *J S Afr Vet Assoc*, 81, 148-150.
- Balicka-Ramis A, 1999. Studies on coccidiosis in goats in Poland. *Vet Parasitol*, 81, 347-349.
- Bastiani FT, Silva AS, Duck MRK, Tonin AA, Monteiro SG, 2012. Outbreak of eimeriosis and giardiasis associated to mortality of lambs in southern Brazil. *Comp Clin Pathol*, DOI 10.1007/s00580-012-1467-9.
- Brown CC, Baker DC, Barker IK, 2007. The alimentary system. In: Jubb MMG (Ed.), *Kennedy and Palmer's Pathology of Domestic Animals*, 5th edition, Saunders Elsevier, UK, pp: 264-267.
- Chartier C, Paraud C, 2012. Coccidiosis due to *Eimeria* in sheep and goats, a review. *Small Ruminant Res*, 103, 84-92.
- Dittmar K, Mundt HC, Grzonka E, Dausgchies A, Bangoura B, 2010. Ovine coccidiosis in housed lambs in Saxony-Anhalt (Central Germany). *Berl Munch Tierarztl*, 123, 49-57.
- Kaya G, 2004. Prevalence of *Eimeria* species in lambs in Antakya province. *Turk J Vet Anim Sci*, 28, 687-692.
- Khan MN, Rehman T, Iqbal Z, Sajid MS, Ahmad M, Riaz M, 2011. Prevalence and associated risk factors of *Eimeria* in sheep of Punjab, Pakistan. *WASET*, 79, 443-447.
- Khodakaram Tafti A, Mansourian M, 2008. Pathologic lesions of naturally occurring coccidiosis in sheep and goats. *Comp Clin Pathol* 17, 87-91.
- Maingi N, Munyua WK, 1994. The prevalence and intensity of infection with *Eimeria* species in sheep in Nyandarua district of Kenya. *Vet Res Commun*, 18, 19-25.
- Ozidal N, Tanritanir P, Goz Y, Deger S, Kozat S, 2009. Parasitic protozoans (*Eimeria*, *Giardia* and *Cryptosporidium*) in lambs with diarrhea in the Van province (Turkey). *Bull Vet Inst Pulawy*, 5, 47-51
- Reginsson K, Richter SH, 1997. Coccidia of the genus *Eimeria* in sheep in Iceland. *Icel Agr Sci*, 11, 99-106.
- Silva FRC, Souza JD, Fialho CG, Escopeli KS, Araujo FAP, 2008. Identification of *Eimeria* species in sheep in Mostardas, southern Brazil. *Veterinaria Em Foco*, 6, 16-20.
- Skirnisson K, 2007. *Eimeria* spp. (Coccidia, Protozoa) infections in a flock of sheep in Iceland: Species composition and seasonal abundance. *Agric Sci*, 20, 73-80.
- Taylor MA, 2012. Emerging parasitic diseases of sheep. *Vet Parasitol*, 2012, (in press).

- Toulah FH, 2007. Prevalence and comparative morphological study of four *Eimeria* spp. Sheep in Jeddah area, Saudi Arabia. *J Biol Sci*, 7, 413-416.
- Wang CR, Xiao JY, Chen AH, Chen J, Wang Y, Gao JF, Zhu XQ, 2010. Prevalence of coccidial infection in sheep and goats in northeastern China. *Vet Parasitol*, 174, 213-217.
- Yakhchali M, Golami E, 2008. *Eimeria* infection (Coccidia: Eimeriidae) in sheep of different age groups in Sanandaj city, Iran. *Vet Arhiv*, 78, 57-64.
- Yakhchali M, Zarei MR, 2008. Prevalence of *Eimeria* infection in sheep of Tabriz suburb, Iran. *IJVR*, 9, 277-280.
- Zachary JF, McGavin MD, 2011. *Pathologic basis of veterinary disease*. 5th edition, Elsevier Mosby, London, UK, pp: 28-29.