

COLOR DOPPLER SONOGRAPHY IN THE DIFFERENTIAL DIAGNOSIS OF UTERINE MASSES

(Received 12 December, 1993)

M. Üstün, M.D. / Ş. Erkılınç, M.D.*** / A. Gülkılık, M.D.*
N. Solak, M.D.** / E. Erdiř, M.D.** / B. Arsan, M.D.****

- * Assistant Professor, Department of Gynecology and Obstetrics, Bakırk y Maternity Hospital, İstanbul, Turkey.
- ** Specialist, Department of Gynecology and Obstetrics, Bakırk y Maternity Hospital, İstanbul, Turkey.
- *** Resident, Department of Gynecology and Obstetrics, Bakırk y Maternity Hospital, İstanbul, Turkey.

SUMMARY

In this study the impedance to blood flow was examined by color Doppler sonography in fifty uterine masses before exploratory laparotomy. After measuring the Resistance Index (RI) of the vessels in the neovascularization area in the mass, these values were compared with the pathology reports of each mass after surgery.

It was seen that neovascularization area was present in all of the eight malignant cases. RI values were less than 0.40 (the limit value) in all of the malignant cases. Neovascularization area was present in 38 (90%) of the 42 benign cases and all RI values were greater than 0.40 in these cases (average 0.65). The sensitivity and specificity of preoperative RI in detecting uterine malignancy were 100 %.

Our results suggest that color Doppler sonography is a useful clinical tool in the preoperative evaluation of uterine masses.

Key Words : Color Doppler sonography, Uterine masses.

INTRODUCTION

It is possible to examine the endometrium and myometrium layers of the uterus today in detail by the ultrasound and detect a uterine mass (1,2). Data from recent studies suggest that the measurements of endometrial thickness obtained by using transvaginal sonography can have both high positive and negative predictive values for uterine malignancy (3,4). There is however a significant false positive rate.

Recent reports have shown that, in the presence of malignant tissue, the impedance to blood flow within the uterine artery is reduced significantly when compared to control groups (5). These data were compared to measurements of endometrial thickness from the same groups of women. It was seen that by using color Doppler, while maintaining sensitivity, the false positive rate of the ultrasound based test is reduced (5). The sensitivity is enhanced if color Doppler is used to interrogate the endometrium in such cases and measure RI of the vessels in the neovascularization area (6).

The purpose of this study is to evaluate the accuracy of color Doppler sonography for predicting malignancy of uterine masses.

MATERIALS AND METHODS

Fifty patients in the study were referred for transabdominal color Doppler sonography after an uterine mass was identified on conventional transabdominal and transvaginal sonography. The age range was 30-66 years with a mean of 43 years.

Examinations were made by using a PVF 357 MT 3.75 MHz probe attached to a Toshiba SSA-270 A scanner. After finding the vascularized areas in the mass by color flow imaging, pulsed Doppler was used to analyze the blood velocity at these areas. Resistance index (RI) was calculated to quantify the impedance to blood flow.

Measurements were repeated for at least three separate cardiac cycles and the lowest resistance index was taken to be representative of the mass.

Masses examined were removed surgically 1-2 days after color Doppler sonographic examination. The benign or malignant nature of the uterine mass was confirmed by histopathology.

The sensitivity, specificity, and both positive and negative predictive values for detecting malignant uterine tumors were determined. Chi-square test was used to compare the RI values of the 8 histopathologically malignant masses with the 42 benign masses.

RESULTS

Forty-two women had benign and eight had malignant uterine tumors by histopathologic examination (Table I and II).

Neovascularization area was detected sonographically in all of the malignant masses. RI was less than 0.40 in all of these malignant masses (Figs. 1 and 2).

Neovascularization area was detected in 38 (90%) of the benign masses. RI was greater than 0.40 in all of these cases (Fig.3).

In general the average resistance index of benign uterine masses (0.66 ± 0.09) was statistically different from malignant masses (0.37 ± 0.02) ($p < 0.001$).

The sensitivity, specificity, positive predictive value and the negative predictive value of color Doppler sonography in detecting uterine malignancy were all 100 %.

Table I- Color Doppler assessment of benign uterine masses.

Histopathology	No.	Neovascularization present	RI
Myoma	37	33 (89%)	0.66
Adenomyosis	5	5 (100%)	0.67
	<u>42</u>	<u>38 (90%)</u>	<u>0.66 ± 0.09</u>

Table II- Color Doppler assessment of malignant uterine masses.

Histopathology	No.	Neovascularization present	RI
Adenocarcinoma	6	6 (100%)	0.36
Undifferentiated carcinoma	1	1 (100%)	0.40
Epidermoid Ca	1	1 (100%)	0.40
	<u>8</u>	<u>8 (100%)</u>	<u>0.37 ± 0.02</u>

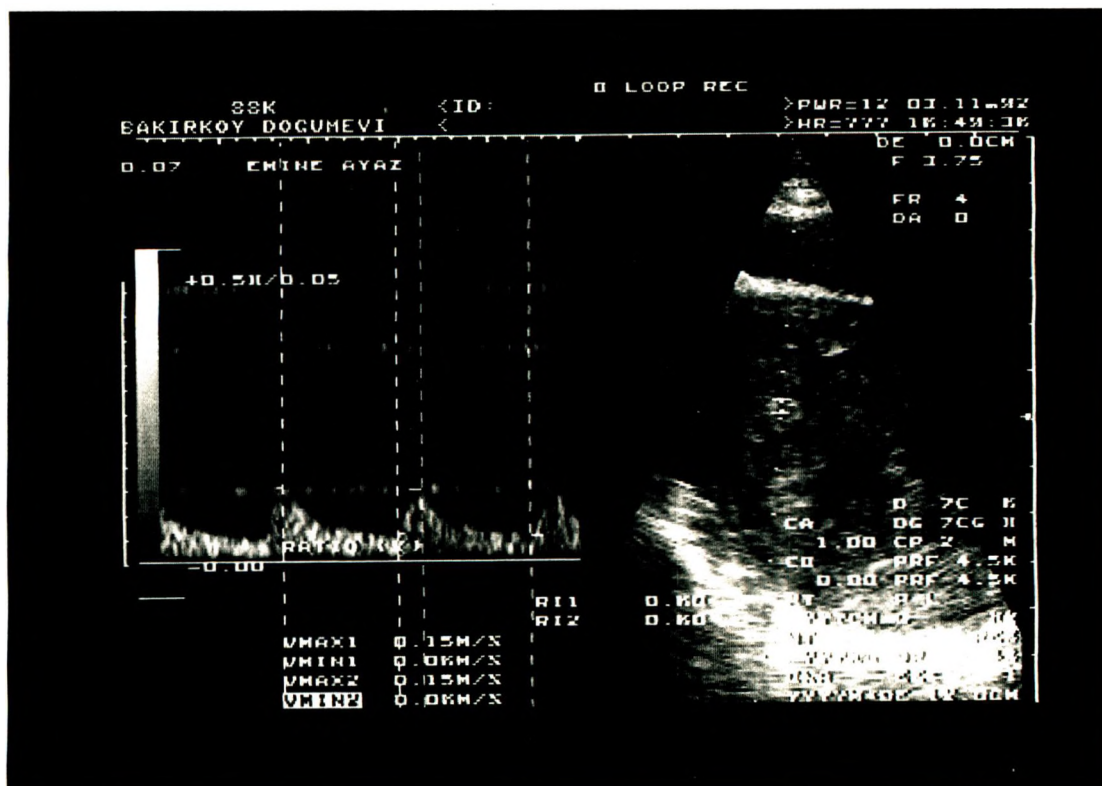


Fig 1. The RI of the vessels in this uterine mass was measured as 0.60. The histopathological diagnosis was uterine myoma.

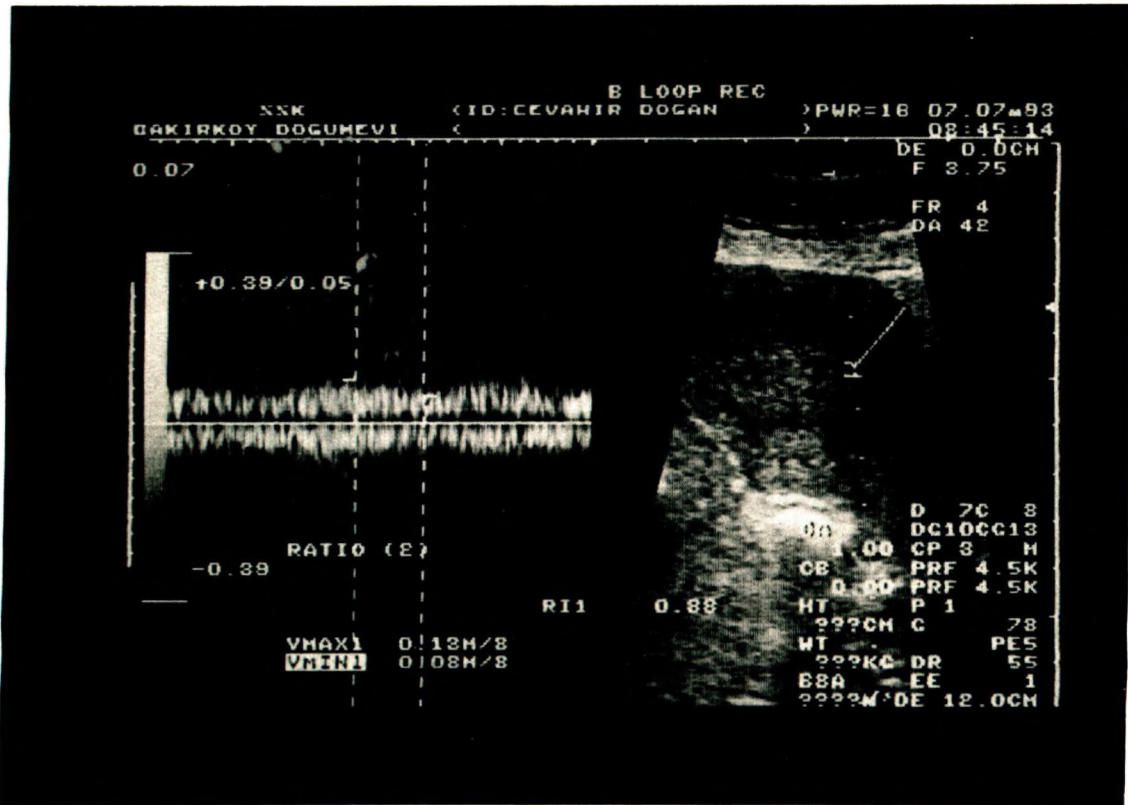


Fig 2. The RI of the vessels at the neovascularization area in the mass was measured as 0.38. The histopathological diagnosis was papillary adenocarcinoma.

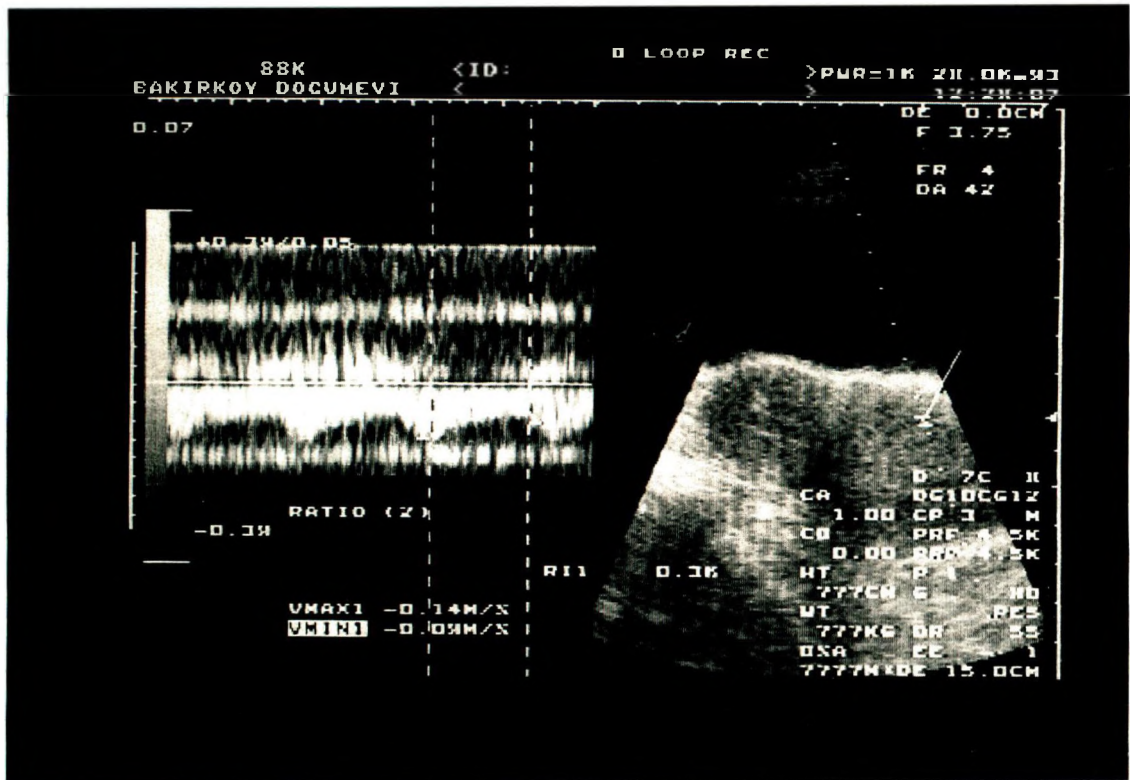


Fig 3. The RI of the vessels at the neovascularization area in the mass was measured as 0.38. The histopathological diagnosis was epidermoid carcinoma.

DISCUSSION

Studies have shown that tumor cells release angiogenic factors that stimulate new capillary growth (7-9). Tumor induced vessels are often dilated and saccular and may even contain tumor cells within the endothelial lining. Tumor microvasculature does not confirm the vasculature of normal tissues (artery to arteriole to capillary to postcapillary venule to venule to vein). Tumors may contain giant capillaries and arteriovenous shunts without intervening capillaries. Newly formed vessels contain no smooth muscles in their walls, but instead contain only a small amount of fibrous connective tissue (7,8).

Evaluation of several types of tumors by color Doppler has been reported (10-13). Although there are different opinions about cut-off values, in most of the studies a cut-off point of 0.40 for the resistance index as well as 1.00 for the pulsatility index were established and used as an indicator for malignancy (6,14,15). The values between 0.40 and 0.50 are accepted as borderline values.

Kurjak et al examined benign uterine masses by transvaginal color Doppler and found that the average resistance index (RI) of the vessels in the masses was 0.54 (16). The RI of the uterine artery was found as 0.74 and this was statistically different from the RI value of the uterine artery of the control group (0.89).

Hata et al studied ten women each with a normal uterus and 21 women with uterine myomas by measuring the resistance index in the arcuate artery (17). The mean RI was 0.76 in normal uteri and 0.67 in patients with uterine myomas.

In a recent study, 750 postmenopausal women were examined by transvaginal color Doppler before hysterectomy (18). 35 patients had endometrial carcinoma. There was an intratumoral neovascularization area in 91% of endometrial carcinoma cases. Visualization of abnormal blood flow within the endometrium was 100% in the diagnosed cases with resistance index near or less than 0.40, which constituted a statistically significant difference compared with that of endometrial hyperplasia.

Merce et al studied 45 patients with metrorrhagia and compared their findings with 19 normal women. They measured the RI values of both of the uterine arteries and the radial and arcuate arteries. A significant decrease in RI of the uterine and intramyometrial arteries was found in women with endometrial abnormalities. The authors concluded that RI of the intramyometrial (arcuate and radial) arteries was highly accurate in predicting positive findings when compared to the RI of uterine arteries (19).

In a study made by Kurjak et al, RI values measured from the vessels at the periphery of the endometrium in two endometrial carcinoma cases were 0.26 and

0.31 (6). In another study made by the same group, 291 benign and 17 malignant uterine masses were examined. Out of 291 benign uterine masses, 157 (54%) were vascularized, while 16 (94%) of the 17 malignant uterine tumors were vascularized. The average RI value in the benign cases was 0.58 and in the malignant cases 0.34 (20).

In our study average RI of the vessels in the neovascularization area of the benign masses was found as 0.66. This value is not different from the values in the literature (16,17). It was seen that both of the two cases with a RI value of 0.43 had a histopathologic diagnosis of degenerated myoma. It is known that during the secondary changes in the myomas the vessels in the myoma can lose some of its muscular elements in the wall and it is possible to find low RI values in the vessels at these degeneration areas (21).

It is known that the vascularization of the uterine masses differs according to the volume, position and the amount of secondary changes in the mass (21). The reason of the high vascularization in our benign masses may be that all of the cases were big masses hospitalized for laparotomy.

In our study there was a neovascularization area in all of the eight malignant masses. This percentage is between 94% and 100% in the literature (18,20).

Most of the studies that examine uterine pathologies by color Doppler sonography are performed as a screening test for postmenopausal women (6,18,20). In these studies the sensitivity, specificity, positive and negative predictive values of color Doppler sonography in evaluating uterine malignancy changed between 92% and 100%. Our study was not a screening test for postmenopausal women but all the cases in the study had a uterine mass and it was possible to see a neovascularization area in the mass in 90% of the benign and 100% of malignant masses. This may be the reason of our better results (100% in all parameters).

Our study suggests that color Doppler sonography is a useful clinical tool in the preoperative evaluation of uterine masses.

REFERENCES

1. Sample WF. Grey scale ultrasonography of normal female pelvis. In: Sanders RC, ed. *The principles and practice of ultrasonography in obstetrics and gynecology*. New York: Appleton Century-Crofts, 1980.
2. Platt JF, Bree RL, Davidson D. Ultrasound of the normal non-gravid uterus: correlation with gross and histopathology. *J Clin Ultrasound* 1990; 18:15-19.
3. Klug PW, Leitner G. Die gegenüberstellung vaginal-sonographischer und histologischer befunde am endometrium. *Geburtsh u Frauheilk* 1989;49:797-802.
4. Osmers R, Volksen M, Schauer A. Vaginosonography for early detection of endometrial carcinoma. *Lancet* 1990;1:1569-1571.

5. Bourne TH, Campbell S, Steer CV, Royston P, Whitehead MI, Collins WP. Detection of endometrial cancer by transvaginal ultrasonography with color flow imaging and blood flow analysis: a preliminary report. *Gynecol Oncol* 1991;40:253-259.
6. Kurjak A, Zalud I, Jurkovic D, Alfirovic Z, Miljan M. Transvaginal color flow Doppler for the assessment of pelvic circulation. *Acta Obstet Gynecol Scand* 1989;68:131-135.
7. Folkman J, Shing Y. Minireview. *J Biol Chem* 1992;267:10931-10934.
8. Folkman J, Melrel E, Abernethy C, Williams G. Isolation of a tumor factor responsible for angiogenesis. *J Exp Med* 1971;133:275-278.
9. Jain RK. Determinants of tumor blood flow. *Cancer Res* 1988;48:2641-2658.
10. Hata T, Hata K, Yamane Y, Kitao M. Real-time two dimensional and pulsed Doppler ultrasound detection of intrapelvic neoplastic tumor and abnormal pathogenic changes: preliminary report. *J Cardiovasc Ultrasonog* 1988;7:135.
11. Fleischer AC, Rogers WH, Rao BK, Kepple DM, Jones HW. Transvaginal color Doppler sonography of ovarian masses with pathological correlation. *Ultrasound Obstet Gynecol* 1991;1:275-278.
12. Bourne T, Campbell S, Steer C, Whitehead MI, Collins WP. Transvaginal color flow imaging: a possible new screening technique for ovarian cancer. *Br Med J* 1989;299:1367-1371.
13. Shimamoto K, Sakuma S, Ishigaki T, Makino N. Intratumoral blood flow: Evaluation with color Doppler echography. *Radiology* 1987;165:683-685.
14. Kurjak A. Screening for ovarian malignancy by transvaginal color flow imaging. *Ultrasound Obstet Gynecol* 1991;1 (suppl 1): 85.
15. Fleischer AC, Rodgers WH, Rao BK, Koppler DM, Worrel JA, Williams L. Assessment of ovarian tumor vascularity with transvaginal color Doppler sonography. *J Ultrasound Med* 1991;10:563-568.
16. Kurjak A, Kupesic-Urek S, Miric D. The assessment of benign uterine tumor vascularization by transvaginal color Doppler. *Ultrasound Med Biol* 1992;18:645-649.
17. Hata K, Makihara K, Hata T, Aoki S, Kitao M. Transvaginal color Doppler imaging for hemodynamic assessment of reproductive tract tumors. *Jpn Int J Obstet Gynecol* 1991;36:301-308.
18. Kurjak A, Shalan H, Sosic A, Benic S, Zudenigo D, Kupesic S, Predanic M. Endometrial carcinoma in postmenopausal women: Evaluation by transvaginal color Doppler ultrasonography. *Am J Obstet Gynecol* 1993;169 (6):1597-1603.
19. Merce LT, Garica L, Dela Fuente F. Doppler ultrasound assessment of endometrial pathology. *Acta Obstet Gynecol Scand* 1991;70:525-530.
20. Kurjak A, Zalud I. The characterization of uterine tumors by transvaginal color Doppler. *Ultrasound Obstet Gynecol* 1991;1:50-52.
21. Kurjak A, Shalan H, Kupesic S, Predanic M, Zalud I. Transvaginal color Doppler sonography in the assessment of pelvic tumor vascularity. *Ultrasound Obstet Gynecol* 1993;3:137-154.