

USE OF A TOE-PULP GRAFT COMBINED WITH V-Y ADVANCEMENT FLAP IN CORRECTION OF HOOK NAIL DEFORMITY

(Received 5 May, 1994)

N. Durak, M.D. / F. Yüksel, M.D.*** / E. Kışlaoğlu, M.D.***

* Professor, Department of Plastic and Reconstructive Surgery, Gülhane Military Medical Academy, Haydarpaşa Training Hospital, Istanbul, Turkey.

** Associate Professor, Department of Plastic and Reconstructive Surgery, Gülhane Military Medical Academy, Haydarpaşa Training Hospital, Istanbul, Turkey.

*** Resident, Department of Plastic and Reconstructive Surgery, Gülhane Military Medical Academy, Haydarpaşa Training Hospital, Istanbul, Turkey.

SUMMARY

The Hook-Nail deformity can accompany the flexion deformity of the DIP joint of the finger. In these cases, it is very hard to correct them using only one technique. Therefore, we think that it is better to use the combined technique of composite toe graft and V-Y advancement.

This combined technique has been performed in four patients. All the grafts and flaps were viable and all the fingers were more functional and better. No donor-site morbidity has been seen in the follow-up period.

Key Words : Hook Nail, Composite graft.

INTRODUCTION

Fingertip amputations are common accidents which happen during work and other daily activities. They are treated by various techniques including grafting, crossfinger flap, Kuttler and Atasoy's (1-3). Generally in every technique there occurs a deformity well known as "Hook Nail" following the healing process (4-6). It may also occur due to flexion contracture of finger, especially following burns. In these cases, it will certainly be harder to correct both the "Hook-Nail" and the flexion deformities of the finger because of the stiffness of tissues. If there is a loss of support of the distal nailbed over distal phalanx, the nailbed may curve volarly (2,5,7). The nail will continue to curve even if it passes the bed. It covers the tip of it and there becomes a painful and awful looking finger (7).

To correct the deformity, the distal nailbed must be released completely and returned to its normal position. There must be tissue to provide enough support to maintain it. Several techniques, including, full-thickness skin grafts, bone grafts, cross-finger flaps with or without Kirschner wire support, and toe-pulp grafts, have been described (8,9). We have applied toe-pulp grafts alone in several cases and ensured acceptable results. Grafts had surely given good support when placed beneath the released nailbed but fullness of the pulp was still inadequate to

correct the deformity completely. Besides, if there was a contracture over the DIP joint, there became a gap too wide to be corrected by a composite graft alone when the nailbed was incised. So, we intended to use the composite toe-pulp graft combined with a V-Y advancement flap to correct the defect manifested when the contracture line was released.

PATIENTS AND METHODS

Four patients have been treated using composite grafts combined with V-Y advancement flaps. They were all males, 20,21,24 and 36 years old respectively, and had follow-up of 1 month to 1 year. They all had suffered hand-burn injuries during their teenages. They had flexion deformity of DIP joints ranging from 30 to 90 degrees. DIP joints of the three patients were supple enough, but one had both active and passive motion restriction. All the patients had digital block anesthesia and were treated on an outpatient basis. The antibiotics were given peri and post-operatively.

Under digital tourniquet control, a fishmouth incision was made in the hyponichium, 3 mm. beneath the nailbed. The incision was carried proximally until the displaced nailbed was completely unstrained. Then, an elliptical transverse wedge of skin and pulp harvested from second toe, sutured into the recipient defect. The donor site was closed primarily. After that, an advancement flap planned on the contracture line of flexion deformity, was incised and sutured in a V-Y fashion. An external cast, or if necessary, internal fixation with K- wire was applied. The finger was splinted for three weeks (Figs. 1,2,3).

RESULTS

No significant problems with either grafts or flaps appeared following operation. Marginal epidermal necrosis on the flaps manifested in two cases, healed by periodic dressings. In two cases, the flexion deformity could be corrected as much as 45 degrees because of extremely contracted tissue on contracture lines. However, all the patients were satisfied at least for their "Hook Nail" deformities.

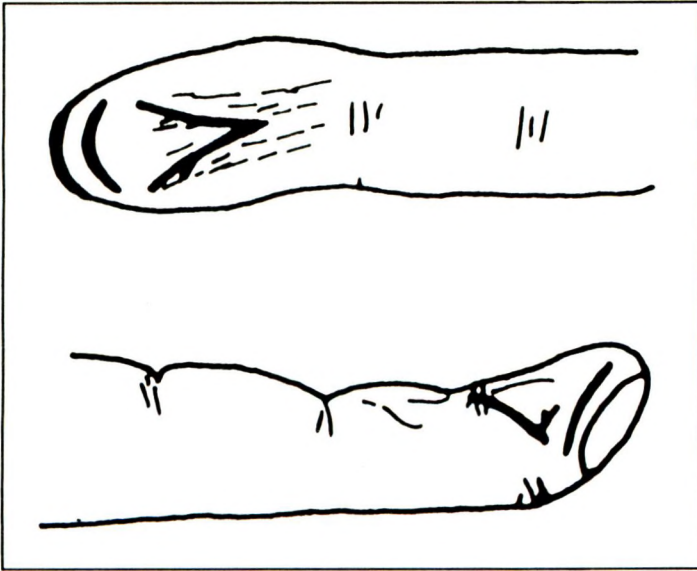


Fig 1. Proposed design of incision preoperatively

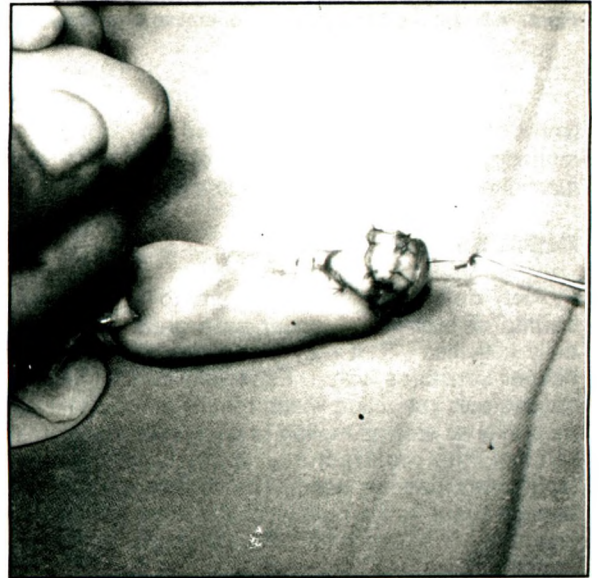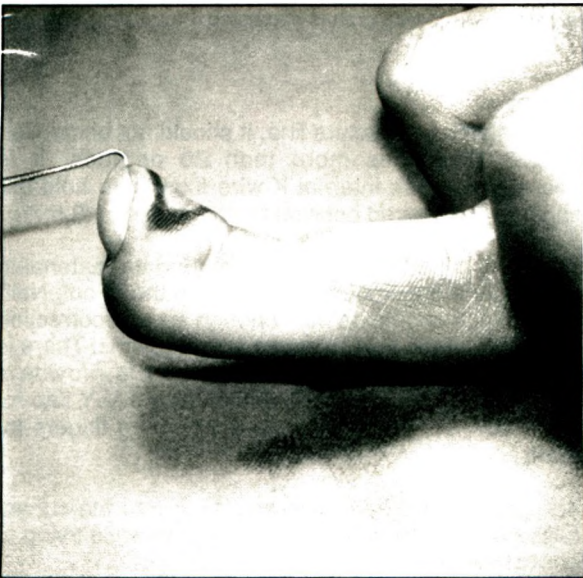


Fig 2. a,b - View of the "Hook - nail" deformity just (a) before and (b) after operation.

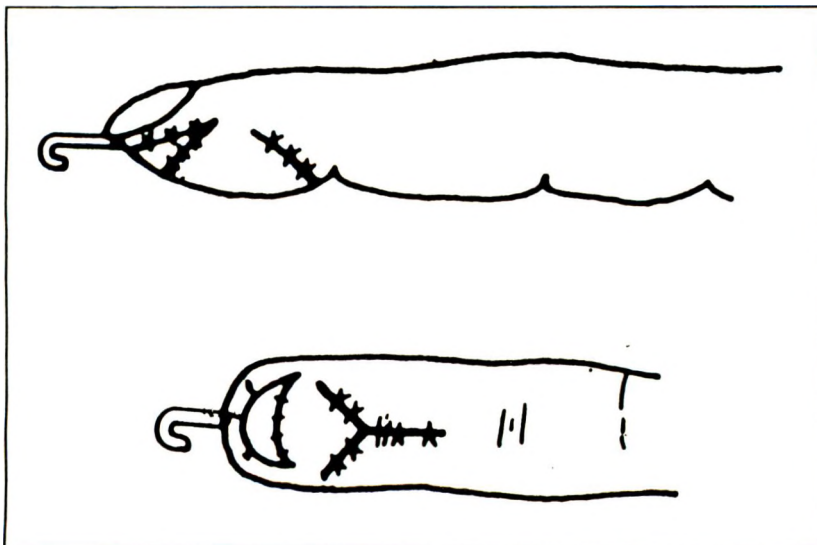


Fig 3. Proposed design of toe graft and V - Y flap postoperatively

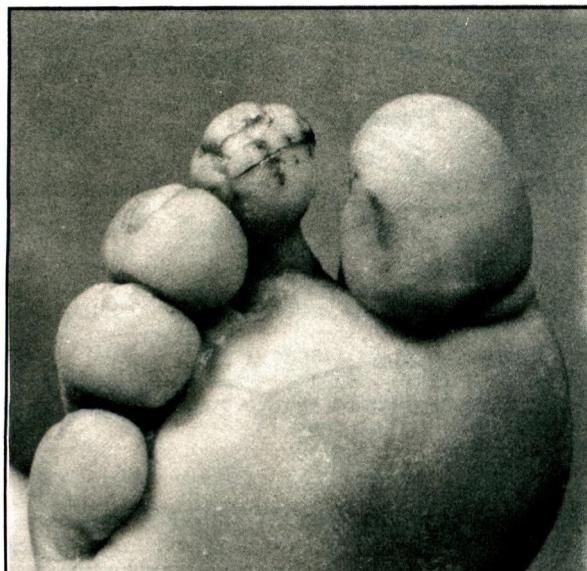
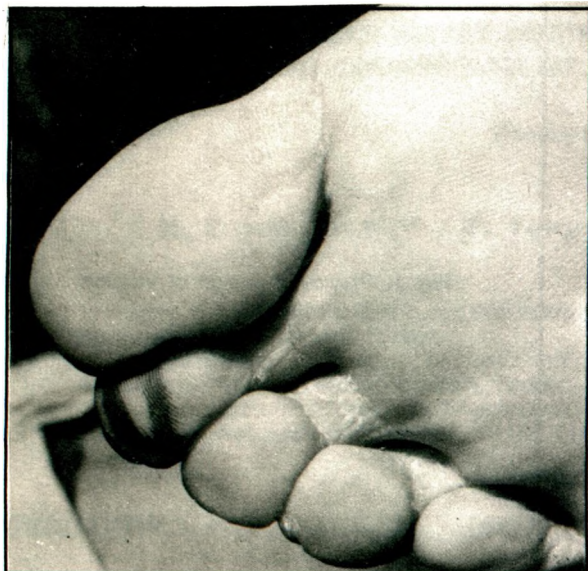


Fig 4. a,b - (a) pre - and (b) post - operative view of second toe from which a composite graft is harvested.

None of the patients experienced any donor-site morbidity (Fig 4). As a result, all of them have more functional and better looking fingers (Fig. 5).

DISCUSSION

Flexion deformity of the fingers following major trauma or burn may appear as a great problem in daily activities (2). It may just comprise the skin or deeper structures with it. Especially on DIP joints, it causes pulp retraction which results in "Hook - Nail" deformity as well as motion restriction of the joint. To release the contracture, Z-plasty or grafting techniques can be used. The former cannot take enough tissue to the pulp while the latter will contract again. A V-Y advancement flap can serve better than the other flaps and take more tissue to the pulp while

releasing the contracture line. It should not be applied to the deformities more than 90 degrees. It is necessary to use internal K-wire fixation to hold the finger in the desired position for three weeks (3,5,7).

The composite toe graft is an appropriate material in padding the fingertip, thus correcting the "Hook-Nail" deformity. It should be bulk enough for overcorrection and contract too little to cause any problems. There is usually enough tissue in one toe pad to provide a substantial graft, especially while using a V-Y flap for correction; so, we did not need any more fingers for grafts.

The goals of the operation are (1) to free the curved nailbed, (2) to restore sufficient tip pulp while trying to correct the flexion deformity.

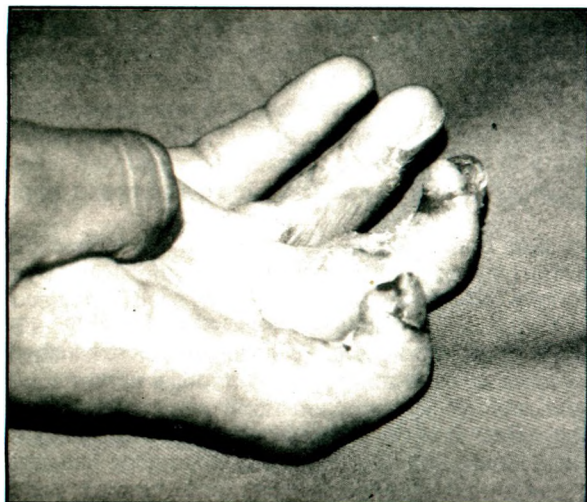

Fig 5. Appearance of corrected "Hook Nail" deformity 3 months after surgery

The procedure does not have significant donor-site morbidity and early mobilization is possible.

In this study, you can see that such a deformity, looking simple but causing great disability, can be corrected by using combined common techniques well known in plastic and reconstructive surgery.

REFERENCES

1. Zook EG. *The perionychium: Anatomy, physiology, and care of injuries*. *Clin Plast Surg* 1981;8:21-24.
2. Zook EG. *Complications of the perionychium*. *Hand Clin* 1986;2:407-410.
3. Atasoy E, Godfrey A, Kalisman M. *The 'antenna' procedure for the 'hook-nail' deformity*. *J Hand Surg* 1983;8A:55-58.
4. Zook EG, Russell RC. *Reconstitution of a functional and esthetic nail*. *Hand Clin* 1990;6:59-61.
5. Shepard GH. *Nail grafts for reconstruction*. *Hand Clin* 1990;6 (1):79-102.
6. Guy RJ. *The etiologies and mechanisms of nail bed injuries*. *Hand Clin* 1990;6:9-12.
7. Bubak PJ, Richey MD, Engrav LH. *Hook-nail deformity repaired using a composite toe graft*. *Plast Reconstr Surg* 1992;90:1078-1080.
8. Mc Cash CR. *Toe pulp free grafts in fingertip repair*. *Br J Plast Surg* 1958;8:19-23.
9. Sturman MJ, Duran RJ. *Late results of fingertip injuries*. *J Bone Joint Surg* 1963; 45:289-292.