A CASE OF VENTRICULAR FLUTTER AND FIBRILLATION IN A CALF SUFFERING FROM DIARRHEA

İshalli bir buzağıda ventriküler flatter ve fibrilasyon olgusu

Abdullah BAŞOĞLU[1]
Kürşat TURGUT[2]

Özet : Üç gündür ishal şikayeti olan bir buzağının çekilen elektrokardiyografisinde ventriküler flatter ve fibrilasyon teşhis edildi. Buzağıda dehidrasyonla birlikte aşırı zayıflama vardı ve klinik tablo çok ağırdı. Hematolojik muayenede; hiperkalemi (12.5 mEq/L) ve hiperkloremi (159 mEq/L) tesbit edildi. Serum Na^+ (156 mEq/L) ve Ca^{++} (10.43 mg/dl) konsantrasyonları normal sınırlar içindeydi. Buzağı kliniğe getirildikten otuz dakika sonra öldü. Otopside, kalpte herhangi bir organik bozukluğa rastlanmadı.

Summary : Ventricular flutter and fibrilation was diagnosed by means of ECG in a calf suffering from diarrhea for three days. The calf was dehydrated, emaciated and in moribund status. Evaluation of blood sample revealed hyperkalemia (12.5 mEq/L) and hyperchloremia (159 mEq/L). Serum Na^+ (156 mEq/L) and Ca^{++} (10.34 mg/dl) levels were within normal range. She died at thirty minutes after arrival. At necropsy, there was no any organic disorder in the heart.

Introduction

Ventricular flutter and fibrillation are rapid, irregular cardiac rhythm. The diagnosis must be made electrocardiographically since the peripheral pulses are not palpable and heart beat is inaudible (7).

It has been reported that ventricular flutter is a progressive stuation. In most cases, it is followed by ventricular fibrillation (1, 9). Both ventricular flutter and fibrillation occur in the therminal stages of most suddenly fatal disease including lightning stroke, plant poisonings such as

(1) Öğr. Gör. Dr., S. Ü. Veteriner Fakültesi, İç Hast. Bilim Dalı, Konya.
(2) Yrd. Doç. Dr., S. Ü. Veteriner Fakültesi, İç Hast. Bilim Dalı, Konya.

acute phalaris toxicity, overdose with anesthetics, severe toxemia and in the therminal phases of most acquired cardiac disease (2).

Diarrhea in newborn calves under 10 days of age is one of the most common diseases. It is characterised clinically by acute profuse watery diarrhea, progressive dehydration and acidosis and death in a few days or earlier (2). It causes severe acid-base and electrolyte disturbance. Hyperkalemic, hyperchloremic, normal anion gap, metabolic acidosis develop with the severity of the disease (4).

Reports of electrocardiographic diagnosis of arrhythmias in cattle are few. Cases of atrial fibrillation in cattle have been reported most commonly (3, 8). However, we could not find a report deal with ventricular flutter and fibrillation in calves. That's why, we wanted to represent this case detected for the first time in our clinics.

Case

A one week old cross breed Holstein Fresian calf was admitted with a history of diarrhea for three days to the clinics of Internal Medinicine, Faculty of Veterinary Medinicine, Konya.

The calf was dehydrated, emaciated and in moribund status. Rectal temperature and respiration rate 40 °C and 60/min respectively. Peripheral pulse could not be palpeted and heart sounds could not be auscultated clearly. Electrocardiogram was recorded on a 3 - channal portable electrocardiograph (*). Recordings were made with calf in right lateral recumbency. Electrodes were placed according to the technique described by Deroth (5). Recordings were made at a paper speed of 25 mm/sec and sensitivty of 1 (1 cm, 1mV). Ventricular flutter and fibrilation were evident on the ECG (Fig. 1).

Evaluation of blood sample obteined from the calf revealed hyperkalemia (12.5 mEq/L) and hyperchloremia (159 mEq/L). Serum Na^+ (156 mEq/L) and Ca^{++} (10.34 mg/dl) levels were within normal range.

Immediately, Adrenaline was injected intravenously. But, the calf condition deteriorated rapidly and she died at thirty minutes after arrival. At necropsy, there was subserous and submucosal petechial hemorrhages. There was no any organic disorder in the hearth. At the bacteriological examination, Escherichia coli enteritis was diagnosed.

(*) Petaş Cardiopet 110.

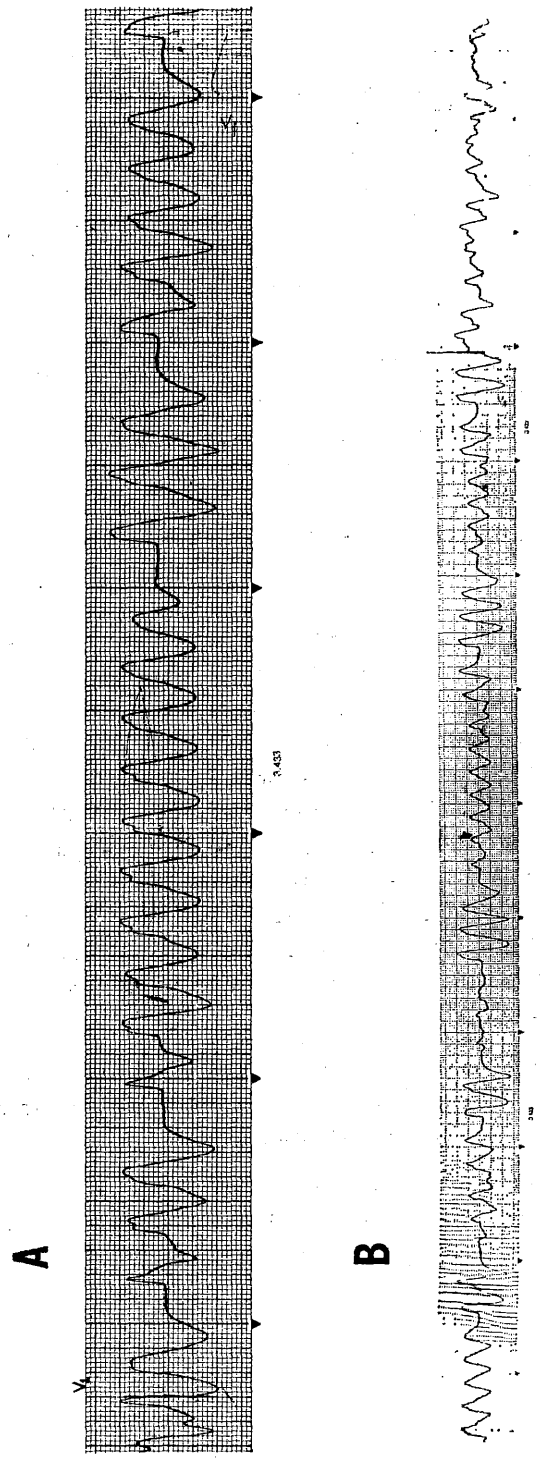

Figure 1. Electrocardiograms recorded from the calf. A: Ventricular flutter. B: Ventricular fibrilation. Paper speed 25 mm/sec.

Discussion

It has been reported that ventricular flutter is a very rare condition. It is a progressive stuation and take a sudden turn to ventricular fibrilation (1, 9, 13). QRS complexs and T waves are too large and in abnormal structure in the ventricular flutter. But, they are in the same shape. When one of the cardiac cyclus finish, the following cyclus start, so complexes are fallow to each other continuously That's why, QRS complex, ST segment and T wave can not be confirmed separetly (1, 13). In the ventricular fibrillation, since the ventricular contractions are erratic, the ECG shows bizarre ventricular pattern of varying size and configuration (7). Electrocardiographic properties of both ventricular flutter and fibrillation were evident on the ECG record of the calf (Fig. 1). Most experimental evidence suggests that cardiac arrhythmias are due to abnormalities in cellular conduction or automaticity. Cardiac conduction can be altered by electrolyte, acid-base disturbances and organic cardiac diseases (10).

Potassium (K^+), calcium (Ca^{++}), sodium (Na^+) and magnesium (Mg^{++}) play a role in the genesis of experimental arrhythmias. In the clinical setting, however, altered K^+ concentration is responsible for the wast majority of such arrhythmias (6). In an experimental study (11), it was found that there was a transient phase of acceleration of intraventricular conduction as K^+ is elevated moderalety but, further rise of K^+ intraventricular conduction was depressed. In an another study (12), it has been pointed out that in the face of slowly rising plasma K^+, the mechanism of death was cardiac standstill due to diffuse depression of intraventricular conduction and only occasionally due to ventricular fibrillation. So, detected high serum K^+ concentration in this case may be responsible for atrial flatter and fibrillation.

It has been reported that the most common cause of atrial fibrillation is acute myocardial infarction (7). However, there was no any organic disorder in the hearth at necropsy in this case.

In conclusion, we found that ECG was an essantial procedure to determine the cardiac arrhythmias in calves. High serum K^+ concentration might play a role in the development of ventricular flutter and fibrillation.

References

1 — Birand, A. (1978). Elektrokardiyografi. Beta Yayınevi, 8dana.

2 — Blood, D. C., Radostits, O. M. and Henderson, J. A. (1983). Veterinary Medicine, Sixth Edition. Bailliere Tindall, London.

3 — Brightling, P. and Townsend, H. G. G. (1983). Atrial fibrillation in ten cows. Can. Vet. J., 24, 331-334.

4 — Brobst, D. (1983). Pathophysiological and adaptive changes in acidbase disorders. J. A. V. M. A. 183, 7, 773-780.

5 — Deroth, L. (1980). Electrocardiographic parameters in the normal lactating Holstein cows. Can. Vet. J., 21, 271-277.

6 — Fisch, C. (1973). Relation of electrolyte disturbances to cardiac arrhythmias. Circulation, 157, 308-419.

7 — Goldman, M. J. (1976). Principles of clinical electrocardiography. 10 th. Edition. Lange Medical Publications. Los Altos, California.

8 — Guirk, S. M., Muir, W. W., Sams, R. A. and Rings, D. M. (1983). Atrial fibrillation in cows : clinical findings and therapeutic considerations. J.A.V.M.A. 182, 12, 1380-1386.

9 — Herve, D. (1987). Insuffisance circulatoire aigue. Pratique Medicale at Chirurgicale de I'Animal de Compagnie, 5, 333-345.

10 — Hoffman, B. E. and Fosen, M. R. (1981). Cellular mechanisms for cardiac arrhythmias. Circs. Res., 49, 1-15.

11 — Mendez, C., Erlij, K. and Moe, G. K. (1964). Indirect action of epinephrine on intraventricular conduction time. Circ. Res., 14, 318-321.

12 — Nahum, L. H. and Hoff, H. E. (1969). Observations on potassium fibrillation. J. Pharmacol., Exp. Ther., 65, 325-329.

13 — Oktay, S. Süleymanlar, G. (1984). Pratik elektrokardiyografi. Hacettepe Taş Kitapcılık Ltd. Şti., Ankara.