



Radiographic, Ultrasonographic and Thermographic Findings in Neonatal Calves with Septic Arthritis: 82 cases (2006-2013)

Elif DOĞAN¹, Latif Emrah YANMAZ¹✉, Zafer OKUMUŞ¹, Mahir KAYA¹, Mümin Gökhan ŞENOCAK¹, Seyda CENGİZ²

1. Ataturk University, Faculty of Veterinary Medicine, Department of Surgery, Erzurum, TURKEY.
2. Ataturk University, Faculty of Veterinary Medicine, Department of Microbiology, Erzurum, TURKEY.

Geliş Tarihi/Received
10.06.2015

Kabul Tarihi/Accepted
06.10.2015

Yayın Tarihi/Published
24.04.2016

Abstract: Septic arthritis is defined as inflammation of a joint caused by various microorganisms. The aim of this study was to evaluate the diagnosis and treatment characteristics of septic arthritis encountered in 82 calves. Fifty-eight cases were monoarthritis, and 24 cases were polyarthritis. Omphalitis was detected in 17 calves. Dorsal, medial and lateral thermograms of joints revealed hot points (n=82). In ultrasonographic examination, inflammatory effusions with different echogenicity were seen. Widening of joint space (n=35) and new bone formation (n=42) were detected by radiography. *Arcanobacterium pyogenes* and *Escherichia coli* (83%) were commonly founded microorganisms. Medical treatment was successful in total of 59 calves (71.9%), 1 calf with polyarthritis and 58 calves with monoarthritis. Twenty-three calves were slaughtered because no clinical improvement was observed till the 14 day of treatment.

Keywords: Calves, Septic arthritis, Thermography, Treatment.

Septik Artritisi Yeni Doğan Buzağılarda Radyografik, Ultrasonografik ve Termografik Bulgular: 82 olgu (2006-2013)

Öz: Septik artritisi birçok mikroorganizmanın neden olduğu bir eklem yangısıdır. Bu çalışmanın amacı 82 buzağıda karşılaşılan septik artritisi tanı ve sağaltımını değerlendirmektir. Elli-sekiz olguda monoartritisi, 24 olguda ise poliartritisi görüldü. Omfalitisi 17 buzağıda belirlendi. Alınan termogramlar ile eklemlerin dorsal, medial ve lateral yüzlerindeki sıcak noktalar (n=82) belirlendi. Ultrasonografik muayenede farklı ekojenitede yangısel effüzyonlar görüldü. Radyografide, eklem aralığının genişlemesi (n=35) ve yeni kemik formasyonları (n=42) belirlendi. Değerlendirilen eklemlerden en sık *Arcanobacterium pyogenes* ve *Escherichia coli* (83%) izole edildi. Medikal sağaltım, monoartritisi 58 buzağı ve poliartritisi 1 buzağı olmak üzere toplan 59 buzağıda (71.9%) başarılı oldu. Yirmi-üç buzağıda, sağaltımın 14. güne kadar klinik bir ilerleme olmadığından, bu olgular kesime sevk edildi.

Anahtar Kelimeler: Buzağı, Sağaltım, Septik artritisi, Termografi.

✉ Latif Emrah YANMAZ

Ataturk University, Faculty of Veterinary Medicine, Department of Surgery, Erzurum, TURKEY.
e-mail: latifemrahyanmaz@gmail.com

INTRODUCTION

S eptic arthritis is very common disease that frequently affects newborn calves. Due to the long treatment period and expensive costs, a considerable number of animals are slaughtered every year (1,2). Septic arthritis commonly occurs due to direct trauma or systemic infections such as umbilical diseases (3,4). Diagnosis is based on clinical symptoms, radiography, ultrasound and bacterial cultures (5-7). Clinical findings include swollen and painful joints, lameness, fever and anorexia (8). The earliest radiographic finding of the arthritis is joint enlargement, which can be seen in 5-10 days. The later radiographic findings include lytic changes in the subchondral bone, capsule thickening and increasing opacity, which can be seen after 4-5 weeks (9).

Ultrasonography is useful to evaluate joint problems and it provides information about the location, size and the nature of the content. In healthy joints, normal synovial content may not be imaged by ultrasound, presence of effusion and distension of the synovial pouch are usually indicates joint inflammation (10). Thermography is the non-invasive technique that shows inflammation in a region (11). If there is an inflammation associated with a joint, it can be easily detected by using thermal camera (12).

Treatment of septic arthritis includes antibiotics, joint irrigation and non-inflammatory drugs (13). Otherwise, the health conditions of calves become worst and they will die in 2-14 days (14). The aim of this study was to evaluate the diagnosis and treatment characteristics of septic arthritis in neonatal calves, which referred to the Veterinary Clinic at the Atatürk University.

MATERIALS and METHODS

Animals

Eighty-two calves with different age, breed, sex and history of lameness and joint swelling, were enrolled in a retrospective study. The calves were

referred to the Veterinary Clinic at the Atatürk University to be evaluated for septic arthritis from January 2006 till November 2013. After a full history was recorded for each calf, clinical examination and diagnostic procedures were performed.

Imaging Techniques

Thermographic examination was carried on the dorsal, medial and lateral aspects of the joints. To minimize air flow and sunlight calves were kept in a room for 15-20 min for adaptation.

Radiographic examination of the joints included the Cranio-caudal (Cr/Ca) and medio-lateral (M/L) projections.

For ultrasonographic examination, involved joints were clipped; cleansed and contact gel was applied. Joints were scanned by using 5 MHz sector and 7.5 MHz linear transducers.

Microbiological Analysis

For microbiological analysis of the affected joint prior to the joint lavage, calves were sedated with 0.05mg/kg i.v. xylazine and placed in the left or right lateral recumbence according to involved limb placed in upper position. The involved joint was prepared for aseptic surgery by using standard procedure. Following asepsis, a 16- gauge needle was placed into the dorsomedial pouch of the associated joint and 2 mL of synovial fluid was obtained with a 2.5-mL syringe. Two mL synovial fluid was inoculated onto Columbia agar with 7% defibrinated sheep blood and MacConkey agar for routine diagnosis. The plates were incubated for 24 hours at 37 °C. Identification of any growth on agars was based on the morphological and haemolytic characteristic of the colonies, catalase, coagulase and oxidase tests, the gram staining and specific biochemical test based on earlier report (15). Antibiotic susceptibility tests were performed by the Agar Disc Diffusion method, according to the Clinical Laboratory Standards Guide. The colonies were suspended in saline solution of NaCl 0.9%. Turbidity

was adjusted to 0.5 McFarland standard (about 10^8 CFU/mL), and used as the inoculums for the antibiotic tests. Afterwards, 0.1 mL bacterial suspension was spread on Muller Hinton agar and antibiotic disks were placed on the agar. Disks containing Amoxicillin-clavulanic acid (20/10 µg), ampicillin-sulbactam (10/10 µg), streptomycin (10 µg), tetracycline (30 µg), trimethoprim (5 µg) were obtained from Oxoid® (Hampshire, England). The plates were incubated at 37 °C for 24 h. Inhibition zones were measured and classified according to Clinical Laboratory Standards Guide as susceptible, moderate resistant or resistant (16).

Treatment

Joint lavage was performed by a through-and-through technique. When the technique was unsuccessful due to cheesy pus, two incisions were made to the anterior and posterior parts of the joint for irrigation. Systemic antibiotic was used until culture results taken place; preferred antibiotic was Amoxicillin-clavulanic acid (8.75 mg/kg, IV, bid). Ketoprofen (3mg/kg, IM, sid, for 5 days) was the anti-inflammatory drug choice. In addition to Amoxicillin-clavulanic acid, Tulathromycin (2.5 mg/kg, SC) was also used in pneumonic cases.

RESULTS

Fifty-eight cases had monoarthritis, while 24 cases suffered from polyarthritis. Calves were 5 days to 3 months of age (median 15 days-old) and included 50 males and 32 females. Table 1 presents the collected data related to 82 calves with septic arthritis. Omphalitis was detected in 17 calves (11 polyarthritis, 6 monoarthritis), and 3 polyarthritis cases had omphalitis and pneumonia.

The history of all cases included the presence of anorexia, lameness, fatigue, and local swelling at the involved joint. All the cases had fever (range 39.7°C to 40.6°C), and pain in passive motion of the joint. Coughing was noticed in 3 cases. All the cases showed fibrin clots, cloudy and dark colour

appearance in synovial fluid analysis. Foul smell was detected in fistulised joints (n=29).

Table 1. Summary data for 82 calves with septic arthritis.

Tablo 1. Septik artritisi 82 buzağının özet bilgileri.

Variable	Number of cases	%
Sex		
Male	50	61.0
Female	32	39.0
Age		
<1 week	42	51.2
1-4 week	28	34.1
4-12 week	12	14.6
Breed distribution		
Crossbreed	45	54.9
Brown Swiss	22	26.8
East Anatolian Red	8	9.8
Simmental	5	6.1
Holstein Friesians	2	2.4
Number of involved joints		
Monoarthritis	58	70.7
Polyarthritis	24	29.3
Localization of joints (totally 118)		
Carpus	77	65.3
Tarsus	25	21.2
Knee	8	6.8
Elbow	3	2.5
Metacarpophalangeal	3	2.5
Metatarsophalangeal	2	1.7

The dorsal, medial and lateral thermograms of joints revealed hot points (n=82). These hot points were warmer than surrounding area (Fig 1, 2 and 3). Ultrasonographic examination was achieved in 67 cases and inflammatory effusions with different echogenity were seen in all cases (Fig 4). Widening of the joint space (n=35), new bone formation and bone osteolysis (n=42) were detected by radiography (Fig 5). Radiographic examination was not performed in 5 cases.

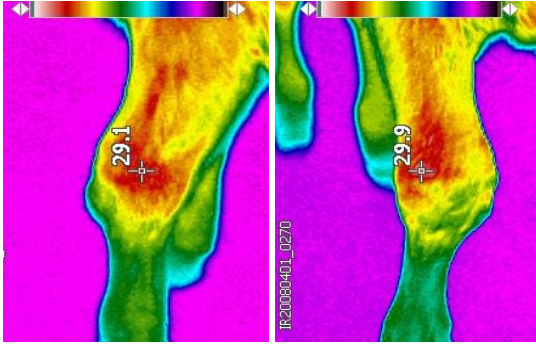


Fig 1. Lateral carpal thermograms of male, 1 week old, crossbreed calf with polyarthritis. Hot spots were seen as a red colour.

Şekil 1. Poliartritisi 1 haftalık erkek melez buzağının lateral karpal termogramları. Sıcak noktalar kırmızı renkte görülmektedir.

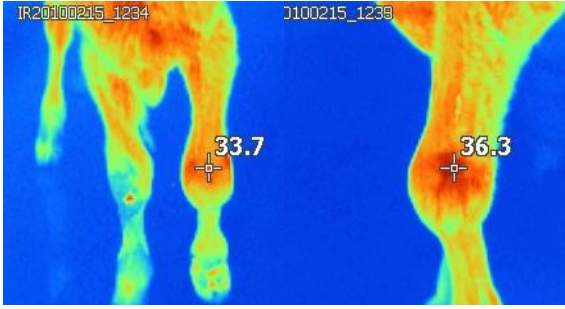


Fig 2. Male, 1 month old, Brown Swiss calf with left septic carpalitis. Dorsal and lateral thermograms of left carpus showed hot spots.

Şekil 2. Erkek, 1 aylık, sol septik karpitisli İsviçre Esmeri buzağı. Sol karpusun dorsal ve lateral termogramları sıcak noktaları göstermekte.

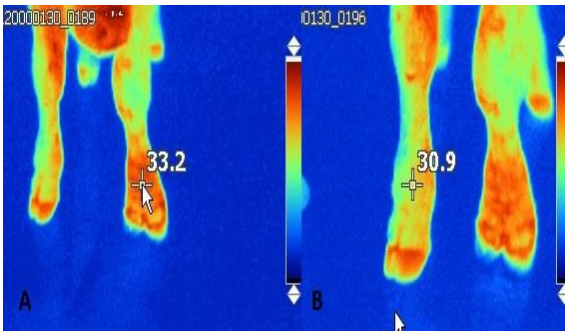


Fig 3. Male, 1 week old, Brown Swiss calf. Dorsal thermograms revealed 2-3°C differences between healthy (B) and septic metacarpophalangeal (A) joint.

Şekil 3. İsviçre Esmeri, 1 haftalık erkek buzağı. Dorsal termogramlar, septik (A) ve sağlıklı (B) metakarpofalangeal eklemler arasında 2-3 °C'lik sıcaklık farkını ortaya çıkardı.

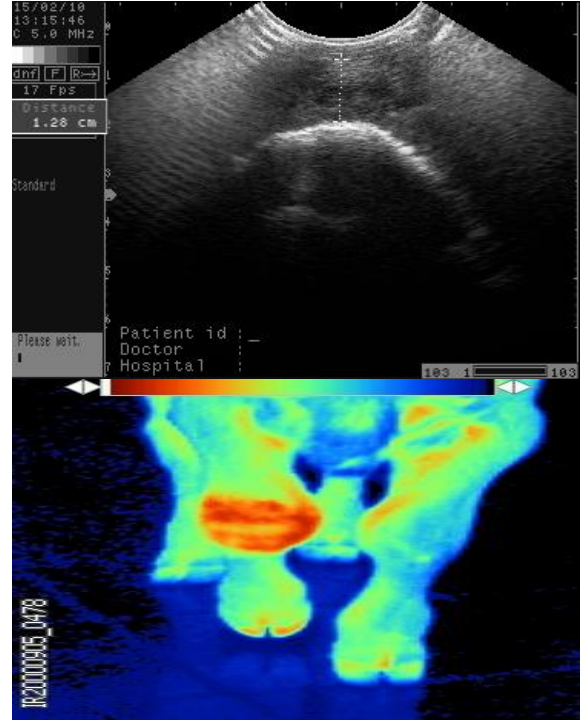


Fig 4. Male, 1 month old, Brown Swiss calf with right septic carpalitis. Ultrasonography of right carpus showed inflammatory effusion in the joint. Thermogram of the same case, note hot spots at the dorsal view of the joint.

Şekil 4. Erkek, 1 aylık, Sağ septik karpitisli İsviçre Esmeri buzağı. Sağ karpusun ultrasonografisi eklemden yangısel effüzyonu gösterdi. Aynı olgunun termogramı, eklem dorsal yüzünde sıcak noktalar fark ediliyor.

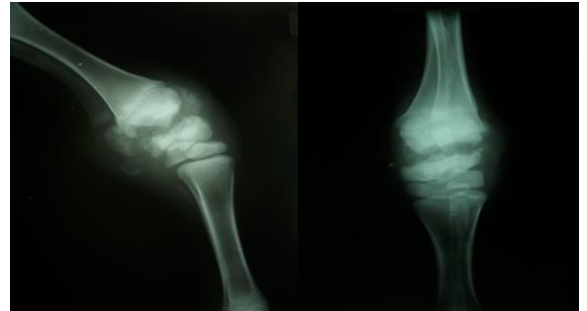


Fig 5. Female, 2 month old, Simmental calf with left septic carpalitis. Medio-lateral (M/L) and Cranio-caudal (Cr/Ca) radiographs of left carpus revealed osteolysis at the distal radial condylus and proximal carpal bones.

Şekil 5. Dişi, 2 aylık, sol septik karpitisli Simental buzağı. Sol karpusun Medio-lateral (M/L) ve Cranio-caudal (Cr/Ca) radyografileri proksimal karpal kemiklerde ve distal radius kondilusunda osteolizleri göstermektedir.

According to microbiological analysis; *Arcanobacterium pyogenes* and *Escherichia coli* (83%) were commonly found. Other detected microorganisms were *Staphylococcus aureus*, *Actinomyces spp.* and *Actinobacillus spp.* (17%). Amoxicillin-Clavulanic acid combination showed a high efficacy, so the combination had been chosen as the first antibiotic option.

Medical treatment continued until swelling resolves and disappearance of lameness. In 59 calves, following medical treatment, rectal temperature was decreased on the 4th day of treatment at average normal levels (38.5 °C-39.1 °C), and joint swelling gradually decreased. There was no clinical improvement in 23 calves till 14th day of treatment. Twenty-three calves with polyarthritis (3 of them had pneumonia and omphalitis) were slaughtered as a consequence of unresponsiveness to medical treatment. The treated 59 calves (71.9%), one with polyarthritis and 58 with monoarthritis had good outcomes. Table 2 presents outcome of the 82 calves with septic arthritis.

Table 2. Outcome of treatments in 82 calves with septic arthritis.

Tablo 2. 82 buzağıda septik artritlerin sağaltım sonuçları.

Outcome	Involved Joints	
	Monoarthritis	Polyarthritis
Treatment	58	24
Recovered	58	1
Slaughtered	-	23

DISCUSSION and CONCLUSION

The early postnatal period is one of the most challenging factors in calf health (3). Septic arthritis is one of the major problems that affect calf health and can arise from haematogenous spread such as umbilical cord diseases or percutaneous infection such as trauma or invasion from adjacent tissue (8). In the present study, umbilical diseases were also encountered in 20 calves with septic arthritis. Polyarthritis is the frustrating complication of umbilical diseases, and it can also result from

gastrointestinal or respiratory diseases via haematogenous spread (14). In this study, 24 calves had problems more than one joint, and omphalitis was the reason of polyarthritis in 14 calves. Lameness, swollen and painful joints, fever and inappetence are common clinical findings of septic arthritis (2,9). In this study, these clinical findings were present in all the calves. Increased turbidity, decreased viscosity and existence of fibrin are the macroscopic findings of synovial fluid in septic arthritis. When the macroscopic changes are subtle, sample should be analysed for cellular count (7,9,17). In the current study, fibrin clots, cloudy and dark colour appearances in synovial fluid were obvious, thereby sample did not submit for cell count. Microbiological culture is essential for the diagnosis of bacterial infections and culture results play an important role to detect susceptible antibiotics (17). *Arcanobacterium pyogenes* and *Escherichia coli* are the most common microorganisms isolated in septic arthritis cases (14). Similar to this report (14), the same microorganisms (83%) were also commonly found in this study.

Usefulness of thermography in joint problems of horses has been pointed by previous reports (18,19). If there is a joint problem, increased temperature can be easily seen in the dorsal view of the related joint (11). In this study, dorsal thermograms of joints revealed similar results.

The ultrasonography of the joint is one of the basic initial imaging modality with very good sensitivity to diagnose joint effusion in septic arthritis (20). In acute stage of the septic arthritis, increased synovial fluid volume and echogenic material which floats in the joint can be seen (9). Similar to the previous report, inflammatory effusions with different echogenicity was detected in the present study.

It has been proven that radiography is the main imaging technique to give information about the stage and prognosis of the joint problems. Early radiographic finding is joint distension, and when

the problem becomes chronic, new bone formation can be visible (4,10). In this study, widening of joint space and periosteal new bone formation were detected by radiography.

Treatment of septic arthritis is maintained by lavage of the whole joint, systemic antibiotics and anti-inflammatory drugs. Broad-spectrum antibiotics should be chosen initially and the choice of antibiotics may be modified after the results of sensitivity testing (21,22). Prognosis and outcome of the septic arthritis is depending on the number of affected joints (5,23). Prognosis is better when one joint is involved only (14). Despite intensive treatment, the prognosis is guarded for septic arthritis and return to full activity range from 27% to 81% (8,22,23). In the present study, returning to full activity rate was 71.9%, and twenty-three calves with polyarthritis were slaughtered due to unresponsiveness to medical treatment.

It was concluded that in addition to radiography and ultrasonography, thermography can also be used to detect joint problems in calves. Treatment of septic arthritis in calves is tough and time consuming, but it has good outcomes when the disease is involved only one joint and/or without other systemic disorders.

REFERENCES

1. Wichtel ME., Fenwick SG., Hunter J., Stephenson A., Martin D., Wichtek JJ., 2003. Septicaemia and septic arthritis in a neonatal calf caused by *Lactococcus lactis*. *Veterinary Record*, 153, 22-23.
2. Desrochers A., 2004. Septic Arthritis. In "Farm Animal Surgery", Ed: EM Fathman, 330-336, Elsevier, Philadelphia.
3. Brenner J., Ungar-Waron H., 1996. Environmental and managemental risk factors affecting morbidity and mortality of young calves. *Israel Journal of Veterinary Medicine*, 51, 3-8.
4. Hardy J., 2006. Etiology, diagnosis and treatment of septic arthritis, osteitis, and osteomyelitis in foals. *Clinical Techniques in Equine Practice*, 5, 309-317.
5. Francoz D., Desrochers A., Fecteau G., Desautels C., Latouche JS., Fortin M., 2005. Synovial fluid changes in induced infectious arthritis in calves. *Journal of Veterinary Internal Medicine*, 19, 336-343.
6. Gagea MI., Bateman KG., Shanahan RA., Van Dreumel T., McEwen BJ., Carman S., Archambault M., Caswell JL., 2006. Naturally occurring *Mycoplasma bovis*-associated pneumonia and polyarthritis in feedlot beef calves. *Journal of Veterinary Diagnostic Investigation*, 18, 29-40.
7. Heppelmann M., Kofler J., Meyer H., Rehage J., Starke A., 2009. Advances in surgical treatment of septic arthritis of the distal interphalangeal joint in cattle: A review. *The Veterinary Journal*, 182, 162-175.
8. Haerdi-Landerer MC., Habermacher J., Wenger B., Suter MM., Steiner A., 2010. Slow release antibiotics for treatment of septic arthritis in large animals. *The Veterinary Journal*, 184, 14-20.
9. Desrochers A., Francoz D., 2014. Clinical management of septic arthritis in cattle. *Veterinary Clinics of North America: Food Animal Practice*, 30, 177-203.
10. Kofler J., Geissbühler U., Steiner A., 2014. Diagnostic imaging in bovine orthopedics. *Veterinary Clinics of North America: Food Animal Practice*, 30, 11-53.
11. Yanmaz LE., Okumus Z., Dogan E., 2007. Instrumentation of thermography and its applications in horses. *Journal of Animal and Veterinary Advances*, 6, 858-862.
12. Yanmaz LE., Okumus Z., 2014. Using infrared thermography to detect corneal and extremity temperatures of healthy horses. *Israel Journal of Veterinary Medicine*, 69, 20-23.
13. Nichols S., Larde H., 2014. Noninfectious joint disease in cattle. *Veterinary Clinics of North America: Food Animal Practice*, 30, 205-223.

14. Fubini S., Ducharme N., 2004. Farm Animal Surgery. 477-484, St Louis, Missouri.
15. Quinn PJ., Carter ME., Markey B., Carter GR., 1994. Clinical Veterinary Microbiology. 118-155, Mosby-Wolfe, London.
16. CLSI, 2013. Performance standards for antimicrobial susceptibility testing; Twenty-Third Informational Supplement. M100-S23. Clinical Laboratory Standards Institute, Wayne, PA.
17. Rohde C., Anderson DE., Desrochers A., St-Jean G., Hull BL., Rings DM., 2000. Synovial fluid analysis in cattle: A review of 130 cases. *Veterinary Surgery*, 29, 341-346.
18. Soroko M., Henklewski R., Filipowski H., Jodkowska E., 2013. The effectiveness of thermographic analysis in equine orthopedics. *Journal of Equine Veterinary Science*, 33, 760-762.
19. Redaelli V., Bergero D., Zucca E., Ferrucci F., Costa LN., Luzi F., 2014. Use of thermography techniques in equines: principles and applications. *Journal of Equine Veterinary Science*, 34, 345-350.
20. Basawaraj NG., Keshavamurthy M., Giridhar AG., Srinath MG., 2012. Role of ultrasonography in the diagnosis of septic arthritis of hip in infants. *International Journal of Biological and Medical Research*, 3, 1889-1891.
21. Steel CM., Hunt AR., Adams PL., Robertson ID., Chicken C., Yovich JV., Stick JA., 1999. Factors associated with prognosis for survival and athletic use in foals with septic arthritis: 93 cases (1987–1994). *Journal of the American Veterinary Medical Association*, 215, 973-977.
22. Meijer MC., Van Weeren PR., Rijkenhuizen AB., 2000. Clinical experiences of treating septic arthritis in the equine by repeated joint lavage: a series of 39 cases. *Journal of Veterinary Medicine Series A-Physiology Pathology Clinical Medicine*, 47, 351-365.
23. Nuss K., 2003. Septische arthritis von schulter- und hüftgelenk beim rind: Diagnose und therapie. *Schweizer Archiv für Tierheilkunde*, 145, 455-463.