

## ASPIRATION OF BARIUM CONTRAST MEDIUM IN AN ELDERLY MAN WITH DISORDERED SWALLOWING

(Received 11 November, 1994)

**B. Bağcı Ceyhan, M.D.\* / T. Çelikel, M.D.\* / M. Koç, M.D.\*\*\*\*  
R. Ahıskalı, M.D.\*\* / T. Biren, M.D.\*\*\* / Ç. Ataizi Çelikel, M.D.\*\*\*\*\***

\* Associate Professor, Department of Pulmonary Medicine, Faculty of Medicine, Marmara University, Istanbul, Turkey.

\*\* Assistant Professor, Department of Pathology, Faculty of Medicine, Marmara University, Istanbul, Turkey.

\*\*\* Assistant Professor, Department of Radiology, Faculty of Medicine, Marmara University, Istanbul, Turkey.

\*\*\*\* Resident, Department of Pulmonary Medicine, Faculty of Medicine, Marmara University, Istanbul, Turkey.

\*\*\*\*\* Resident, Department of Pathology, Faculty of Medicine, Marmara University, Istanbul, Turkey.

### SUMMARY

The aspiration of contrast medium during the investigation of gastrointestinal diseases is a well recognized hazard, particularly in patients with swallowing disorders. A case is reported in which accidental aspiration of contrast barium occurred owing to disordered swallowing in an elderly man. The infiltration on chest x-ray persisted 2 years after barium contrast aspiration. Inflammatory reaction and refractile, granular material observed in lung biopsy specimens suggested barium-induced pneumonitis.

It is concluded that particular care should be taken in the radiological examination of such patients.

**Key Words :** Aspiration, barium contrast, pneumonitis.

### INTRODUCTION

A recent report stressed the dangers of a barium-sulphate aspiration in the elderly patients while using a high density suspension (1). However, lower density barium contrast may also be harmful to the lung (2). We report a case of barium-induced pneumonitis following the aspiration of a low density barium sulphate suspension during the investigation of gastrointestinal hemorrhage.

### CASE REPORT

A 72 year-old man was referred to our hospital for evaluation of productive cough and dyspnea progressing over a 2 years period, with particular worsening over the last 6 months. The patient complained of productive cough and exertional

dyspnea, but he did not have fever or chest pain. Physical examination revealed diffuse bilateral rales in the lung and neurologic examination revealed pseudobulbar palsy and right-sided hemiparesis. The hemiparesis was related to head trauma 40 years previously, but the dysphagia had been present for only two years. He had 40 pack-year smoking history. His past medical history was significant for recurrent gastrointestinal bleeding. He had been admitted to a hospital with persistent abdominal pain, nausea and vomiting 2 years previously. At that time, barium examination had been attempted but had not been successful, the patient had aspirated barium contrast medium (100% w/v). Endoscopically a peptic ulcer had been seen in the bulbous and a small oozing hemorrhage visualized. The ulcer healed completely with medical treatment. Chest x-ray, at that time, had showed contrast material in the bronchi in the bibasilar zone (Fig. 1). On the present admission, 2 years after barium contrast medium aspiration, chest x-ray revealed diffuse infiltration, particularly in the right lower and middle zones (Fig. 2). This appearance mimicked the previous chest x-rays, although infiltration was less prominent. Unfortunately, the patient could not cooperate in spirometric analysis. Arterial blood gases revealed mild hypoxemia at room air. A thin sectioned computed tomographic scan of the thorax disclosed bibasilar parenchymal high density reticular infiltrations which caused linear artifacts (Fig.3). Bronchoalveolar lavage demonstrated dirty-white colored fluid; transbronchial biopsy of the right lower zone showed refractile, granular material engulfed by alveolar macrophages, interstitial mononuclear cellular infiltration, rare multinucleated giant cells and minute granuloma (Figs. 4,5). It has been suspected that this granular material was barium medium. Barium contrast medium aspiration history and high density artifact appearance in the tomographic scan of the thorax supported this diagnosis.

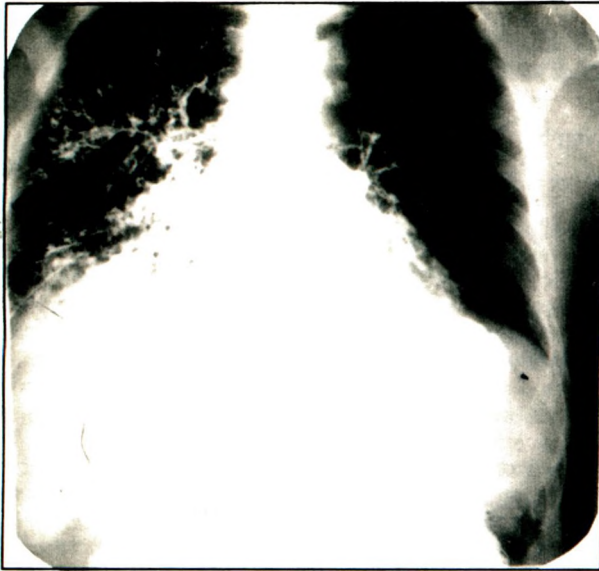


Fig. 1: Barium - bronchography immediately after aspiration

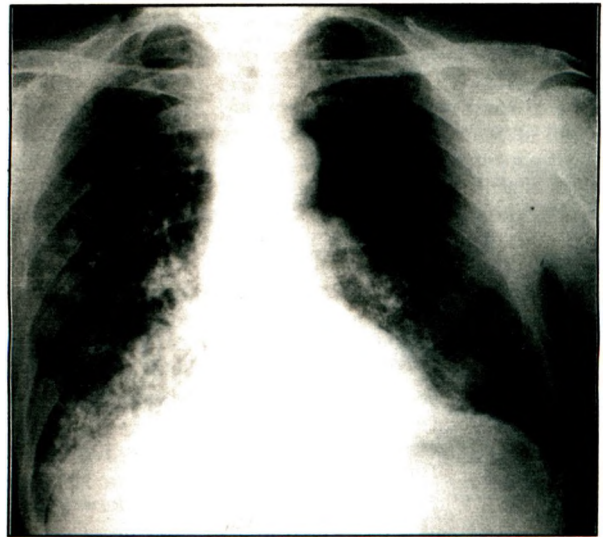


Fig. 2: Chest x-ray showing bilateral infiltration 2 years after the aspiration

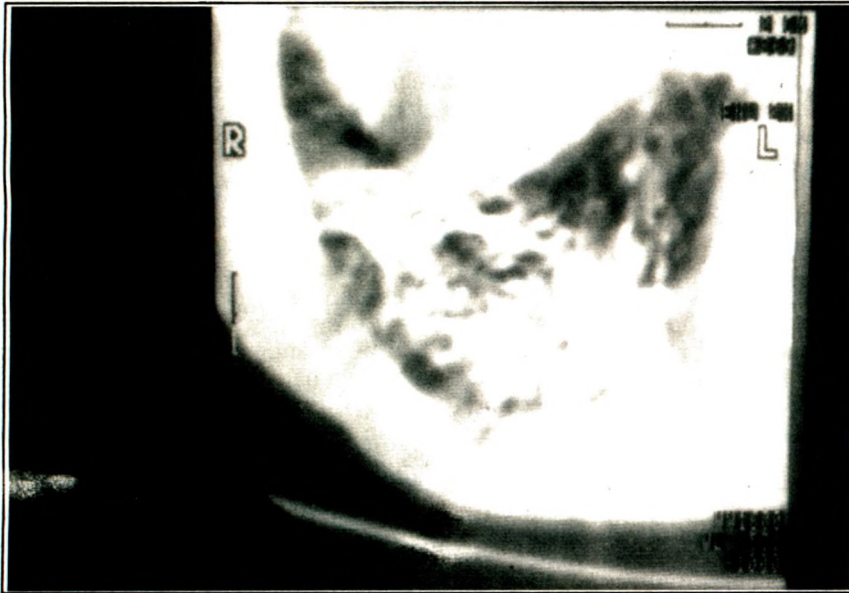


Fig. 3:  
CT-scanning of the thorax  
showing contrast artifact

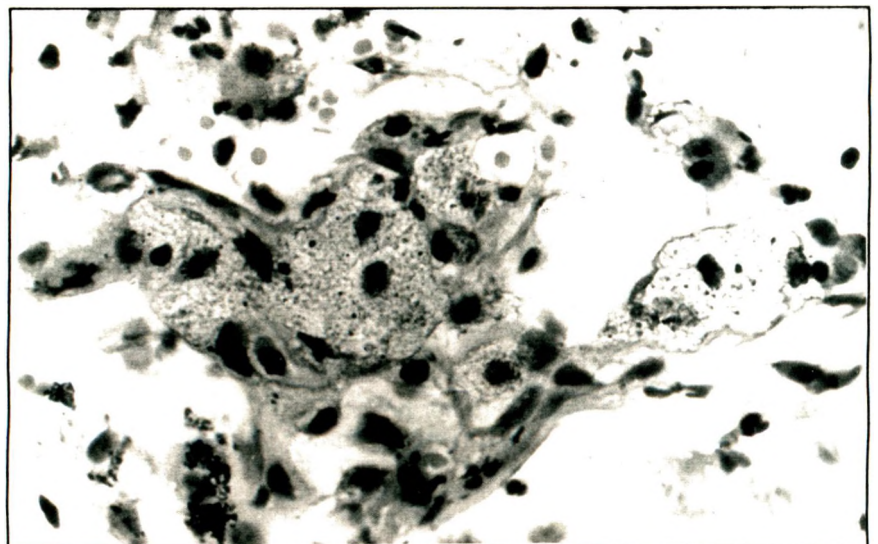


Fig. 4:  
Histologic section showing  
granular refractile material in  
the macrophages



**Fig. 5:**  
Histologic section showing  
diffuse interstitial thickening

## DISCUSSION

It has been widely accepted that pulmonary complications following the aspiration of barium sulphate were confined to the use of the high density commercial preparations. The hazard of aspiration of high density barium preparations in elderly and debilitated patients with dysphagia has been emphasized in two elderly women with disordered swallowing where there was pulmonary inflammatory reaction followed within a few hours by death (1). However, one case illustrated lower density preparations may also be the cause of significant morbidity. 100 percent barium sulphate suspension caused acute chemical pneumonitis (2). 100% w/v barium sulphate was given to our patient and the pneumonitis occurred. It has been shown that the majority of hypersensitivity reactions to barium preparations occur within fifteen minutes of aspiration and the majority of patients exhibit cutaneous reactions, 8% of 106 reactions were respiratory in nature (3). Although these reactions are short-term effects, in our case the acute reaction was not observed and the barium-induced pneumonitis persisted 2 years.

Commercial barium preparations include various additives. The identification of the offending additives is difficult in a clinical setting. In our case, ingredients of the contrast-medium were 100% w/v barium sulphate, metil paraben, propilparaben, saccharin sodium and, mint. Many of these chemicals may be capable of causing reactions in the lung. We believe that commercial barium deserves further investigations to find the offending molecule.

It has been shown that pure barium sulphate produces histiocyte reaction and granuloma formation in the mediastinum of rats, contrast agent being visible intracellularly with giant cells at 8 and 42 days (4). Commercial barium sulphate preparation 100% w/v produced the same reaction with contrast deposition in the mediastinum except that giant cells were not seen even at 42 days (4). The same authors evaluated the reactions of pure barium and 100% w/v commercial barium preparation in the rat lung, finding similar results (5). In the same study, the contrast materials, amipaque and hexabrix produced no significant histologic reactions in the rat lungs. These animal studies have shown that low density barium medium is not harmless in the bronchial tree. In our patient, pathologic examination of the lung tissue revealed similar findings, such as histiocyte reaction and granuloma.

The aspiration of contrast medium during the investigation of the upper gastrointestinal system is a well recognized hazard. It is therefore essential that the contrast medium administered is non-irritant to the lungs. In the literature, all of the respiratory reactions were noted in early phases. To our knowledge, our case is the first one where the reaction persisted 2 years and possibly will continue longer. Patients known to be at risk of aspiration should be identified as such on the x-ray request form. The radiologist is then well-informed and able to terminate the examination immediately if aspiration occurs.

**REFERENCES**

1. Gray C, Sivaloganathan S, Simpkins KC. Aspiration of high density barium-contrast medium causing acute pulmonary inflammation-report of two fatal cases in elderly women with disordered swallowing. *Clin Radiol* 1989;40(4):397-400.
2. Pracy JPM, Montgomery PQ, Reading N. Acute pneumonitis caused by low density barium sulphate aspiration. *J Laryngol Otol* 1993;107(4):347-348.
3. Janower ML. Hypersensitivity reactions after barium studies of the upper and lower gastrointestinal tract. *Radiology* 1986;161:139-140.
4. Giani AZ, ten Kate FJ, ten Berg GM, Hoomstra K. Experimental evaluation of various available contrast agents for use in the upper gastrointestinal tract in case of suspected leakage: effects on mediastinum. *Br J Radiol* 1985;58(691):585-592.
5. Giani AZ, ten Kate FJ, ten Berg RG, Hoomstra K. Experimental evaluation of various available contrast agents for use in the upper gastrointestinal tract in case of suspected leakage. Effects on the lung. *Br J Radiol* 1984;57(682):895-901.