

## Giant cervical myoma associated with actinomycosis: a rare cause of uremia

Banuhan Sahin<sup>1</sup>, Aysun Karabulut<sup>2</sup>, Omer Demirtas<sup>2</sup>, Habibe Radiye Ertur<sup>2</sup>, Nevzat Karabulut<sup>3</sup>

<sup>1</sup>Department of Obstetrics and Gynecology, Kars Harakani State Hospital, Kars, Turkey

<sup>2</sup>Department of Obstetrics and Gynecology, Pamukkale University School of Medicine, Denizli, Turkey

<sup>3</sup>Department of Radiology, Pamukkale University School of Medicine, Denizli, Turkey

### ABSTRACT

Myomas are commonly seen benign tumors of the uterus; they may cause a great variety of symptoms depending on the location. Herein, we presented an unusual case of giant cervical myoma with associated actinomycosis resulting in bilateral hydronephrosis and uremia. A 42-year-old woman was admitted to emergency service with anuria and confusion. She had an intra-abdominal mass extending 4-5 cm above the level of umbilicus. The hemoglobin level was 5.1 g/dl and creatinine level was 5.2 mg/dl. Magnetic resonance imaging revealed enlarged uterus with intrauterine device which was displaced up above the level of umbilicus due to a large cervical mass measuring 16.5x11.5x12 cm, tortuous hydroureters on both sites and left tuba ovarian abscess. A huge cervical lobulated mass which was pressing both ureters and filling the lower abdomen, and left tuba ovarian abscess with dense adhesions which was created by actinomycotic infection were detected on explorative laparotomy. Uremia was normalized gradually following hysterectomy, and the patient was discharged with penicillin treatment. Although myomas are the benign tumors, they may mimic the genital malignancy, and may cause life-threatening complications such as renal failure and uremia.

*Eur Res J 2016;2(3):222-224*

**Keywords:** Myoma; uremia; actinomycosis

### Introduction

Uterine myoma is a benign genital tract tumor affecting approximately 50% of the women over 35 years of age [1]. It originates from smooth muscle of the uterus and may rarely reach to giant sizes. The clinical symptoms vary according to localization of the tumor and can adversely affect the quality of life, and may cause compressive effect on vital organs such

as lungs and heart [2]. Urinary symptoms, like increased frequency of micturition or intermittent urination were frequently seen especially in women with big myomas [2]. We could only detect one case of myoma causing uremia in our literature search [3].

Herein, we presented an unusual case of giant cervical myoma with associated actinomycosis resulting in bilateral hydronephrosis and uremia.

*Address for correspondence:*

Aysun Karabulut, MD., Pamukkale University School of Medicine, Department of Obstetrics and Gynecology, Camlaralti mah., 20070 Denizli, Turkey

E-mail: [aysunkarabulut@yahoo.com](mailto:aysunkarabulut@yahoo.com)

Received: January 25, 2016; Accepted: April 07, 2016; Published Online: July 27, 2016

## Case Presentation

A 42-year-old pre-menopausal woman was admitted to emergency service with anuria and confusion. Physical examination revealed an intra-abdominal mass extending 4-5 cm above the level of umbilicus. The cervical os could not be visualized due to compressive effect of the mass on pelvic exam. The hemoglobin level was 5.1 g/dl and leukocyte count was 30,950/mm<sup>3</sup> with neutrophil predominance. Heavy menstruation lasting 7-8 days and 20 to 25 days apart were noticeable in medical history of the patient. Serum creatinine level was 2.59 mg/dl on admission, and increased progressively to 5.2 mg/dl on the next day. Carcinoembryonic antigen, cancer antigen 125, and alpha-fetoprotein levels were within normal limits. A giant mass extending 4-5 cm above the umbilicus was detected on sonographic exam. Magnetic resonance imaging (MRI) revealed enlarged uterus with intrauterine device which was displaced up above the level of umbilicus due to a large cervical mass measuring 16.5x11.5x12 cm, tortuous hydroureters on both sites and left tuba-ovarian abscess (Figure 1). There was no regional nodal or distant metastasis detected on MRI.

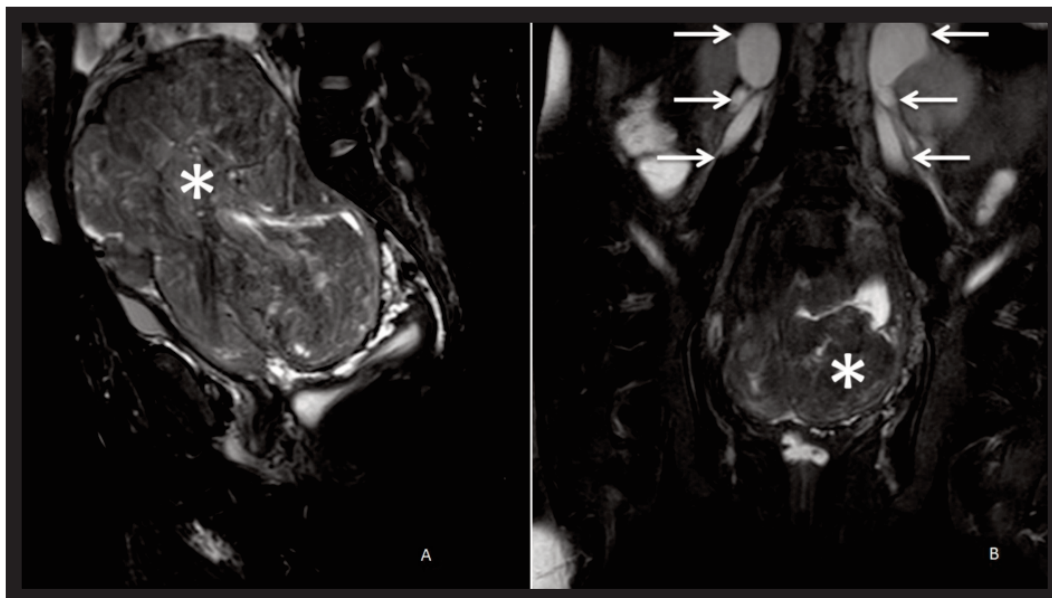
Blood transfusion and hemodialysis were performed to improve general condition of the patient. Explorative laparotomy revealed enlarged, lobulated cervical mass occupying the whole lower abdomen and compressing the ureters with left tuba-ovarian abscess (Figure 2). Ureters were encircling the outer surface of the myoma on both sites. Both ureters and

dense adhesions were dissected from the myoma and total hysterectomy and bilateral salpingo-oophorectomy were performed. Pathologic exam revealed 16.5x11.5x12 cm cervical myoma weighing 1,620 g, distorting the uterine shape and left tuba-ovarian abscess infiltrated with actinomycosis colonies. Histologic signs of malignancy were not found microscopically.

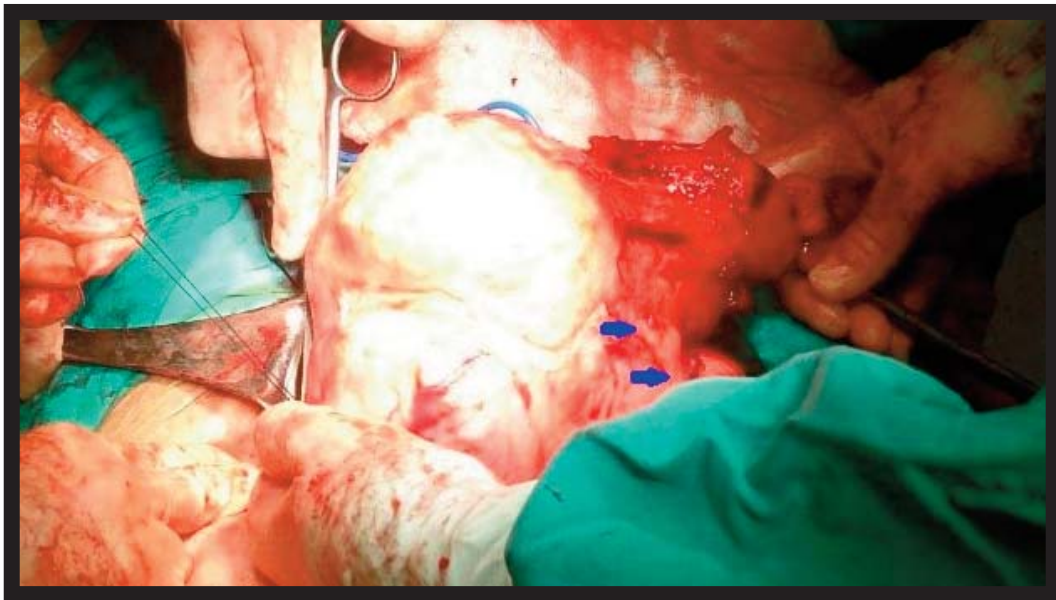
Penicillin treatment was started in the postoperative period. The patient was completely free of symptoms and had normal serum creatinine levels within two weeks.

## Discussion

Our case is important to show that a benign condition such as myoma may result in a life-threatening condition. The size and location determine the presence and degree of the symptoms [2]. Many cases of uterine leiomyoma causing intra-abdominal compression have been reported previously, but only one case of uremia developed secondary to ureteral compression of myoma was seen in our literature search [2]. Renal failure due to ureteral obstruction may be seen in advanced cervical cancer [4]. However, renal failure due to cervical myoma is not an expected situation, because myomas usually give symptoms such as bleeding, pain or problems of urination before reaching to this stage [1]. Our patient had deep anemia, confusion, and uremia on admission. Probably due to low socio-cultural level, she did not



**Figure 1.** Sagittal (A) and coronal (B) magnetic resonance images show multilobulated huge cervical mass (*asterisks*) filling the pelvis and causing bilateral hydroureteronephrosis (*arrows*).



**Figure 2.** Intraoperative appearance of the uterine mass. Blue arrows show the pathway of left ureter.

admitted previously and chronic anemia was developed progressively which causes depressed cognitive functions. The cervical myoma enlarged and extended into the parametrium. As time goes on, obstructed ureters led to hydronephrosis, and eventually renal failure. Increased uremia further deteriorated the situation and resulted in confusion.

Although, we detected actinomycotic infection which may cause fibrosis in retroperitoneal area, tubal area was moved upwards due to large myoma, and myoma itself was the reason for the ureteral compression. Actinomycotic infection was known to be associated with the presence of foreign body, and most often with use of intra-uterine contraceptive device. It may cause abscess formation and creates dense adhesions [5]. There was left tuba-ovarian abscess in our case. Fever is usually not observed despite elevated leucocytes with neutrophil predominance. Similarly we observed no fever in clinical follow-up, but leukocyte count was highly elevated with neutrophil predominance. Antibiotic treatment should be dictated by the clinical setting.

## Conclusion

In conclusion, although myomas are benign tumors of the uterus, they may cause life-threatening complications, and mimic genital malignancy. Presence of actinomycotic infection may further complicate the situation by causing tuba-ovarian abscess formation. Imaging modalities are helpful to

visualize myoma and its compressive effects in such complicated cases.

### *Informed Consent*

Written informed consent was obtained from the patient for the publication of this case report.

### *Conflict of interest*

The authors declared that there are no potential conflicts of interest with respect to the research, authorship, and/or publication of this article.

### *Acknowledgement*

The article was presented as P-101 poster in TJOD 13<sup>th</sup> Congress, May 11-15, 2015, Antalya, Turkey

## References

- [1] Hoffman B. Pelvic mass. In: Williams gynecology. Schorge J, editor. Dallas, Texas: McGraw-Hill Companies, 2008, p.197.
- [2] Inaba F, Maekawa I, Inaba N. Giant myomas of the uterus. *Int J Gynaecol Obstet* 2005;88:325-6.
- [3] Heimer G, Axelsson O, Johnson P. Uterine myoma causing uremia in a 15-year-old girl. *Gynecol Obstet Invest* 1991;32:247-8.
- [4] Plesinac-Karapandzic V, Masulovic D, Markovic B, Djuric-Stefanovic A, Plesinac S, Vucicevic D, et al. Percutaneous nephrostomy in the management of advanced and terminal-stage gynecologic malignancies: outcome and complications. *Eur J Gynaecol Oncol* 2010;31:645-50.
- [5] Valour F, Senechal A, Dupieux C, Karsenty J, Lustig S, Breton P, et al. Actinomycosis: etiology, clinical features, diagnosis, treatment, and management. *Infect Drug Resist* 2014;7:183-97.