

RELIABILITY OF FASCIOCUTANEOUS FLAPS ON THE BASE OF BURN SCAR BY USING DOPPLER COLOR FLOW IMAGING IN THE PREOPERATIVE PLANNING

(Received 18 July, 1996)

E. Kışlaoğlu, M.D.* / F. Yüksel, M.D.* / Ç. Başekim, M.D.**
E. Karacaoğlu, M.D.*** / C. Uçar, M.D.*****

* *Professor, Department of Plastic and Reconstructive Surgery, Gülhane Military Medical Academy, Istanbul, Turkey.*

** *Assistant Professor, Department of Radiology, Gülhane Military Medical Academy, Haydarpaşa Training Hospital, Istanbul, Turkey.*

*** *Resident, Department of Plastic and Reconstructive Surgery, Gülhane Military Medical Academy, Istanbul, Turkey.*

ABSTRACT

Objective: As perforator vessels play an important role in fasciocutaneous flap coverage their anatomical prediction is essential in flap designing. Lack of adequate vascular supply to the burn scar tissues, makes them unusual and vulnerable to distal necrosis in reconstructive procedures. We performed this study in order to achieve a better and safer design of fasciocutaneous flaps for burn scars by using Doppler color flow imaging.

Methods: In this study, six patients with troubles on their burn scar areas were treated with fasciocutaneous flaps, each based on an adjacent, single perforator vessel. Doppler with conventional ultrasound was used for location and calibration of perforator vessels on individual basis.

Results: No signs of compromise in flap circulation was observed and flaps were all organized in accuracy.

Conclusion: It is concluded that more reliable and safer design of fasciocutaneous flaps can be detected by using Doppler color flow imaging.

Key Words: Fasciocutaneous flaps, Doppler color flow imaging.

INTRODUCTION

It is a challenge to repair the tissue defects on the upper and lower extremities with exposed deep structures such as bone, nerve, joint and tendons or

complicated wounds, by leaving minimal deformity. Various methods, some requiring two-stage operations, can be used but most result in unacceptable outcome or great donor-site morbidity. Fasciocutaneous flaps seem to balance those multiple factors including recipient site requirements, donor site morbidity, operative complexity and patient factors for closing the tissue defects on extremities,(1) Reintroduction of the fasciocutaneous flap principle by Ponten(2) after the early work of Manhot,(3) Salmon,(4) Milton(5) and McGregor and Jackson,(6) has a great promise as a viable reconstructive option in poorly vascularized recipient areas (7). Beside the utility and simplicity of those flaps, the sources of blood supply to the fasciocutaneous flaps are varied and may include a perforating vessel from the underlying muscle or direct or longitudinal vessels coursing on top of the fascia (8). Relatively high frequency of anomalies of deep fascial perforators are an obstacle to plan the fasciocutaneous flaps with safety. Variation in their diameter and localization differ even in the same individual, whereas symmetry is present in only a third (9). Therefore, the ability to image and locate these vessels preoperatively will probably improve the safety and reliability of local flaps based on these flaps.

Inadequate vascular supply of burn scar makes them more vulnerable to tissue necrosis than any reconstructive procedure. Burn scar has a usual pattern of healing but an unusual outcome of histologic pattern. Unusual histologic pattern and vascularization without any dominant perforator vessel make them inappropriate to primary or secondary closures or sometimes flap and grafting methods (10). Although grafting is an alternative to

cover the skin defects after burn scar release or resection, it is mostly unreliable in complicated cases. The fasciocutaneous flap coverage as one of the most reliable reconstructive procedures may result in distal flap necrosis. So, it must be based at least on an intact, high caliber perforator vessel.

Being noninvasive and simple to apply, Doppler color flow imaging is used in the preoperative assessment of flap vascular supply (8,9,11). It provides important and detailed information about blood flow velocity and volume within the perforator, so that it enhances the identification of these perforators of the notoriously inconsistent fasciocutaneous flap system (12).

PATIENTS AND METHODS

Preoperative evaluation of the fasciocutaneous perforators in donor areas just around the recipient sites, was done for 6 patients with Doppler color flow imaging. Each imaging was carried out by the same qualified radiologist using the Toshiba SSA 270 A color Doppler ultrasound system (7,5 Mhz high - resolution linear - array transducer). In the technique, bloodstream, approaching to the probe becomes red on the screen whereas streams, getting away from the probe becomes blue. So, for the perforator system, red color means arterial and blue means venous structures.

All the patients were males with ages ranging from 20 to 42. Burn scars were on the upper extremities in 2 cases and on the lower extremities in the rest (Table I). All the burn scar areas were the end result of second and third degree burns healed secondarily. After passing at least two year-period, they were accompanied by late complications including atonic wounds, pressure on or adhesion to the underlying structures. All but excluding one on a forearm level, were tried to be treated previously by excision, primary closure or grafting procedures. Unfortunately, they all failed.

Perforators were evaluated just around the burn scar areas that would be adequate to perform elevation of flap with a proximally based pedicle. Perforator vessel depth from skin and their calibrations were recorded for all cases (Table I). A picture of each image was taken for permanent display. As soon as evaluation was completed, pertinent perforator was mapped out in region of the proposed flap to allow its incorporation within the necessary flap boundary. Only one perforator in an adequate quality was determined in each case and the flap was so designed that its base was located on that vessel. All the predetermined perforators were supporting overlying subdermal vascular plexus and they had several minor branches (not exceeding 2 cm. in length), feeding the surrounding fascial tissues.

Cases

Case 1: A 21-year-old electrician had an electrical burn on the left upper extremity 7 years ago. It was a 10x12 cm. left posterior antebrachial deep second degree electrical burn. A long term conservative therapy with only periodic dressings had resulted in fixed antebrachial skin to the posterior of ulna, limited extension of ring and small fingers due to adhesion in flexor tendon system and tingling sense on the ulnar side of his hand when tapping due to pressure onto the ulnar nerve. By means of Doppler color flow imaging, a laterally 10x20 cm, superiorly based antebrachial fasciocutaneous flap was designed preoperatively on the posterior aspect of radius. The diameter of perforator was 1.2 mm and its depth from skin was 6.7 m. Therefore, following resection of the burn scar, the ulnar nerve and flexor tendons were left free and a fasciocutaneous flap nourished by this perforator was elevated and transposed to the defect. Donor site was covered with split-thickness skin graft harvested from his right arm. Flap organization was achieved without any distal flap necrosis (Fig.1).

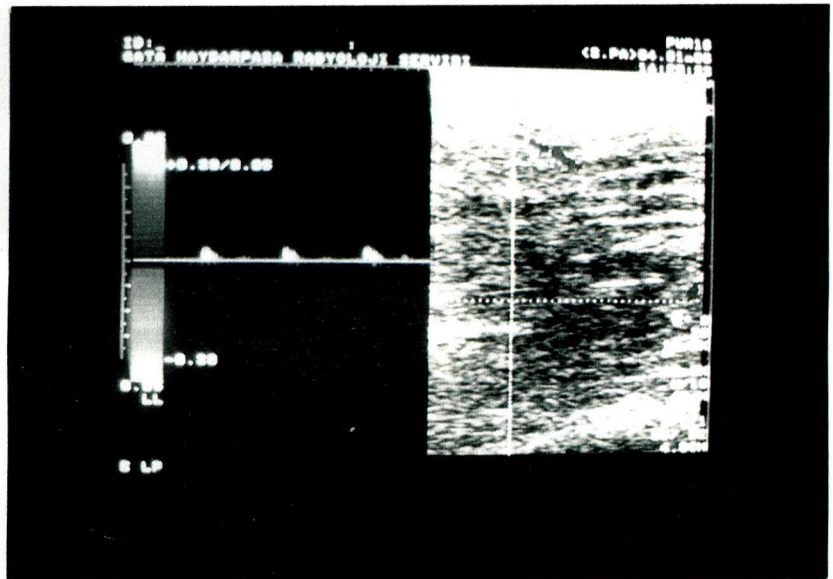
Table I. Treatment sites of cases and calibration and depth of perforator vessels.

Case	Treatment Site	Diameter of Perforator (mm.)	Depth From Skin (mm.)	Size of Flaps (cm.)
1.	Left, Posterior forearm	1.2	6.7	10 x 20
2.	Left, Anterior thigh	1.4	6.2	12 x 25
3.	Right, Pretibial region	1.6	6.9	9 x 2.5
4.	Left, Anterior elbow	1.4	7.2	8 x 16
5.	Right, Lateral thigh	1.8	6.4	14 x 16
6.	Left, Pretibial region	1.4	6.4	8 x 16

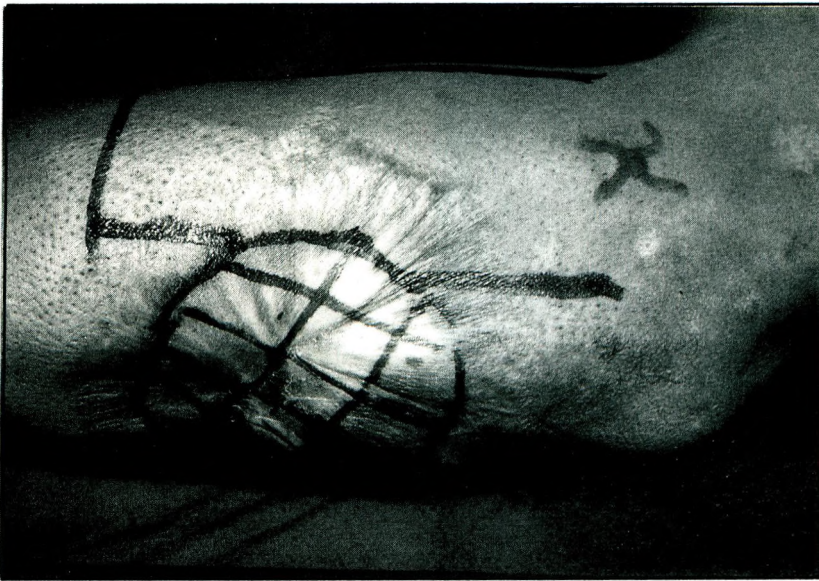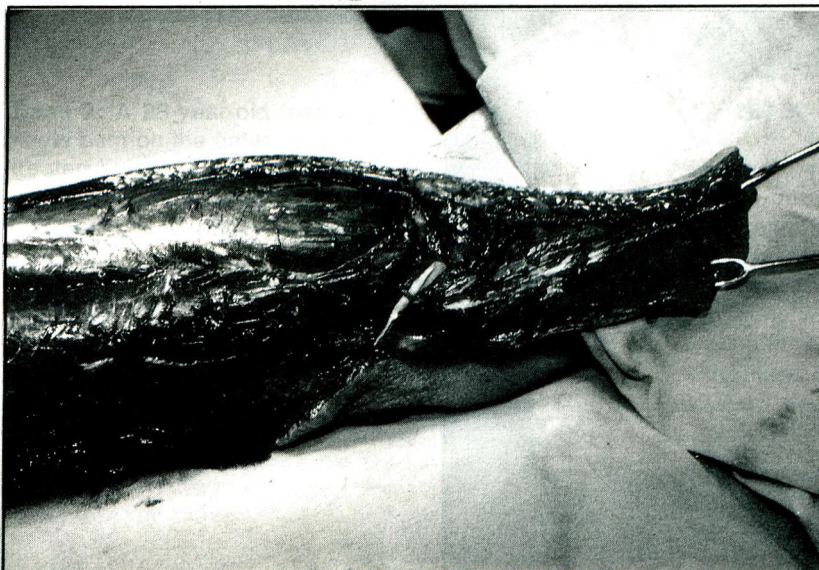


Fig 1

a: Posterior forearm burn scar.



b: Doppler color flow imaging.



c: Perforator vessel demonstrated after dissection.

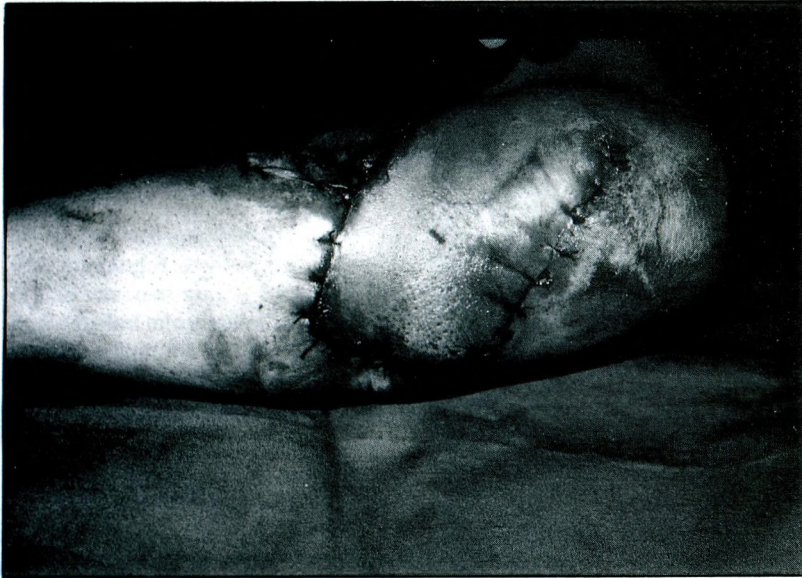
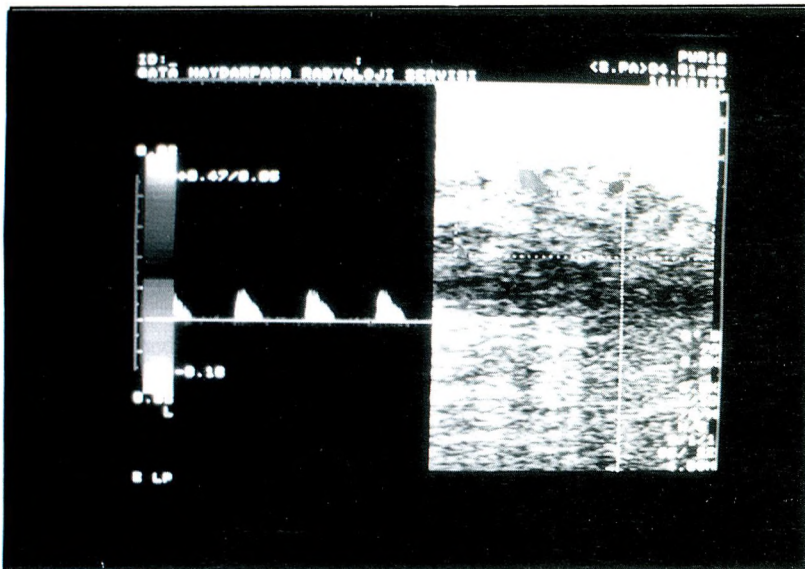
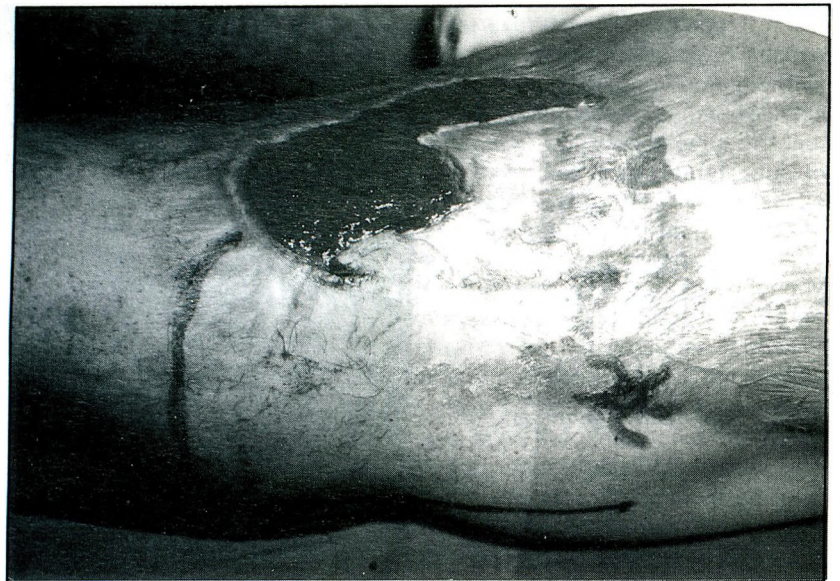

Fig 1

d: Appearance of flap on the post-op. 2nd day.

Fig 2

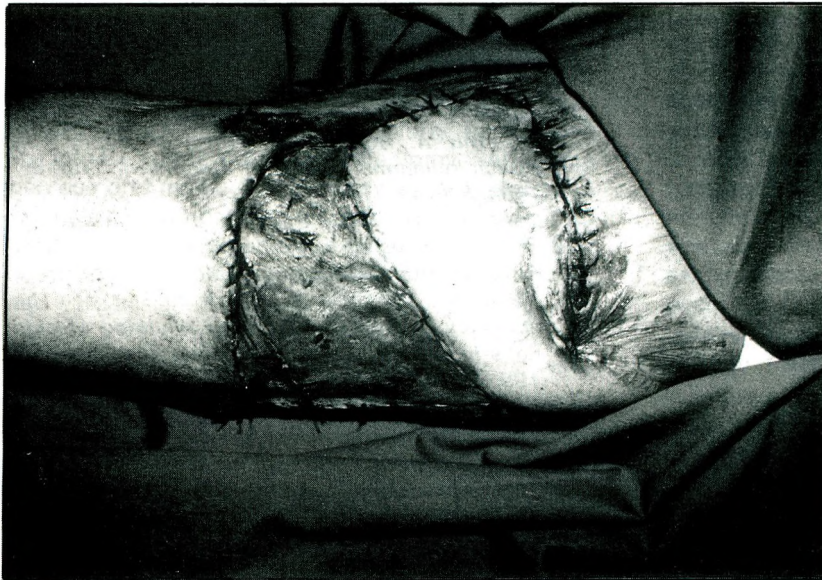
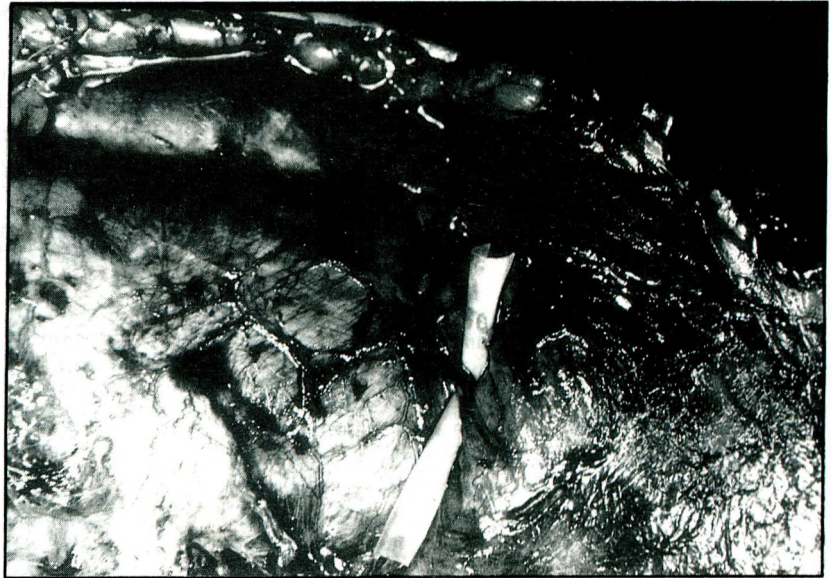a: Atonic wound on the left anterior thigh



b: Doppler color flow imaging,

Fig 2

c: Perforator vessel demonstrated after dissection,



d: Appearance of flap on the post-op. 2nd day.

Case 2: A 28-year-old man suffered a third degree flame burn on the anterior aspect of his left thigh and treated by grafting 3 years ago. One year later, an atonic wound has emerged due to friction caused by his trousers and experienced several unsuccessful grafting procedures. The wound was 15x6 cm.in diameter. Using Doppler color imaging, a perforator with 1.4 mm in caliber and 6.2 mm depth from skin was designed on the lateral site. This proximally based, lateral fasciocutaneous flap was transposed to cover the defect. Donor site was grafted. The microcirculation was satisfactory even in the induration zone that made the medial border of the flap. (Fig.2).

RESULTS

After incision, flaps were dissected subfascially, because great attention was paid not to cause any injuries even to the minor fascial vascular branches. These vessels were really present on the marked points and at the predetermined caliber.No dissections were continued beyond the perforators, because they might cause tension on these vessels. All the flaps were proximally based. Recipient site excision and release were followed by flap transposition and closure.

Neither signs of sloughing nor congestion suggesting compromise in flap circulation were observed .in all

cases in the follow-up period, even on the first post-operative day. Patients were followed-up at least 6 months. The end result was satisfactory for each case.

DISCUSSION

Fasciocutaneous flaps require the following criteria in reconstructing a wound (13):

- 1- Challenge for recipient site requirements.
- 2- Acceptable donor site morbidity.
- 3- Easy dissection and elevation.
- 4- Appropriation for poorly vascularized defects, especially in burn scars in which wound contraction and disintegrity of vascular network make them unresponsive to primary or secondary closure. There are some muscles, musculocutaneous and free flap choices for coverage. But, they usually cause great donor site morbidities, unacceptable either for the patient or surgeon. Local skin flaps are also alternatives, but they are unreliable especially in burn scars.

Numerous anomalies, even for mirror-image regions of the same person, have precluded a systemic mapping of the location, size and importance of fascial perforators that nourish the described fasciocutaneous flaps (8). It must especially be emphasized in burn scar tissues, because their unusual and unpredictable vascular anatomy makes them vulnerable to vascular compromise when used as fasciocutaneous flaps. Perforator vessels, if really present, are in limited numbers in these territories and must be determined preoperatively.

The hand-held Doppler is incapable of distinguishing flow originating from the perforators versus axial vessels (9). The advent of higher frequency transducers has made analysis of the superficial microcirculation possible. The combination of Doppler ultrasound with conventional ultrasonography can be used to evaluate superficial microcirculation preoperatively with accuracy. The resultant color flow Doppler imaging or color Duplex ultrasonography is a noninvasive, repetitive, accurate and easily performed way of evaluation in delineating the vascular map of a flap (14). It is really possible to determine the diameter of the perforator vessels and their extensions as they emerge from the fascia. However, correct estimation of their distances from the skin surface was not very important clinically, since the dissections were performed subfascially.

With the drawing as a template, the flap can be more precisely and rapidly dissected. In order to avoid partial or total tissue necrosis or to reduce flap failure incidence which are totally unacceptable outcomes for a plastic surgeon, color flow Doppler imaging can be used reliably.

REFERENCES

1. Daniel RK, Kerrigan CL Principle and physiology of skin flap surgery. In: McCarthy JG, ed. *Plastic surgery*, Boston: WB Saunders Company, 1990;279-302
2. Ponten B. Events leading to the rediscovery of the fasciocutaneous flap. In: Hallock GG, ed. *Fasciocutaneous flaps*. Boston: Blackwell Scientific, 1982;10-32
3. Manhot C. *The cutaneous arteries of the human body*. New York: Springer - Verlag, 1983;123-141
4. Salmon M. *Artere de la Peau*. Paris: Masson et Cie, 1973;136-194
5. Milton SH. Pedicled skin flaps: The fallacy of the length: width ratio. *Br J Surg* 1970;57:502-518.
6. Mc Gregor IA, Jackson IT. The groin flap. *Br J Plast Surg* 1972;25:3-9
7. Durak N, Kışlaoğlu E, Uzunismail A, Yüksel F, Özdemir A. Adipofasial turn-over flebin çok amaçlı kullanımı. *İst Tıp Fak Mecmuası*, (Turkey) 1994;2:36-41
8. Hallock GG. Evaluation of fasciocutaneous perforators using color Duplex imaging. *Plast Reconstr Surg* 1994;94:664-652
9. Miller RJ, Potporic Z, Colen BL, et al. The accuracy of Duplex US in the planning of skin flaps in the lower extremity. *Plast Reconstr Surg* 1995;95:1221-1229
10. Graham MF, Diegelmann RF, Cohen IK, et al. Effects of inflammation on wound healing: In vitro and in vivo studies. In: Hunt TK, ed. *Soft and hard tissue repair: Biological and clinical aspects*. New York: Praeger Scientific, 1984;361-381
11. Amerhauser A, Molleker BR, Mathets SJ, et al. Color flow ultrasound for delineating microsurgical vessels: A clinical and experimental study. *Ann Plast Surg* 1983; 30:193-199.
12. Merrit CR. Doppler color flow imaging. *J Clin Ultrasound* 1987;15:591-597
13. Tollhurst DF, Haeseker B, Zeeman RJ. The development of fasciocutaneous flap. *Ann Plast Surg* 1984;13:495-502.
14. Domonici CD, Pacifici A, Tinti A, et al. Preoperative and postoperative evaluation of latissimus dorsi myocutaneous flap vascularization by color Duplex scanning. *Plast Reconstr Surg* 1995;96:1358-1366.