

PHOTO QUIZ

Is the presence of diffuse gastric hypermetabolism enough to exclude a gastric tumour?

Salih ÖZGÜVEN, Fuat DEDE, Tunç ONES, Sabahat İNANIR, Tanju Yusuf ERDİL, Halil Turgut TUROGLU

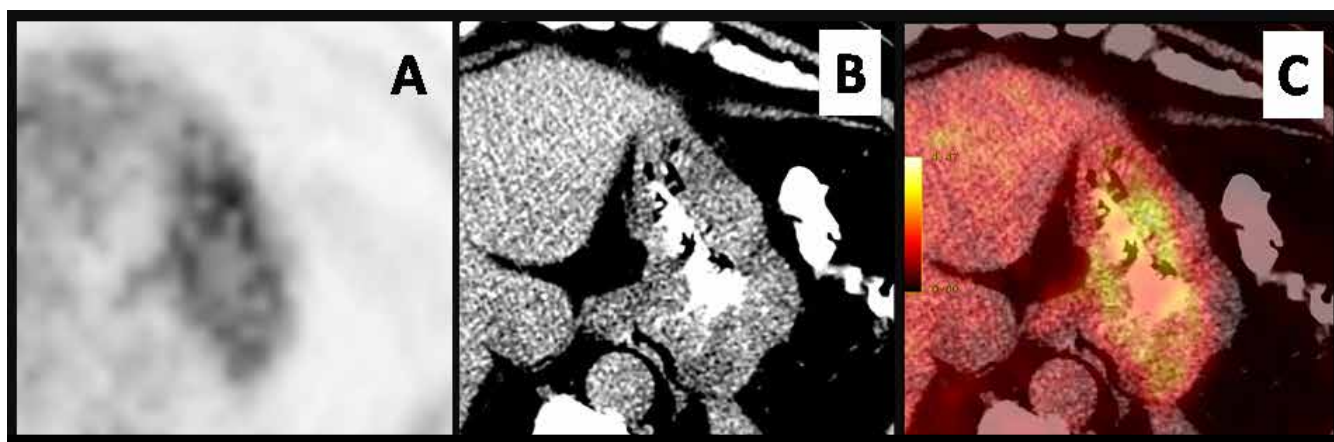

Figure 1. PET (A), CT (B), and PET/CT Fusion (C)

An 81-year-old male with a recently diagnosed gastric neuroendocrine tumour was admitted to the Nuclear Medicine Department. A fluorodeoxyglucose (FDG) positron emission tomography – computed tomography (PET/CT) study was requested for initial staging purposes. Oral contrast-enhanced axial PET/CT slices (Figure 1) at the level of the stomach demonstrated diffuse mild gastric hypermetabolism. There was no other pathological finding in the rest of the body.

Question: Based on the patient's history and FDG PET/CT findings, what is your diagnosis?

- A. Linitis plastica
- B. Physiological smooth muscle activity
- C. Inadequate study
- D. Gastritis

Salih Özgüven (✉), Fuat Dede, Tunç Ones, Sabahat İnanır, Tanju Yusuf Erdil, Halil Turgut Turoğlu
Department of Nuclear Medicine, School of Medicine, Marmara University,
Istanbul, Turkey
e-mail: drsozg@gmail.com

Submitted/Başvuru: 11.06.2013 - Accepted/Kabul: 19.07.2013

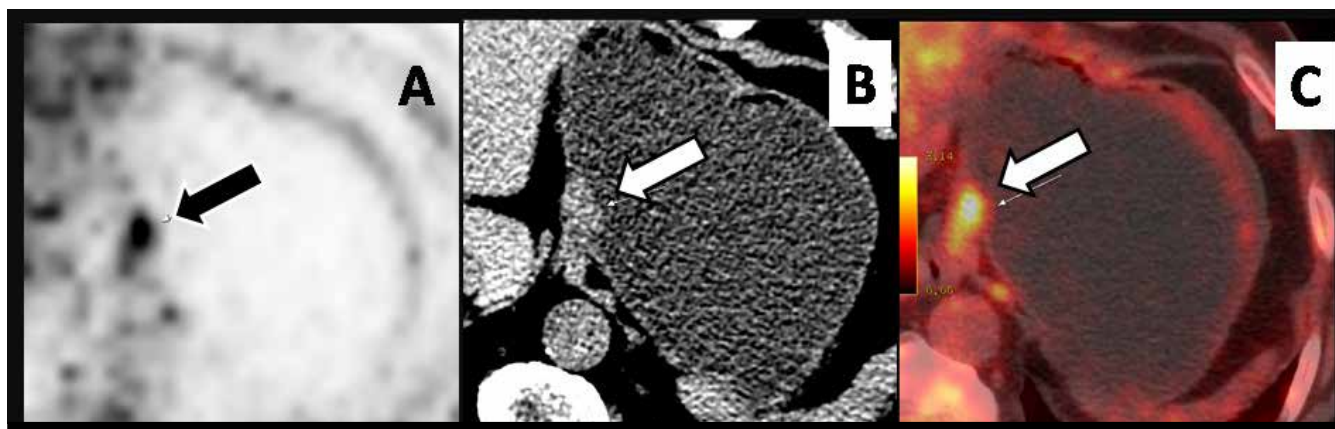


Figure 2. Mild-to-moderate hypermetabolic (A) nodular lesion is clearly seen at the cardia region on CT (B) and fusion image (C) of water-filled stomach with normal gastric wall thickness.

ANSWER to PHOTO QUIZ: The answer is C.

In this case, the presence of a tumour had been shown at the cardia of the stomach by upper endoscopy. However, on the routine FDG PET/CT study (Fig. 1) no tumour specific focal FDG uptake can be noticed in the cardiac region due to diffuse physiological gastric metabolism. We encouraged the patient to drink 700 ml of water after a whole body PET/CT scan and just before an additional supine position regional PET/CT scan, in order to eliminate physiological gastric activity and to visualize the gastric walls more clearly (Fig. 2). With this maneuver, a hypermetabolic focus suggesting a primary tumour appeared morphologically and metabolically.

Physiologic FDG can produce well-known diagnostic pitfalls, in the detection of disease in the stomach by causing either false negative or false positive results [1]. The gastric wall has variable FDG uptake patterns, partly because of smooth muscle activity or non-neoplastic inflammation that may be confused with malignancy [2, 3]. Distension makes it easier to delineate subtle mucosal abnormalities of the contracted gastric wall as pathologic [4]. Fortunately, these mucosal abnormalities disappear after liquid ingestion, most likely because the partial-volume effect produces a distended and thinned gastric wall. With this effect, liquid ingestion is useful in reducing false negative results in the evaluation of the stomach [5]. We have adopted the water ingestion method, to eliminate physiologic ^{18}F -FDG uptake in the contracted stomach. Additionally, as a second step, we have performed regional late scanning which may have a positive impact on

lesion detectability by increasing FDG uptake in the tumour and by decreasing physiological uptake of gastric tissue.

The sensitivity of PET in detecting neuroendocrine tumors is low due to their low FDG-avidity. Other than FDG, gastric neuroendocrine tumors (NETs) also accumulate Ga^{68} DOTATOC, Ga^{68} DOTATATE on PET scan, metaiodobenzylguanidine (MIBG) and octreotide on conventional scintigraphy; however, these are beyond the scope of this case presentation.

In conclusion, diffuse physiologic gastric hypermetabolism may obscure malignant foci and to overcome this, a simple maneuver, of having the patient drink water only and rescanning the distended stomach, can be used to improve the diagnostic accuracy of FDG PET in patients where malignancy is suspected.

References

1. Shreve P, Anzai Y, Wahl R. Pitfalls in oncologic diagnosis with FDG PET imaging: physiologic and benign variants. *Radiographics* 1999;19:61-77.
2. Cook GJR, Fogelman I, Maisey M. Normal physiological and benign pathological variants of 18-fluoro-2-deoxyglucose positron emission tomography scanning: potential for error in interpretation. *Semin Nucl Med* 1996;24:308-14. doi: 10.1016/S0001-2998(96)80006-7
3. Bischof-Delaloye A, Wahl RL. How high a level of FDG abdominal activity is considered normal? *J Nucl Med* 1995; 36(suppl):106P.
4. Horton KM, Fishman EK. Helical CT of the stomach: evaluation with water as an oral contrast agent. *AJR* 1998;171:1373-6. doi: 10.2214/ajr.171.5.9798881
5. Mijin Y, Hyun S C, Eunhye Y, et al. The role of gastric distention in differentiating recurrent tumor from physiologic uptake in the remnant stomach on ^{18}F -FDG PET. *J Nucl Med* 2005;46:953-7.