

## Case Report

# FIVE CASES OF CARCINOMA OF THE PAPILLA OF VATER WITH DOUBLE PRIMARY MALIGNANCIES AND REVIEW OF THE LITERATURE

(Received, 23 May 1997)

**C. Kalaycı, M.D.\* / O. Özdoğan, M.D.\*\*\* / S. Küllü, M.D.\*\*  
N. Tözün, M.D.\* / N. B. Ulusoy, M.D.\***

\* Professor, Department of Gastroenterology, Faculty of Medicine, Marmara University, Istanbul, Turkey.

\*\* Professor, Department of Pathology, Faculty of Medicine, Marmara University, Istanbul, Turkey.

\*\*\* Resident, Department of Gastroenterology, Faculty of Medicine, Marmara University Istanbul, Turkey.

## ABSTRACT

We report five cases of carcinoma of the ampulla of Vater with another primary malignancy diagnosed either synchronously or asynchronously. These cases were observed in a group of ten Vaterian carcinoma cases diagnosed between 1988 and 1993. These cases include the first Vaterian carcinoma cases with previous breast and esophagus tumors and the second case in the literature with simultaneous colonic carcinoma in the absence of familial polyposis coli and/or Gardner's syndrome. Compared with the other cancer series, the expected second primary malignancy rate in Vaterian carcinoma cases is much higher. Therefore, we suggest that, patients with an adenocarcinoma of the papilla of Vater should be investigated for the presence of another primary malignancy.

**Key Words:** Carcinoma, Papilla of Vater, Double primary malignancies.

## INTRODUCTION

Adenocarcinoma of the papilla of Vater with coincident malignancy at another site is a rare condition. Here we report five cases of Vaterian carcinoma with another primary malignancy which were observed in a group of ten Vaterian carcinoma cases diagnosed between 1988 and 1993. One of these; simultaneous colonic and Vaterian adenocarcinoma in the absence of familial polyposis coli and/or Gardner's syndrome is only the second case described in the literature (1). Vaterian carcinomas with previous breast and esophagus tumors respectively are described for the first time here.

## CASE REPORTS

**Case 1:** A 62 year old male was admitted with a one month history of jaundice and intermittent fever. His past medical history included squamous cell carcinoma of the esophagus, diagnosed 29 months previously and treated with radiotherapy which relieved his dysphagia. He was operated on seven months later for recurrent dysphagia and found to be inoperable. Six cycles of chemotherapy were administered and relieved the dysphagia. Laboratory evaluation at the time of admission revealed an aspartate aminotransferase (AST) of 60 IU/L (normal 0-34 IU/L), alanine aminotransferase (ALT) of 56 IU/L (normal 0-43 IU/L)- alkaline phosphatase of 335 IU/L (normal 35-125 IU/L), total bilirubin of 3 mg/dl (normal 0.3-1.1 mg/dl) and a prothrombin time (PT) of 16 seconds (normal 12-14 seconds). Abdominal ultrasound demonstrated dilated common and intrahepatic bile ducts and hydropic gallbladder. Endoscopic retrograde cholangiopancreatography (ERCP) demonstrated dilated common and intrahepatic bile ducts (Fig.1) and the papilla of Vater was seen to be hyperemic and irregular. Endoscopic biopsies of the papilla revealed adenocarcinoma (Fig.2) and Whipple procedure was performed. Metastases were detected in three of the peripancreatic lymph nodes. Twenty months after this operation dysphagia recurred and was relieved by Eder-Puestow dilators. At the same time ultrasonic examination showed a hypoechoic nodule 17 mm in diameter in the posterior of the right liver lobe. Ultrasound guided biopsy of this lesion showed metastatic adenocarcinoma. Three days later the patient died of respiratory failure.

**Case 2:** A 72 year old male was admitted with melena and 10 kilograms weight loss over the last three months. Colonoscopy revealed an ulcerated,

polypoid mass, 3 cm in diameter, in the ascending colon and a 3 mm polyp next to it. There was also a 1.2 cm pedunculated polyp which was removed by polypectomy snare and two other diminutive polyps in the sigmoid colon which were removed by hot biopsy forceps. The biopsies of the mass lesion in the ascending colon showed adenocarcinoma and the polyps were tubulovillous adenomas. His family history was negative for colonic polyps and colon carcinoma. At laparotomy for segmental colonic resection another tumor was coincidentally palpated in the second portion of the duodenum. Gastrojejunostomy, cholecystojejunostomy and Braun anastomosis were performed for palliation. Postoperative duodenoscopy confirmed a tumor of the papilla of Vater and the biopsies showed both adenoma and invasive adenocarcinoma. The patient refused further treatment and died at home one year later.

**Case 3:** A 72 year old man was admitted for jaundice which had developed two weeks previously. He had been a heavy smoker for fifty years (40 cigarettes/day). On admission liver function tests were as follows: AST of 77 IU/L, ALT of 109 IU/L, alkaline phosphatase of 466 IU/L, total bilirubin of 8 mg/dl and PT of 18 seconds. Chest radiography showed a mass lesion in the parahilar region of the right lung 5x7 cm in diameter. Bronchoscopic biopsies showed squamous cell carcinoma. During ERCP, the papilla of Vater was seen to be irregular and enlarged. A biopsy of this lesion showed invasive adenocarcinoma. He died of acute pulmonary edema 20 days after the admission.

**Case 4:** A 62 year old female was admitted for anemia of unknown etiology with a hemoglobin of 10 g/dl and fever. Her past medical history included pulmonary tuberculosis and right radical mastectomy for adenocarcinoma 25 years and 2 years ago respectively. Chest radiography showed bilateral apical calcifications and acid fast bacilli grew in bronchoscopic lavage culture. Fever resolved with anti-tuberculosis therapy. Her blood tests revealed AST of 118 IU/L, ALT of 130 IU/L, alkaline phosphatase of 742 IU/L, total bilirubin of 3.2 mg/dl and direct bilirubin of 2.2 mg/dl. Abdominal ultrasound showed dilated common bile duct and minimally dilated intrahepatic ducts with normal appearing pancreas and liver. ERCP was attempted and the papilla was found to be irregular and hemorrhagic. Cannulation was unsuccessful. Endoscopic biopsies showed adenocarcinoma of the papilla. A Whipple procedure was performed. There was no tumor deposit at any other site. She is still well and alive two years after the operation.

**Case 5:** A 83 year old male was admitted for melena, jaundice and five kilograms weight loss over the

previous four months. His blood tests revealed a hemoglobin of 5.9 g/L, alkaline phosphatase of 346 IU/L, ALT of 62 IU/L, total bilirubin of 22.3 mg/dl and direct bilirubin of 21 mg/dl. Abdominal ultrasound and computerized tomography showed cholelithiasis and dilated common and intrahepatic bile ducts. Gastroscopy revealed a mass lesion at the cardia of the stomach and biopsy showed adenocarcinoma. ERCP was performed for obstructive jaundice and a tumor of the papilla of Vater diagnosed. A biopsy of this lesion also showed adenocarcinoma. During laparotomy peritoneal carcinomatosis was found and partial gastrectomy, choledochojejunostomy and Braun anastomosis were performed for palliation. He was discharged and died at home two months later.

## DISCUSSION

Carcinoma of the papilla of Vater is a rare entity. The incidence of this tumor has been reported to be 0.8% of all malignancies (2). Detection of another tumor at another site either synchronously or asynchronously is even more rare. Between 1988 and 1993 at Marmara University Hospital we diagnosed ten cases of adenocarcinoma of the papilla of Vater. Five of these cases had another primary tumors either synchronously or in the past. This figure is remarkably higher than in the other two reported series (Table I). In addition to the series shown in table I there are several other reports of coincident neoplasms with Vaterian carcinoma such as gastric lymphoma and carcinoma of the stomach (4-6).

Case 1 and case 4 are the first reported cases of carcinoma of the papilla of Vater with coincident tumors of esophagus and breast respectively. Although the lung cancer coincident with the carcinoma of the papilla of Vater has been reported previously by Schlippert, case 3 is the first case reported with simultaneous presentation of these malignancies (2).

As for colonic adenomas, adenomas of the papilla of Vater are regarded as premalignant (7,8). The simultaneous existence of adenoma and adenocarcinoma in biopsy specimens of case 2 supports this hypothesis. Periampullary carcinoma has been reported in patients with familial polyposis coli and Gardner's syndrome (9-12). In the literature there is only one case report of carcinoma of the ampulla of Vater synchronous with colonic carcinoma in the absence of familial polyposis coli or Gardner's syndrome (1). In case 2 one colonic adenoma, two diminutive polyps with unknown histology and adenocarcinoma in the papilla of Vater is concurrently present. The patient did not show any evidence of familial polyposis coli and did not have a family history compatible with this syndrome or Lynch



syndrome II (hereditary colonic carcinoma) which is associated with an increased risk of extracolonic adenocarcinoma (13).

Except for the first case with previous esophageal carcinoma, neither chemotherapy nor radiotherapy was used prior to the diagnosis of carcinoma of the papilla of Vater. Since the time period for solid tumor induction by radiotherapy and chemotherapy is much

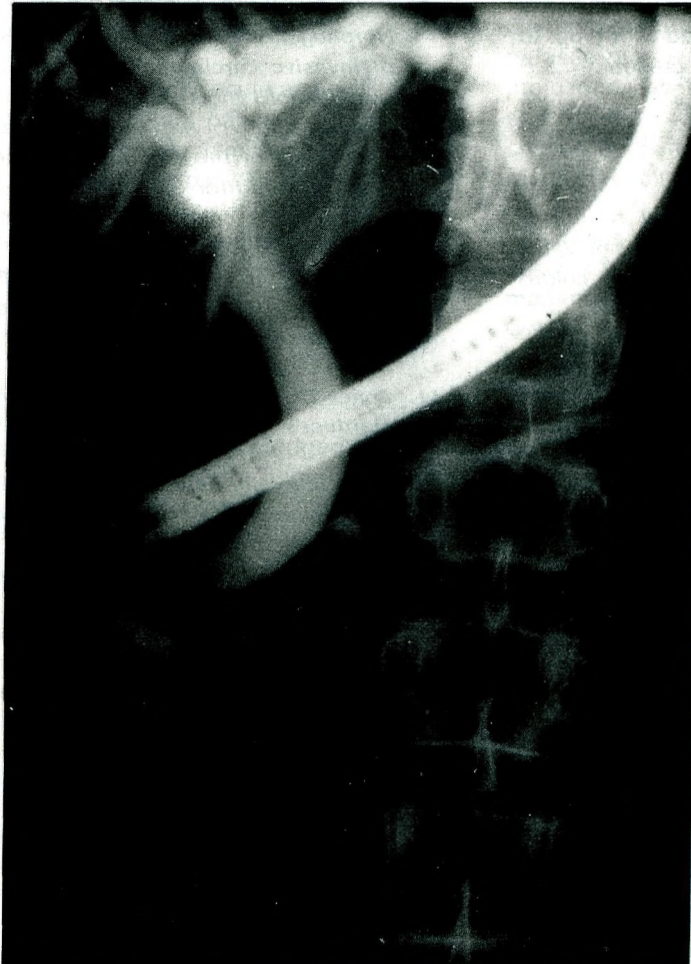longer than a few years it is unlikely that the cancer of the papilla of Vater was caused by previous radiotherapy and/or chemotherapy which were carried out 29 and 23 months before diagnosis (14,15).

Moertel, et al reported the expected incidence of secondary tumor to be 2.8% in the general population. This is less than the frequency of the

**Table I.** Literature Review of Coincident Neoplasms Together With Vaterian Carcinoma

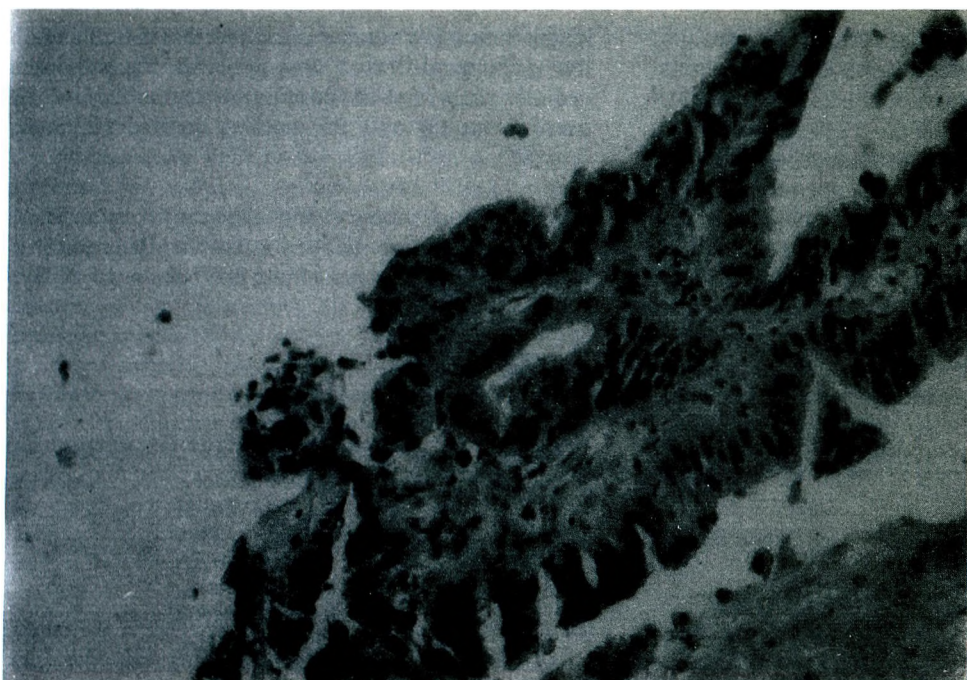
	*P.C.N./**T.P.P	%	Type of Coincident Neoplasm
Schlippert (2)	7/57	12.5	Bronchus, Endometrium, Right pyriform sinus, Rectum, Lip, Larynx, Uterus
Yamaguchi (3)	7/109	6	Stomach (3 cases), Duodenal adenoma, Islet cell adenoma, Carcinoid tumor
Present series	5/10	50	Esophagus, Colon, Lung, Breast, Stomach

\* Number of patients with coincident neoplasms  
\*\* Total number of patients with tumor of the papilla of Vater



**Fig. 1:**

Endoscopic retrograde cholangiopancreatographic view of case 1 shows dilated common bile duct and intrahepatic bile ducts.

**Fig. 2:**

Microscopic appearance of endoscopic biopsy of Papilla Vateri shows adenocarcinoma.

coincident neoplasms in patients with Vaterian carcinoma in this and previous series (16). Based upon our experience, we suggest that any patient who present with an adenocarcinoma primary in the papilla of Vater deserves a detailed work up to ensure that no other malignancies are present.

## REFERENCES

1. Yoshida J, Morisaki T, Yamaguchi K, et al. Carcinoma in adenoma of the ampulla of Vater synchronous with cancer of the sigmoid colon. *Dig Dis Sci* 1990;35:271-275.
2. Schlippert W, Luche D, Anuras S, et al. Carcinoma of the papilla of Vater. A review of fifty-seven cases. *Am J Surg* 1978;135:763-770.
3. Yamaguchi K, Enjoji M. Carcinoma of the ampulla of Vater. A clinicopathologic staging of 109 cases of carcinoma and 5 cases of adenoma. *Cancer* 1987;59:506-515.
4. Cattell RB, Warren KW, Francis TC. Periampullary carcinomas. *Diagnosis and surgical management. Surg Clin North Am* 1959;39:781-788.
5. Monge JJ, Judd ES, Gage RP. Radical pancreatoduodenectomy: A 22 year experience with the complications, mortality rate and survival rate. *Ann Surg* 1964;160:711-722.
6. Kitano S, Morotomi I, Oiawa T, et al. Simultaneous early carcinomas of the ampulla of Vater and the stomach. Report of a case involving chronic active hepatitis. *S Afr Med J* 1984;66:656-658.
7. Kozuka S, Tsubone M, Yamaguchi A, et al. Adenomatous residue in cancerous papilla of Vater. *Gut* 1981;22:1031-1034.
8. Baczako K, Buchler M, Beger HG, et al. Morphogenesis and possible precursor of lesions of invasive carcinoma of the papilla of Vater. *Hum Pathol* 1985;16:305-310.
9. Capps WF Jr, Lewis MI, Gazzangia DA. Carcinoma of the colon, ampulla of Vater and urinary bladder associated with familial polyposis: A case report. *Dis Colon Rectum* 1968;11:298-305.
10. Parks TG, Bussey HJ, Lochart-Mumery HE. Familial polyposis coli associated with extracolonic abnormalities. *Gut* 1970;11:323-329.
11. Jones TR, Nance FC. Periampullary malignancy in Gardner's syndrome. *Ann Surg* 1977;185:565-573.
12. Mark EJ, McNeely BU. Case records of the Massachusetts General Hospital. Case 50-1982. *N Eng J Med* 1982;307:1566-1573.
13. Fitzgibbons RJ, Lynch HT, Stanislav GV, et al. Recognition and treatment of patient with hereditary non polyposis colon cancer (Lynch syndromes I-II). *Ann Surg* 1987;206:289-295.
14. Tucker MA, Coleman CN. Secondary Cancers. In: De Vita VT, Helmann Jr S, Rosenberg SA, eds. *Cancer Principles and Practice of Oncology*. Philadelphia: JB Lippincott, 1989:2181-2190.
15. Tucker MA, Coleman CN, Cox RS, et al. Risk of second cancer after treatment for Hodgkin's disease. *N Engl J Med* 1988;318:76-81.
16. Moertel GC, Malcolm B. Multiple primary malignant neoplasms: Introduction and presentation of data. *Cancer* 1961;14:221-230.