

COMPARISON OF CONE-BEAM COMPUTED TOMOGRAPHY AND PANORAMIC RADIOGRAPHS IN DETECTING MAXILLARY SINUS SEPTA

Maksiller Sinüs Septasının Belirlenmesinde Konik Işınlı Bilgisayarlı Tomografi ve Panoramik Radyografinin Karşılaştırılması

Meryem TORAMAN-ALKURT¹, İlkay PEKER¹, Şerife DEĞERLİ¹, Ali Rıza İlker CEBECİ², Elif SADIK³

Received: 08/01/2016

Accepted: 19/04/2016

ABSTRACT

Purpose: The purpose of this retrospective study was to compare the performance of cone-beam computed tomography (CBCT) and panoramic radiography in detecting the presence and location of maxillary sinus septa.

Materials and methods: This study included radiographic examination of 104 maxillary sinuses of 52 individuals (26 females, 50% and 26 males, 50%) whose panoramic radiographs and CBCT images were obtained for several dental causes which were examined by the consensus of four dentomaxillofacial radiologists. The posterior maxillary segments in proximity of maxillary sinus were classified as edentulous and dentate maxillary segments. The location of maxillary sinus septa was classified as primary septa and secondary septa according to the presence of maxillary tooth at the affected site. The maxillary sinus septa were divided into three categories (anterior, middle and posterior) according to its relation with posterior maxillary teeth. Data were statistically analyzed with chi-square and Fisher's exact tests.

Results: The septa were found in 23.1% and 29.8% of the maxillary sinuses on panoramic radiography and CBCT images, respectively. The majority of maxillary sinus septa were observed in dentate posterior maxillary segments on both panoramic (45.8%) radiography and CBCT (64.5%) images. Statistically significant differences ($p < 0.001$) were found between panoramic radiography and CBCT images for presence, location and neighborhood with the posterior maxillary teeth of maxillary sinus septa.

Conclusion: The results of this study demonstrated the low reliability of panoramic radiography images in the detection of maxillary sinus septa. CBCT images can provide valuable information to the clinicians about the presence and location of maxillary sinus septa.

Keywords: Maxillary sinus septa; panoramic radiography; cone-beam computed tomography

ÖZ

Amaç: Bu retrospektif çalışmanın amacı, maksiller sinüs septasının varlığını ve konumunu belirlemede konik-ışınli bilgisayarlı tomografi (KIBT) ve panoramik radyografi yöntemlerinin karşılaştırılmasıdır.

Gereç ve yöntem: Bu çalışmada 52 kişiden çeşitli dental nedenlerle elde edilmiş panoramik radyografi ve KIBT görüntüsündeki 104 maksiller sinüs, dört ağız, diş ve çene radyolojisi uzmanının fikir birliği ile incelendi. Maksiller sinüsle yakın komşuluktaki posterior maksiller bölge, dişsiz ve dişli olarak sınıflandırıldı. Maksiller sinüs septasının yeri, ilgili bölgedeki maksiller diş varlığına göre, primer ve sekonder septa şeklinde sınıflandırıldı. Maksiller sinüs septası, posterior maksiller dişlerle olan komşuluğuna göre ön, orta ve arka olarak üç kategoriye ayrıldı. Veriler ki-kare ve Fisher'in kesin testi ile istatistiksel olarak analiz edildi.

Bulgular: Panoramik radyografi ve KIBT görüntülerindeki maksiller sinüslerin sırasıyla, %23.1 ve %29.8'inde septa bulundu. Hem panoramik radyografi (%45.8) hem de KIBT görüntülerindeki (%64.5) maksiller sinüs septası çoğunlukla, dişli posterior maksiller bölgelerde izlendi. Maksiller sinüs septasının varlığı, lokalizasyonu ve posterior maksiller dişlerle olan komşuluğu için panoramik radyografi ve KIBT görüntüleri arasında istatistiksel olarak anlamlı fark ($p < 0.001$) bulundu.

Sonuç: Çalışmanın sonuçları, maksiller sinüs septasının belirlenmesinde panoramik radyografi görüntülerinin güvenilirliğinin düşük olduğunu gösterdi. KIBT görüntüleri ise maksiller sinüs septasının varlığı ve konumu hakkında klinisyenlere yararlı bilgi verebilir.

Anahtar kelimeler: Maksiller sinüs septa; panoramik radyografi; konik-ışınli bilgisayarlı tomografi

¹ Department of Dentomaxillofacial Radiology Faculty of Dentistry Gazi University

² Private Practice

³ Department of Dentomaxillofacial Radiology Faculty of Dentistry Ordu University



Introduction

The maxillary sinuses, which occupy the body of the maxilla generally as large pyramidal cavities, have variable morphologies and sizes. They are the largest of the paranasal sinuses. (1, 2) Maxillary sinus is in close proximity to the orbit, alveolar ridge and maxillary posterior teeth, thus, this anatomical region may sustain injuries during dental procedures. The maxillary sinus elevation technique is one of the most commonly used strategies for dental implant rehabilitation in atrophic posterior maxilla (3-5). Since the maxillary alveolar process forms the maxillary sinus floor, assessment of possible alterations in maxillary sinuses is essential especially in the preoperative implant planning in the maxillary posterior region (6). In the images of the maxillary sinuses, one or multiple transvers radiopaque lines, which are named 'septa' can be observed. They were originally described in 1910 by Underwood (7). They can divide maxillary sinus into two or more cavities. As Zijdeveld *et al.* (5) and Boyne and James (3) stated the presence, location, shape, number and size of septa in the maxillary sinus, especially the inferior wall, increase the risk of sinus membrane perforation during sinus floor elevation procedures (8-12). There are several hypotheses suggested by different authors concerning the presence of antral septa (10, 13-16). Krennmair *et al.* (14) have classified the septa into primary and secondary septa. Primary septa is thought to arise during maxillary development whereas secondary septa arises from the irregular pneumatization of the sinus floor following tooth loss. In previous studies the septae were accepted as the wall of the cortical bone at least 2.5 mm in height within the maxillary sinus (9, 13, 17).

Accurate radiographic identification of these structures is necessary to obtain detailed information regarding maxillary sinus anatomy during maxillofacial surgery. Dental panoramic radiography, computed tomography (CT) and cone-beam computed tomography (CBCT) have been used to identify the maxillary sinus septa (9, 10, 18). CBCT is recommended as an excellent, low cost technique for the evaluation of maxillary sinus septa with only slightly more ionizing radiation dose than panoramic radiography and far less than CT (19-23). Although various studies compared panoramic radiography and CT for detection of maxillary sinus septa, no study was conducted regarding the comparison of panoramic radiography and CBCT (6, 22, 24).

The purpose of this retrospective study was to compare the performance of CBCT and panoramic radiography in determining the presence and location of maxillary sinus septa.

Materials and Methods

Sample characteristics and imaging protocols

This study included panoramic radiographs and CBCT scans of 104 maxillary sinuses in 52 individuals (26 females, 26 males), obtained for several dental causes which were available in the database of a private imaging center. Before any radiographic images were obtained, the patients were asked to sign informed consents for radiography and clinical examinations according to the principles of the Helsinki Declaration. Only researchers had access the acquired data. Panoramic images used in the study had been obtained using Planmeca Proline XC (Planmeca, Helsinki, Finland) unit, a charge coupling device (CCD) based digital panoramic unit operating at 60-80 kVp and 4-12 mA, with a 0.5 mm focal spot and an exposure time of 16 seconds. CBCT images were acquired with Iluma Ultra Cone-beam CT Scanner (3M Imtec, Ardmore, OK, USA) with a 24.4×19.5 cm amorphous silicon flat-panel image detector and a cylindrical volume of reconstruction up to 21.2×14.2 cm. CBCT images were obtained at 120 kVp, 1-3.8 mA with 0.2 mm voxel size, an exposure time of 7.8 seconds and a field of view of 8 cm.

Study variables

The posterior maxillary segments in proximity of maxillary sinus were classified as edentulous (partial, complete and atrophic edentulous) and dentate maxillary segments (14). The location of maxillary sinus septa was classified as primary septa if it was located from a maxillary tooth root; and secondary septa located superior to an edentulous ridge (3, 10, 14, 22). The maxillary sinus septa according to neighborhood with the posterior maxillary teeth was divided into three categories: anterior region, between the mesial and distal aspects of the second premolar root; middle between distal aspects of second premolar and second molar; and posterior, distal aspect of the root of the second molar (6, 9, 17). In this study, septa of at least 2.5 mm in height were evaluated in accordance with previous studies (9, 13, 17).

Radiographic examination protocol

The examinations were carried out by the agreement of four dentomaxillofacial radiologists (M.A, I.P, I.C and E.S) with at least five years of experience on panoramic images and axial, coronal and sagittal sections for CBCT examinations, on the computer monitor (21 inch LCD monitor with 1280 × 1024 resolution) in a quiet room with subdued ambient lighting. Totally 11 sessions were arranged in a period of two weeks and 10 maxillary sinuses were evaluated in each session, eventually the examinations were

completed in 22 weeks. The examples of maxillary sinus septa were presented in Figure 1 and 2.

Statistical analysis.

Data were statistically analyzed by using SPSS-15.0 version (SPSS Inc, Chicago, IL, USA) for Windows with descriptive statistics, chi-square and Fisher's exact tests. Confidence interval was set to 95% and p-values less than 0.05 were considered statistically significant.

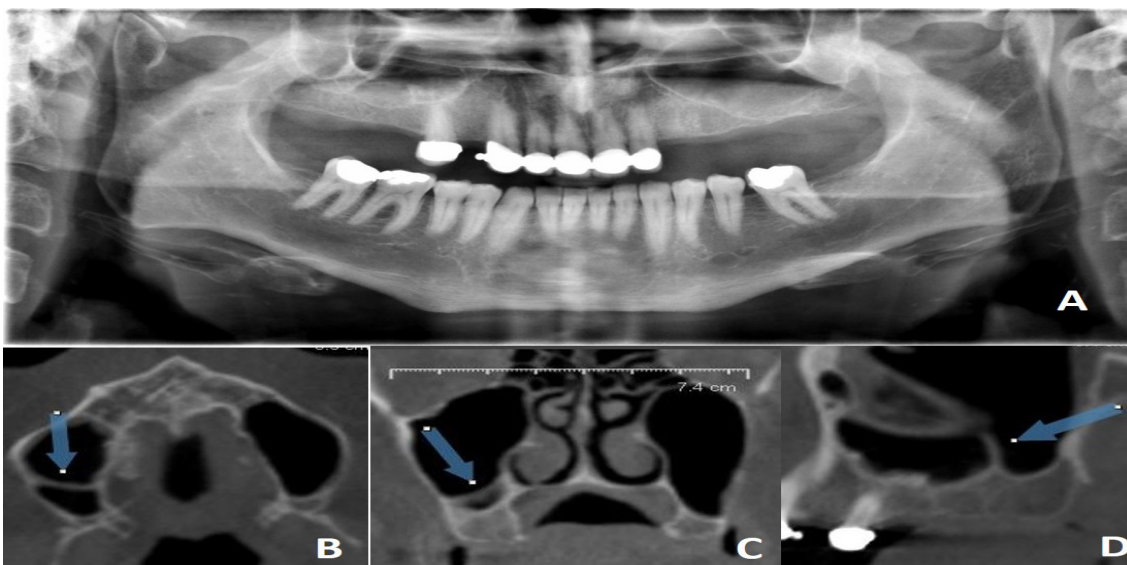


Figure 1. An example of maxillary sinus septa on panoramic (A) and CBCT (B,C and D) images.

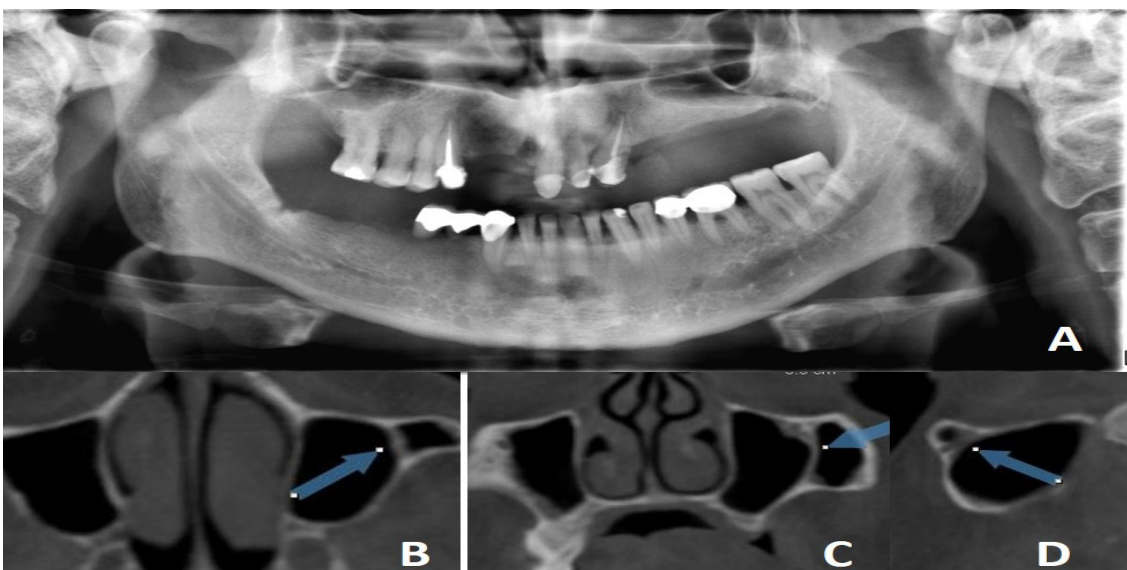


Figure 2. An example of maxillary sinus septa on panoramic (A) and CBCT (B,C and D) images.

Results

In total, 104 maxillary sinuses of 52 individuals between 16 and 75 years of age (mean±standard deviation (SD): 46.8±15.9 years) were examined in this study. There were two age groups; 26 subjects' ages were under 50. Regarding the posterior maxillary segments in proximity of maxillary sinus; the most common posterior maxillary segments were partial edentulous (n=22, 42%), followed by dentate (n=15, 29%), atrophic edentulous (n=11, 21%) and complete edentulous jaws (n=4, 8%) in the right quadrants, respectively. In the left quadrants, dentate posterior maxillary segments (n=20, 38%) were mostly observed, followed by partial edentulous (n=15, 29%), atrophic edentulous (n=12, 23%) and complete edentulous jaws (n=5, 10%). The prevalence of

maxillary sinus septa was found to be 23.1% (n=24) and 29.8% (n=31) on panoramic and on CBCT images, respectively. 24 maxillary sinus septa were observed in 21 patients on panoramic images and 31 maxillary sinus septa were observed in 20 patients on CBCT images whose mean age±SD was 39.05±16.6 years. Most of the septa was observed in subjects under age 50. Thus, bilateral maxillary sinus septa was determined in 3 (5.8%) patients on panoramic images and in 8 (15.4%) patients on CBCT images and also double unilateral septa was observed in 3 (5.8%) patients on CBCT images. The majority of maxillary sinus septa was observed in dentate posterior maxillary segments which was followed by partial edentulous, atrophic edentulous and complete edentulous jaws on both panoramic and CBCT images (Table 1).

Table 1. The distribution of maxillary sinus septa according to the adjacent posterior maxillary segments.

Posterior maxillary segments	Presence of maxillary sinus septa	
	Panoramic images n (%)	CBCT images n (%)
Partial edentulous	8 (33.4)	6 (19.4)
Complete edentulous	2 (8.3)	2 (6.4)
Atrophic edentulous	3 (12.5)	3 (9.7)
Dentate	11 (45.8)	20 (64.5)
Total	34 (100)	31 (100)

Regarding the location of maxillary sinus septa; the frequencies of primary septa was 58.3% (n=14) and 58.1% (n=18) on panoramic and CBCT images, respectively. The frequencies of secondary septa were found to be 41.7% (n=10) and 41.9% (n=13) on panoramic and CBCT images, respectively. Statistically significant difference ($p<0.001$) was observed between panoramic radiography and CBCT scans for the location of maxillary sinus septa (Table 2). Regarding presence of the maxillary

sinus septa and its neighborhood with the posterior maxillary teeth; the majority of maxillary sinus septa were observed at the anterior region on panoramic images (Table 3). However, the maxillary sinus septa was mostly observed at the middle region on CBCT images. Statistically significant differences ($p<0.001$) were found between panoramic radiography and CBCT scans for the presence and neighborhood with the posterior maxillary teeth of the maxillary sinus septa (Table 3).

Table 2. The results of statistical analysis for the location of maxillary sinus septa.

Location of maxillary sinus septa	Panoramic images n (%)	CBCT images n (%)	p value
Primary	14 (58)	18 (58)	$p<0.001^*$
Secondary	10 (42)	13 (42)	
Total	24 (100)	31 (100)	

*Fisher's Exact Test

Table 3. The distribution and statistical analysis for the presence and neighborhood with the posterior maxillary teeth of the maxillary sinus septa.

Presence and neighborhood with the posterior maxillary teeth of septa			Panoramic radiography findings				p value	
			Absent	Anterior region	Middle region	Posterior region		Total
CBCT findings	Anterior region	n %	1 3.25%	1 3.25%	0 0%	0 0%	2 6.5%	$p < 0.001^*$
	Middle region	n %	8 25.85%	9 29%	6 19.35%	0 0%	23 74.2%	
	Posterior region	n %	5 16.1%	0 0%	0 0%	1 3.25%	6 19.35%	
	Total	n %	14 45.2%	10 32.25	6 19.35%	1 3.25%	31 %100	

*Fisher's Exact Test

Discussion

Accurate diagnosis of maxillary sinus septa is possible with radiographic identification. Panoramic radiography, CT and CBCT have been used to identify the maxillary sinus septa. However, exact and definitive assessment can be achieved by CT and CBCT scans. CBCT is recommended as an excellent, low cost technique for the evaluation of maxillary sinus septa with only slightly more radiation dose than panoramic radiography and far less than CT (22, 25). Although various studies compared panoramic radiography with CT for the detection of maxillary sinus septa, according to our knowledge, no study was conducted regarding the comparison of panoramic radiography and CBCT (6, 25, 26).

Different observation methods have been used by several authors. Underwood (7) examined 45 dried skulls, Ulm *et al.* (17) observed maxillary sinuses during sinus lift procedures, Lugmayr *et al.* (15) observed sinus septa on CT images. Krennmair *et al.* (14) assessed prevalence of septa on CT images and 24.5% of the sinuses were also observed during sinus lifting. Kasabah *et al.* (13) compared panoramic radiography by CT images. Velasquez-Plata *et al.* (27) and Kim *et al.* (9) used software analyses for septa detection. Several studies detected septa using panoramic images (25-28). Our study represents the first performance for comparison of the CBCT and panoramic radiography findings in detecting the presence, number and location of maxillary sinus septa. We examined 104 maxillary sinuses of 52 individuals on both digital panoramic and CBCT images. The prevalence of maxillary sinus septa has been reported as 20.6% and 58% by CBCT in previous studies performed in different countries (29-34). However, it was reported that the prevalence of maxillary sinus septa ranged between 14.3% and 33.3 % in a systematic review

in French population (30). Jang *et al.* (31) examined 151 patients and reported its prevalence of 26% in Korean population. Li *et al.* (32) analyzed 424 patients in Han population and observed the maxillary sinus septa in 44.8% of the patients. Dobeles *et al.* (33) determined the maxillary sinus septa in 20.6% of the Latvian patients. Lana *et al.* (34) reported the prevalence of maxillary sinus septa as 44.4% in Brazilian patients. The prevalence of maxillary sinus septa has been reported as 58% in Turkish patients by Orhan *et al.* (23). In the current study, prevalence of maxillary sinus septa was found to be 23.1% and 29.8% on panoramic and on CBCT images. Although, this result was lower than the previous study performed in Turkish population, it was in accordance with some previous reports. Orhan *et al.* (23) reported that unilateral septa has been determined in majority of cases with mixed dentition (3.2%) and bilateral septa has been determined in majority of cases with dentition (23%). Unilateral and bilateral two septa were found in 1.08% and 0.2% of the cases, respectively. Also, unilateral and bilateral three septa were found in 0.4% of the cases by the same authors. In the present study, the frequency of unilateral maxillary sinus septa was higher (40.4%) than bilateral septa (5.8%) and also unilateral double septa was observed in 5.8% of the patients on CBCT images. This result is different from Orhan *et al.*'s (23) results. Some authors (23, 35) observed higher prevalence of septa in partially edentulous maxilla than in totally edentulous ones and reported no statistically significant differences between the different types of edentulism. However, other authors (9, 14, 36, 37) reported a higher prevalence of septa in completely edentulous patients than in partially edentulous patients. In the present study, the majority of maxillary sinus septa was observed in dentate posterior maxillary segments which was followed by partial edentulous, atrophic edentulous and complete edentulous jaws on both panoramic and CBCT images,

which is different from previous studies. Location of the maxillary sinus septa was determined by different authors. Underwood (7) reported most of the septa has been found in the posterior region over third molar roots; Ulm *et al.* (17) reported a greater frequency of septa in the anterior region, as did Krennmair *et al.* (14) (70% of septa in the premolar region); and Velásquez-Plata *et al.* (27), Kim *et al.* (9), González-Santana *et al.* (25), Orhan *et al.* (23) found the highest frequency in the middle region, as 41%, 50.8%, 65% and 69.1%, respectively. However, Jang *et al.* (30) reported the highest frequency they have observed was in the middle and anterior regions for edentulous and dentate patients, respectively. In the present study, the highest prevalence was found in the anterior region as 32.2% on panoramic images and 74.2% were observed in the middle region on CBCT images which is in accordance with previous reports. Krennmair *et al.* (14) reported the rate of false diagnosis on panoramic radiographs as 21.3% while Kasabah *et al.* (13) reported as 44.1% and Gonzalez-Santana *et al.* (25) as 11.8%. We also found statistically significant differences between panoramic radiography and CBCT scans for the detection of septa presence, location and distribution of primary/secondary septa in accordance with previous studies.

Conclusion

The results of this study demonstrated that there are significant differences between panoramic radiographs and CBCT images in the detection of presence, number and location of maxillary sinus septa. CBCT is a useful imaging method to determine of maxillary sinus septa as it provides cross-sectional images.

Source of funding

None declared

Conflict of interest

None declared

References

1. Mc Growan DA BP, James J. The maxillary sinus and its dental implications. London: Wright Co, 1993, 1-25.
2. Williams PL BL, Berry MM, Collins P, Dyson M, Dussek JE, Ferguson MWJ. Gray's anatomy. Edinburgh: Churchill Livingstone, 1995, 1637.
3. Boyne PJ, James RA. Grafting of the maxillary sinus floor with autogenous marrow and bone. *J Oral Surg* 1980;38(8):613-616.
4. Koymen R, Gocmen-Mas N, Karacayli U, Ortakoglu K, Ozen T, Yazici AC. Anatomic evaluation of maxillary sinus septa: Surgery and radiology. *Clin Anat* 2009;22(5):563-570.
5. Zijderveld SA, van den Bergh JP, Schulten EA, ten Bruggenkate CM. Anatomical and surgical findings and complications in 100 consecutive maxillary sinus floor elevation procedures. *J Oral Maxillofac Surg* 2008;66(7):1426-1438.
6. Maestre-Ferrin L, Galan-Gil S, Rubio-Serrano M, Penarrocha-Diago M, Penarrocha-Oltra D. Maxillary sinus septa: A systematic review. *Med Oral Patol Oral Cir Bucal* 2010;15(2):e383-386.
7. Underwood AS. An inquiry into the anatomy and pathology of the maxillary sinus. *J Anat Physiol* 1910;44(Pt 4):354-369.
8. Betts NJ, Miloro M. Modification of the sinus lift procedure for septa in the maxillary antrum. *J Oral Maxillofac Surg* 1994;52(3):332-333.
9. Kim MJ, Jung UW, Kim CS, Kim KD, Choi SH, Kim CK, Cho KS. Maxillary sinus septa: Prevalence, height, location, and morphology. A reformatted computed tomography scan analysis. *J Periodontol* 2006;77(5):903-908.
10. Krennmair G, Ulm C, Lugmayr H. Maxillary sinus septa: Incidence, morphology and clinical implications. *J Craniomaxillofac Surg* 1997;25(5):261-265.
11. Tatum H, Jr. Maxillary and sinus implant reconstructions. *Dent Clin North Am* 1986;30(2):207-229.
12. van den Bergh JP, ten Bruggenkate CM, Disch FJ, Tuinzing DB. Anatomical aspects of sinus floor elevations. *Clin Oral Implants Res* 2000;11(3):256-265.
13. Kasabah S, Slezak R, Simunek A, Krug J, Lecaro MC. Evaluation of the accuracy of panoramic radiograph in the definition of maxillary sinus septa. *Acta Medica (Hradec Kralove)* 2002;45(4):173-175.
14. Krennmair G, Ulm CW, Lugmayr H, Solar P. The incidence, location, and height of maxillary sinus septa in the edentulous and dentate maxilla. *J Oral Maxillofac Surg* 1999;57(6):667-671.
15. Lugmayr H, Krennmair G, Holzer H. [The morphology and incidence of maxillary sinus septa]. *Rofo* 1996;165(5):452-454.
16. Naitoh M, Suenaga Y, Kondo S, Gotoh K, Arijji E. Assessment of maxillary sinus septa using cone-beam computed tomography: Etiological consideration. *Clin Implant Dent Relat Res* 2009;11 Suppl 1:e52-58.
17. Ulm CW, Solar P, Krennmair G, Matejka M, Watzek

- G. Incidence and suggested surgical management of septa in sinus-lift procedures. *Int J Oral Maxillofac Implants* 1995;10(4):462-465.
18. Almog DM, Romano PR. Ct-based dental imaging for implant planning and surgical guidance. *N Y State Dent J* 2007;73(1):51-53.
 19. Liang X, Jacobs R, Hassan B, Li L, Pauwels R, Corpas L, Souza PC, Martens W, Shahbazian M, Alonso A, Lambrechts I. A comparative evaluation of cone beam computed tomography (cbct) and multi-slice ct (msct) part 1. On subjective image quality. *Eur J Radiol* 2010;75(2):265-269.
 20. Loubele M, Bogaerts R, Van Dijck E, Pauwels R, Vanheusden S, Suetens P, Marchal G, Sanderink G, Jacobs R. Comparison between effective radiation dose of cbct and msct scanners for dentomaxillofacial applications. *Eur J Radiol* 2009;71(3):461-468.
 21. Ludlow JB, Davies-Ludlow LE, Brooks SL, Howerton WB. Dosimetry of 3 cbct devices for oral and maxillofacial radiology: Cb mercuray, newtom 3g and i-cat. *Dentomaxillofac Radiol* 2006;35(4):219-226.
 22. Ludlow JB, Ivanovic M. Comparative dosimetry of dental CBCT devices and 64-slice CT for oral and maxillofacial radiology. *Oral Surg Oral Med Oral Pathol Oral Radiol Endod* 2008;106(1):106-114.
 23. Orhan K, Kusakci Seker B, Aksoy S, Bayindir H, Berberoglu A, Seker E. Cone beam CT evaluation of maxillary sinus septa prevalence, height, location and morphology in children and an adult population. *Med Princ Pract* 2013;22(1):47-53.
 24. Tsiklakis K, Donta C, Gavala S, Karayianni K, Kamenopoulou V, Hourdakakis CJ. Dose reduction in maxillofacial imaging using low dose cone beam ct. *Eur J Radiol* 2005;56(3):413-417.
 25. Gonzalez-Santana H, Penarrocha-Diago M, Guarinos-Carbo J, Sorni-Broker M. A study of the septa in the maxillary sinuses and the subantral alveolar processes in 30 patients. *J Oral Implantol* 2007;33(6):340-343.
 26. Malec M ST, Tutak M, Trybek G, Sporniak-Tutak, K. Maxillary sinus septa prevalence and morphology-computed tomography based analysis. *Int J Morphol* 2015;33(1):144-148.
 27. Velasquez-Plata D, Hovey LR, Peach CC, Alder ME. Maxillary sinus septa: A 3-dimensional computerized tomographic scan analysis. *Int J Oral Maxillofac Implants* 2002;17(6):854-860.
 28. Shibli JA, Faveri M, Ferrari DS, Melo L, Garcia RV, d'Avila S, Figueiredo LC, Feres M. Prevalence of maxillary sinus septa in 1024 subjects with edentulous upper jaws: A retrospective study. *J Oral Implantol* 2007;33(5):293-296.
 29. Dobeles I, Kise L, Apse P, Kragis G, Bigestans A. Radiographic assessment of findings in the maxillary sinus using cone-beam computed tomography. *Stomatologija* 2013;15(4):119-122.
 30. Jang SY, Chung K, Jung S, Park HJ, Oh HK, Kook MS. Comparative study of the sinus septa between dentulous and edentulous patients by cone beam computed tomography. *Implant Dent* 2014;23(4):477-481.
 31. Lana JP, Carneiro PM, Machado Vde C, de Souza PE, Manzi FR, Horta MC. Anatomic variations and lesions of the maxillary sinus detected in cone beam computed tomography for dental implants. *Clin Oral Implants Res* 2012;23(12):1398-1403.
 32. Li J, Zhou ZX, Yuan ZY, Yuan H, Sun C, Chen N. [An anatomical study of maxillary sinus septum of han population in Jiangsu region using cone-beam CT]. *Shanghai Kou Qiang Yi Xue* 2013;22(1):52-57.
 33. Rosano G, Gaudy JF, Chaumanet G, Del Fabbro M, Taschieri S. [Maxillary sinus septa. Prevalence and anatomy]. *Rev Stomatol Chir Maxillofac* 2012;113(1):32-35.
 34. Vogiatzi T, Kloukos D, Scarfe WC, Bornstein MM. Incidence of anatomical variations and disease of the maxillary sinuses as identified by cone beam computed tomography: A systematic review. *Int J Oral Maxillofac Implants* 2014;29(6):1301-1314.
 35. Maestre-Ferrin L, Carrillo-Garcia C, Galan-Gil S, Penarrocha-Diago M, Penarrocha-Diago M. Prevalence, location, and size of maxillary sinus septa: Panoramic radiograph versus computed tomography scan. *J Oral Maxillofac Surg* 2011;69(2):507-511.
 36. Lee WJ, Lee SJ, Kim HS. Analysis of location and prevalence of maxillary sinus septa. *J Periodontal Implant Sci* 2010;40(2):56-60.
 37. Park YB, Jeon HS, Shim JS, Lee KW, Moon HS. Analysis of the anatomy of the maxillary sinus septum using 3-dimensional computed tomography. *J Oral Maxillofac Surg* 2011;69(4):1070-1078.

Corresponding Author:**Meryem TORAMAN ALKURT**

Department of Dentomaxillofacial Radiology

Faculty of Dentistry Gazi University

06510 Emek-Ankara, Turkey

Phone: +90 312 203 41 52

e-mail: mtalkurt@gmail.com