

MANDIBULAR INCISOR EXTRACTION: A 5-YEAR FOLLOW-UP

Mandibuler Keser Dişı Çekimi: 5 Senelik Takip

Kadir BEYCAN, Ahu ACAR

Received: 10/03/2016

Accepted: 26/04/2016

ABSTRACT

This case report presents the mandibular incisor extraction treatment of a patient with dental Class I malocclusion and lower crowding, in whom one mandibular incisor extraction was selected as the treatment of choice to improve the dental occlusion. A 19-year-old male patient's chief complaint was the crowding of lower incisors. He had a straight profile with normal upper and lower lip projection. Upper and lower dental midlines were coincident with the facial midline. The patient had Class I molar and canine relationships on both sides. He had Class I skeletal relationship, low angle vertical pattern, and proclined upper and lower incisors. The treatment plan included the extraction of lower right central incisor to resolve the crowding. At the end of 16-month active fixed treatment, lower dental crowding was resolved. At the 5-year follow-up, the patient had a stable occlusion, with the results of the orthodontic treatment maintained.

Keywords: Mandibular incisor; crowding, extraction; occlusion; long term follow-up

ÖZ

Bu vaka raporunda dişsel Sınıf I maloklüzyonu ve alt diş kavsinde çapraşıklık olan bir hastada, dental oklüzyonun mandibuler keser dişı çekimi yapılarak tedavi edilme süreci anlatılmaktadır. Alt keser dişlerinin çapraşıklıktan şikayetçi olan 19 yaşındaki erkek hasta normal üst ve alt dudak projeksiyonu ile birlikte düz bir profile sahipti. Üst ve alt dişsel orta hatlar yüz orta hattı üzerinde konumlanmıştı. Ağız içi muayenesinde sağ ve sol tarafta dişsel Sınıf I kanin ve molar ilişkisi olduğu tespit edildi. Hastada isketsel Sınıf I ilişki, azalmış dikey boyut, prokline alt ve üst dişlerin olduğunu belirledi. Tedavi planı alt sağ lateral keser dişı çekimi olarak belirlenmiştir. 16 aylık aktif tedavi sonunda çapraşıklık giderildi. Beş senelik takip sonrasında oklüzyonun stabil kaldığı, ortodontik tedavi ile elde edilen sonuçların korunduğu gözlemlenmiştir.

Anahtar kelimeler: Alt çene kesici dişler; çapraşıklık; dişı çekimi; uzun dönem takip



Introduction

The extraction of one mandibular incisor is not very common in orthodontics, although it has obvious benefits in the area of crowding (1, 2). The possible indications for incisor extraction could be abnormalities in the number of anterior teeth; discrepancies in tooth size, ectopic eruption of incisors and moderate Class III malocclusions (3, 4). Undesirable side-effects have been reported as the possible increase of the overbite and overjet beyond acceptable limits, re-opening of the space, partially unsatisfactory posterior occlusion, relapse of crowding in the remaining three incisors and loss of the interdental gingival papillae in the lower anterior region (1, 3, 5-8).

Kokich and Shapiro (6) stated that with careful planning and case selection, single lower incisor extraction may allow the orthodontists to use simple treatment mechanics and to achieve good results. In such cases, a full diagnostic set-up was recommended in order to predict the exact occlusal changes (6, 9).

The aim of this case report is to present the treatment and 5-year follow-up of a patient with dental and skeletal Class I malocclusion and moderate lower anterior crowding, in whom one mandibular incisor extraction was selected as the treatment of choice in attempt to improve the dental occlusion.

Case Report

Diagnosis

A 19-year-old male patient presented at the clinic with the chief complaint of crowding of the lower anterior teeth. He had a symmetric face with competent lips, average smile line with consonant smile arch, and straight profile (Figure 1). The intraoral examination showed that the patient had good oral hygiene, and the periodontium was healthy. He had Class I molar and canine relationships bilaterally. He had Class I skeletal relationship, low angle vertical pattern, proclined upper and lower incisors and normal lip projection. The upper and lower dental midlines were coincident with the facial midline. The Bolton tooth size analysis (10) showed 1.5 mm lower anterior excess. The arch length discrepancies in the upper and lower arches were -1.6 mm and -5.4 mm, respectively. Maxillary central incisors crowns were triangular-shaped. The panoramic radiograph revealed that upper and lower third molars were erupting (Figure 2A).

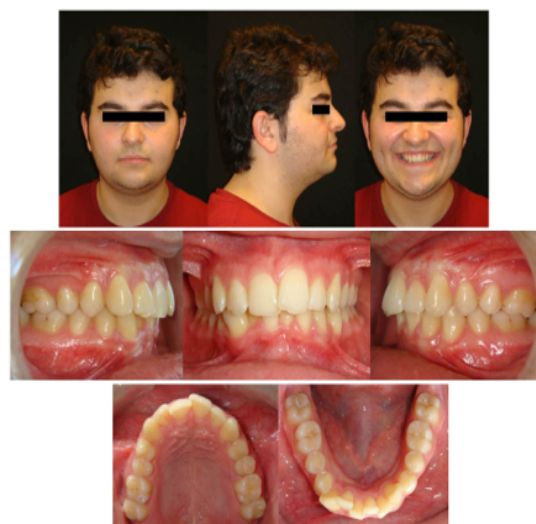

Figure 1. Pretreatment extraoral and intraoral photographs.

Treatment objectives

The primary treatment objectives for this patient were to eliminate crowding, maintain Class I canine/molar relationship bilaterally during treatment, and correct dental relationship without unfavorable profile change.

Treatment alternatives

Two treatment options were proposed to the patient: extraction of upper and lower first bicuspid, and extraction of one lower incisor. Extraction of four bicuspid could result in excessive retraction of the uncrowded maxillary incisors, compromising the facial profile and lip projection. Mandibular incisor extraction could eliminate lower arch crowding and correct the occlusion without affecting the facial profile and lip projection. The patient was informed about both options and their consequences. Patient preferred the incisor extraction option.

Treatment progress

Orthodontic brackets (0.018-inch slot, preadjusted Roth edgewise appliances) were placed on the maxillary teeth, and the initial alignment started with 0.014-inch nickel-titanium (Ni-Ti) archwire and the patient was referred for the extraction of lower right central incisor. One week after extraction, orthodontic brackets (0.018-inch slot, preadjusted Roth edgewise appliances) were placed on the mandibular teeth and

alignment for the lower arch was initiated with 0.014-in Ni-Ti archwire, at the same time a segment of light elastomeric chain was placed between lower right lateral incisor and left canine to close the diastema and eliminate crowding (Figure 3A, 3B, 3C). The elastomeric chain was changed every 3 weeks to maintain the activation. After elimination of the crowding, 0.016 x 0.016-in Ni-Ti wires followed by 0.016 x 0.022-in Ni-Ti wires were used for the upper and lower arches for levelling. Upper central incisors' mesiodistal widths were wider at the incisal edges than the cervical region (triangular-shaped). Upper central incisors were reshaped by reducing the maxillary central incisors 2 mm interproximally (Figure 3D, 3E). The treatment was finished with 0.016 x 0.022-in stainless-steel wires with ideal torque and shape. After satisfactory interdigitation was achieved, the fixed appliances were removed, and maxillary and mandibular canine-to-canine fixed lingual retainers were placed for retention (Figure 4).

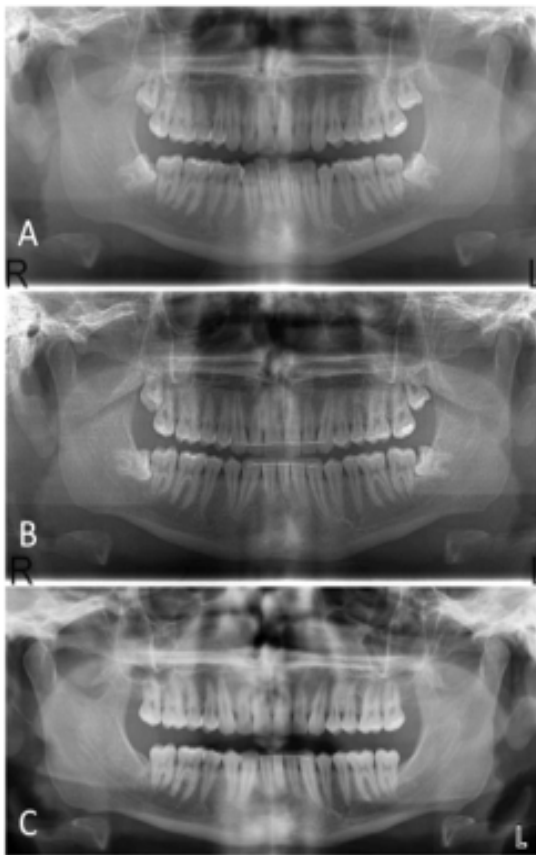


Figure 2. A, pretreatment panoramic radiograph; B, posttreatment panoramic radiograph; C, panoramic radiograph at 5-year follow-up.

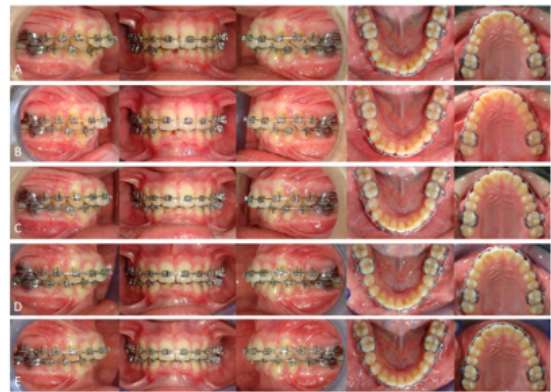

Figure 3. A, B, C, diastema closure; D, E, interproximal enamel reduction.

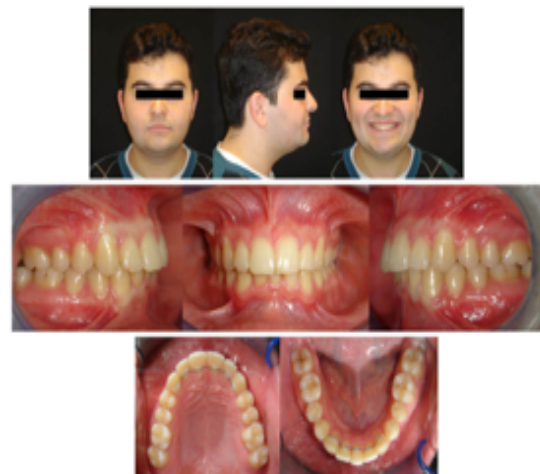

Figure 4. Posttreatment extraoral and intraoral photographs.

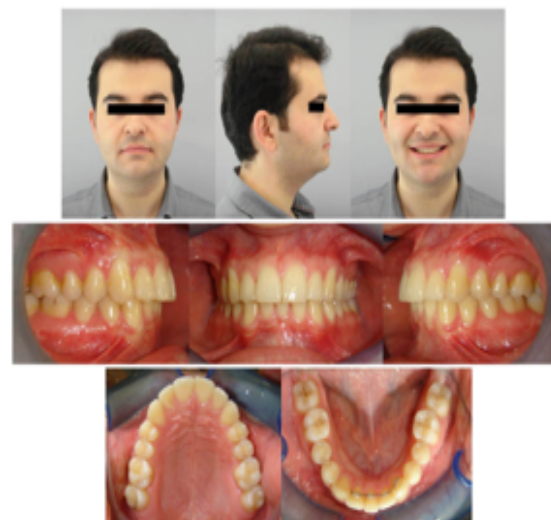

Figure 5. Retention facial and intraoral photographs at 5 years.

Results

The active treatment time was 16 months. The facial profile was maintained (Figure 4), treatment objectives were achieved and lower anterior crowding was eliminated. The posttreatment extraoral photographs showed a pleasing smile with a favorable smile arc. The patient was satisfied with the treatment results. In the panoramic radiograph, no sign of apical resorption or damage to the teeth was seen (Figure 2B). At the 5-year follow-up, the patient had a stable occlusion, with the results of the orthodontic treatment maintained (Figure 5, Figure 2C).

Discussion

This case revealed the clinical effectiveness of one incisor extraction in properly selected cases. Advantages of mandibular incisor extraction treatment are: decreased treatment time (6), long time stability in the mandibular anterior area (3, 7), and preservation of soft-tissue profile (8).

The possible disadvantages of this method are: unpleasant open extraction space, coincidence of the mandibular and maxillary dental midline is lost (8), a black triangle may form caused by the loss of the interdental papilla (11) and extraction of mandibular incisors may compromise the ideal overjet, overbite, and proper intercanine width in cases that do not have a Bolton (10) discrepancy except cases with small maxillary and large mandibular incisors. These factors should be contemplated before considering incisor extraction as a treatment option.

During the preliminary diagnosis of this patient, an accurate tooth-size analysis was made. The tooth-size analysis revealed a 1.6 mm mandibular anterior tooth size excess. The mandibular central incisors measured 5.4 mm mesiodistally. The extraction of lower right central incisor was planned which was the most proclined tooth in the lower anterior region. After extraction, a 4.3 mm maxillary tooth size excess resulted. This is not unusual after mandibular incisor extraction. The maxillary excess was resolved by reducing the maxillary central incisors 2 mm interproximally and by slightly increasing the anterior overjet and overbite. Factors to consider interproximal enamel reduction include: maxillary crown structure (triangular-shaped crowns are easier to reduce than columnar-shaped teeth), interproximal enamel thickness or the presence of interproximal restorations, root proximity and the

amount of interproximal alveolar bone (5). In this patient, the posttreatment maxillary tooth size excess was only 2.3 mm. The triangular-shaped crowns of the maxillary central incisors indicated interproximal reduction. Therefore the overjet and overbite were slightly increased. The treatment results were stable after 5 years of retention (Figures 5, 2C).

At the end of treatment the mandibular dental midline became the center of the remaining central incisor. Thus the maxillary midline coincided with the center of the remaining mandibular central incisor. It was reported that this situation does not compromise aesthetics or function (5).

Conclusion

If carefully planned, mandibular incisor extraction can be an effective treatment option that produces functional and aesthetic results with minimal orthodontic intervention.

Source of funding

None declared

Conflict of interest

None declared

References

1. Dacre JT. The long term effects of one lower incisor extraction. *Eur J Orthod* 1985;7(2):136-144.
2. Gottlieb EL, Nelson AH, Vogels DS, 3rd. 1996 jco study of orthodontic diagnosis and treatment procedures. Part 1. Results and trends. *J Clin Orthod* 1996;30(11):615-629.
3. Canut JA. Mandibular incisor extraction: Indications and long-term evaluation. *Eur J Orthod* 1996;18(5):485-489.
4. Faerovig E, Zachrisson BU. Effects of mandibular incisor extraction on anterior occlusion in adults with class III malocclusion and reduced overbite. *Am J Orthod Dentofacial Orthop* 1999;115(2):113-124.
5. Klein DJ. The mandibular central incisor, an extraction option. *Am J Orthod Dentofacial Orthop* 1997;111(3):253-259.
6. Kokich VG, Shapiro PA. Lower incisor extraction in orthodontic treatment. Four clinical reports. *Angle Orthod* 1984;54(2):139-153.
7. Riedel RA, Little RM, Bui TD. Mandibular incisor

- extraction--postretention evaluation of stability and relapse. *Angle Orthod* 1992;62(2):103-116.
8. Valinoti JR. Mandibular incisor extraction therapy. *Am J Orthod Dentofacial Orthop* 1994;105(2):107-116.
 9. Miller RJ, Duong TT, Derakhshan M. Lower incisor extraction treatment with the invisalign system. *J Clin Orthod* 2002;36(2):95-102.
 10. Bolton W. Disharmony in tooth size and its relation to the analysis and treatment of malocclusion. *Angle Orthod* 1958;28:113-130.
 11. Uribe F, Holliday B, Nanda R. Incidence of open gingival embrasures after mandibular incisor extractions: A clinical photographic evaluation. *Am J Orthod Dentofacial Orthop* 2011;139(1):49-54.

Corresponding Author:**Kadir BEYCAN**

Department of Orthodontics
Faculty of Dentistry Marmara University
34854 Maltepe / İstanbul, Turkey
Phone: +90 0216 421 16 21
e-mail: orthodonty@hotmail.com