

# Histopathological examination of the placenta after delivery in pregnant women with COVID-19

✉ Fatih Taş<sup>1</sup>, ✉ Fikri Erdemci<sup>2</sup>, ✉ Fırat Aşır<sup>2</sup>, ✉ Mustafa Maraşlı<sup>3</sup>, ✉ Engin Deveci<sup>2</sup>

<sup>1</sup>Siirt University, Faculty of Medicine, Department of Histology and Embryology, Siirt, Turkey

<sup>2</sup>Dicle University, Faculty of Medicine, Department of Histology and Embryology, Diyarbakır, Turkey

<sup>3</sup>Kartal Dr. Lütfi Kırdar City Hospital, Department of Obstetrics and Gynecology, İstanbul, Turkey

**Cite this article as:** Taş F, Erdemci F, Aşır F, Maraşlı M, Deveci E. Histopathological examination of the placenta after delivery in pregnant women with COVID-19. J Health Sci Med 2022; 5(3): 868-874.

## ABSTRACT

**Introduction:** COVID-19 is a viral disease generated by a new coronavirus named SARS-CoV-2. The consequences of this virus on the human placenta and the newborn are still unclear. IL-6 can disturb the placenta's immunological homeostasis and be employed as an inflammatory marker for the poor prognosis of COVID-19 infection. Bax has some features like being a key protein regulating apoptotic mechanisms and plays an important role in both maintaining dynamic balance and integrity in the placenta as in many tissues. This study aims to indicate the impact of COVID-19 on inflammation and apoptotic pathways in the placenta by using IL-6 and Bax antibodies.

**Material and Method:** COVID-19 positive (n:10) and COVID-19 negative (n:10) normotensive placentas were included. Haematoxylin-eosin staining and immunohistochemical staining (IL-6 and Bax antibodies) were applied. Statistical data of immunohistochemical (IL-6 and Bax expression) staining results were assessed by analyzing the H-score. Biochemical parameters were recorded. Group means were analyzed with a nonparametric Kruskal Wallis Test.

**Results:** In the COVID-19 group, increased syncytial knots, fibrin deposition, inflammation, fibrinoid necrosis, neutrophil accumulation were observed. The COVID-19 group had considerably higher levels of IL-6 and Bax expression than the control group. Furthermore, COVID-19 patients had statistically lower WBC and higher CRP values than normotensive patients.

**Conclusion:** COVID-19 has been linked to placental inflammation and trophoblast cell damage, both of which can result in major maternal and fetal problems during pregnancy. We found intense IL-6 expression in the placentas of pregnant women with COVID-19 infection. A rise in IL-6 levels triggers CRP production, and this increase is linked to the severity of COVID-19 as a risk factor. Also, we suggested that COVID-19 infection triggers the apoptotic process in placental tissue by increasing the expression of the proapoptotic Bax protein. It is clinically very significant to follow up COVID-19 positive pregnancies for maternal and fetal health. During this follow-up, IL-6 and Bax expression levels in the placenta, together with histopathological findings and serum CRP levels, can guide the evaluation of the prognosis, severity and response to treatment of the disease.

**Keywords:** COVID-19, placenta, IL-6, inflammation, Bax, apoptosis

## INTRODUCTION

In December 2019, a new coronavirus-related epidemic broke out in Wuhan and World Health Organization labeled it a pandemic (1). The pathogenic factor was determined as severe acute respiratory syndrome coronavirus 2 (SARS-CoV-2) based on phylogenetic research, and the disease caused by the virus was dubbed Coronavirus Disease 2019 (COVID-19) (2). The disease is diagnosed by real-time reverse transcriptase-polymerase chain reaction (rRT-PCR) (3). The clinic of COVID-19 viremia is similar to previous coronaviruses, which is a cause of severe acute respiratory syndrome (SARS). Clinical manifestations

are fever, cough, fatigue, sputum production, loss of taste sense, myalgia, difficulties in breathing, etc. (2,3). Pregnant patients with COVID-19 disease and nonpregnant adult patients have similar clinical characteristics (4). Ground-glass opacity (56.4 percent) and bilateral patchy shadowing were found to be the most prevalent radiological abnormalities on computed tomography (51.8 percent). Lymphocytopenia, thrombocytopenia, leukopenia, and elevated C-reactive protein (CRP) levels are more common laboratory findings in patients with COVID-19 positive. COVID-19 is treated with remdesivir, anticytokinic

biological agents (anti-interleukin-1 (IL-1) (Anakinra) and anti-interleukin-6 (IL-6) (Tocilizumab, TCZ), IVIG (intravenous gammaglobulin), and recently vaccines (e.g., Biontech, sinovac, moderna) are recommended (5,6).

Maternal morbidity is a health problem due to pregnancy. Infections and eclampsia are among the most common causes (7). Pregnancy diseases can adversely affect the fetus as much as the mother. Respiratory viral infections observed during pregnancy cause serious obstetric and neonatal consequences (8). Pregnancy-related complications associated with maternal and fetal morbidity have a close relationship with the placenta (9). However, the impacts of COVID-19 on human placenta and newborn are not fully understood (10). Since the COVID-19 reports are based on a limited number of cases (10,11), comprehensive studies are needed to define placental histopathological findings specific to COVID-19 infection.

In normal pregnancies, there is a mild systemic inflammatory response (12). Leukocyte count increases, neutrophils and monocytes are activated (13), and concentrations of circulating inflammatory cytokines (IL-6, Tumor necrosis factor- $\alpha$ ) increase (14). The secretion levels of these cytokines with increasing concentrations are affected by each other (15). Many tissues release IL-6 as a pleiotropic immunomodulatory cytokine in response to infection and tissue damage. Acute phase responses, hematopoiesis, and immune cell development and activation are all regulated by it (16). IL-6, which are products of activated macrophages, has negative effects on pregnancy (17). It interferes with many events affecting fetal growth, such as nutrient transfer, anoxia, and vascular permeability, by acting in the fetomaternal gap (18). IL-6 can also disturb the placenta's immunological homeostasis (18) and be employed as an inflammatory marker for the poor prognosis of COVID-19 infection (19). IL-6 levels over a certain threshold are linked to the necessity for mechanical ventilation. Patients with high IL-6 levels ( $\geq 80$  pg/ml) are 22 times more likely to have respiratory failure than those with low IL-6 levels (20). Therefore, antisitokinic drugs such as TCZ, a monoclonal antibody against IL-6, are used as a treatment option for COVID-19 patients (21).

Apoptosis is programmed cell death and plays a significant role in tissue homeostasis, embryonic growth, and immunity. Bcl-2 family control apoptosis with proapoptotic proteins and antiapoptotic proteins (22). The balance between proapoptotic and antiapoptotic protein expression determines the outcome of apoptosis (23). Bax, one of these proteins, is a molecule that stimulates apoptosis and that causes cytochrome c to be released from the mitochondria when produced. When it is released, it activates caspase-9 and caspase-3, respectively (23). Bax has some features like being a key

protein regulating apoptotic mechanisms and plays an important role in both maintaining dynamic balance and integrity in the placenta as in many tissues (24).

This study's purpose is to demonstrate the consequences of COVID-19 on inflammation and apoptotic pathways in the placenta by using IL-6 and Bax antibodies.

## MATERIAL AND METHOD

The study was carried out with the permission of Siirt University Non-Interventional Clinical Researches Ethics Committee (Date: 23.09.2020, Decision No: E.11597). All procedures were realized in accordance with the ethical rules and the principles of the Declaration of Helsinki. Patients who were approved to participate in this study were informed about it and completed an informed consent form.

Placental tissue was obtained from patients submitted to the Obstetrics and Gynecology Department of the Siirt Training and Research Hospital. The study included placentas from pregnant women who tested positive for COVID-19 PCR during pregnancy (n:10) and placentas from pregnant women who tested negative for COVID-19 (n:10). This study did not include patients in both groups with secondary or chronic diseases (such as any respiratory infection, pregnancy complications, or other systemic diseases).

### Obtaining and Following-up Tissues

Placental tissue was processed for routine histological examination, fixed in %10 formaldehyde, passed through an ascending alcohol series, and then incubated in xylene and in paraffin. 5  $\mu$ m thick sections were stained with hematoxylin-eosin (HE) staining and immunohistochemical staining. Biochemical blood parameters were recorded for all patients.

### Immunohistochemical Staining

Sections were brought to distilled water and soaked in EDTA buffer solution (pH:8.0, lot number: ab93680, Abcam) for epitope retrieval in a microwave oven at 700 Watts for 10 minutes. For endogenous peroxidase blocking, hydrogen peroxide solution (lot number: TA-015-HP, Thermo Fischer) was dropped into this section and incubated for 20 minutes. After blocking solution, sections were overnight with IL-6 (catalog no: sc-32296, Santa Cruz Biotechnology) and Bax (catalog no: sc-20067, Santa Cruz Biotechnology) antibodies at 1/100 dilution. Diaminobenzidine (DAB) (lot number: TA-001-HCX, Thermo Fischer) was used as chromogen. After counterstaining with Harris haematoxylin, sections were mounted with entellan (lot number: 107961, Sigma-Aldrich) and analyzed with Zeiss Imager A2 (Germany) by Zen 3.2 lite software.

The H-score (HS) was used to assess the outcomes of immunohistochemical staining.  $HS = \sum (1 + i) \times \pi_i$ . Where i indicates the staining intensity (0=no expression, 1=light, 2=medium, 3=dense, and 4=very dense) and  $\pi_i$  indicates the percentage of staining intensity (25). Results were given as  $\pm$  standard error. Statistical analysis of the results obtained was made.

### Statistical Analysis

IBM SPSS software (ver. 25) was used for statistical analysis. The nonparametric Kruskal Wallis Tests were used to examine the mean values of groups. All data were given as a mean with a standard deviation (S.D.). Any p value < 0.05 was admitted statistically significant.

## RESULTS

### Laboratory Statistics

In terms of RBC (red blood cell), MCV (mean corpuscular volume), MCH (mean corpuscular hemoglobin), HGB (hemoglobin), HTC (hematocrit), PLT (platelet), neutrophil, lymphocyte, monocyte, eosinophil, and basophil values, there was no significant difference ( $p > 0.05$ ) between experimental (COVID-19) and control groups. They are in normal range in both groups. The WBC value in the experimental group (COVID-19) was considerably lower than the control group ( $p < 0.05$ ), whereas CRP value in the experimental group (COVID-19) was considerably higher than the control group ( $p < 0.05$ ) (Table 1).

Table 1. Laboratory findings (mean) and statistical comparison between groups			
Parameter	Control (mean±SD)	COVID-19 (mean±SD)	Paired-comparison
WBC ( $10^3/mm^3$ )	10.72±1.83	8.66±1.84	p=0.034
RBC ( $10^{12}/L$ )	4.54±0.43	4.24±0.45	p=0.096
HGB (g/dl)	12.62±1.68	11.68±1.21	p=0.257
HCT (%)	39.01±4.51	36.86±2.97	p=0.472
PLT ( $10^3/mm^3$ )	254.2±70.61	262.30±77.51	p=0.940
MCV (fL)	88.50±5.08	87.53±7.19	p=0.910
MCH (pg)	29.05±1.52	28.42±2.13	p=0.406
Neutrophil (%)	75.49±3.95	69.28±22.84	p=0.940
Lymphocyte (%)	18.34±4.32	17.22±4.16	p=0.449
Monocyte (%)	5.71±1.26	4.78±1.01	p=0.130
Eosinophil (%)	0.78±0.27	0.95±0.54	p=0.422
Basophil (%)	0.22±0.10	0.29±0.14	p=0.229
CRP (mg/dl)	10.22±7.60	22.51±12.83	p=0.026

SD: Standard deviation

### Immunohistochemical Statistics

Statistical data of immunohistochemical (IL-6 and Bax expression) staining results indicated in Table 2 were evaluated by investigating the H-score. The levels of IL-6 and Bax expression in COVID-19 group were found to be considerably higher than in the control group ( $p < 0.05$ ).

### Histopathological Findings

Haematoxylin-eosin staining of placental tissues belonging to COVID-19 group are shown in Figure 1 and Figure 2, respectively. IL-6 and Bax immunostaining of placental tissues belonging to the control and COVID-19 groups are shown in Figure 3 and Figure 4, in sequence. In the control group, normal histology was observed with cytotrophoblasts, syncytiotrophoblasts, fetal capillaries, and villous stroma. No pathology was observed in the stromal connective tissue and vascular structures (not shown in figures). In the placenta of COVID-19 group, increased syncytial knots, fibrin deposition, fibrinoid necrosis in the vascular wall, intervillous hemorrhage, inflammation, neutrophil accumulation, fetal villi with chorangiosus and oedema were observed (Figure 1 and 2). IL-6 and Bax expression levels were increased considerably in COVID-19 group competing with the control group ( $p < 0.05$ ). IL-6 expression was mostly negative in the control group (Figure 3a), yet it was intense in syncytial knots and syncytiotrophoblast cytoplasm (Figure 3b) in COVID-19 group. Bax expression was mostly negative in the syncytial knots and tertiary villi in the control group (Figure 4a). In COVID-19 group, Bax reaction was positive predominantly in syncytiotrophoblast cytoplasm (Figure 4b).

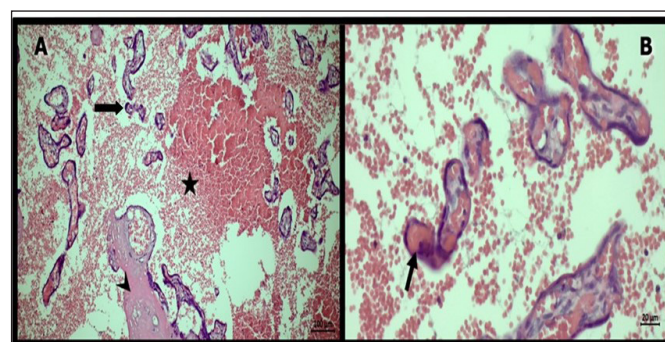
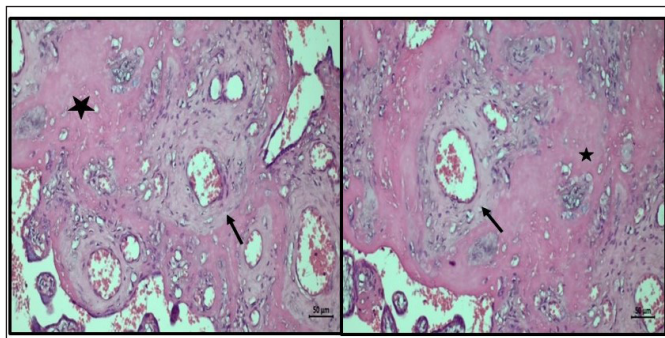
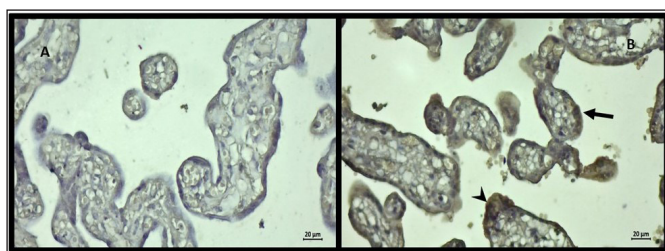


Figure 1. HE staining of placental tissues belonging to the COVID-19 group (A), Increased syncytial knots (arrow), fibrin deposition (arrowhead), and intervillous hemorrhage (star) (X10) (B) Fetal villi with oedema and chorangiosus (arrow) (X40)

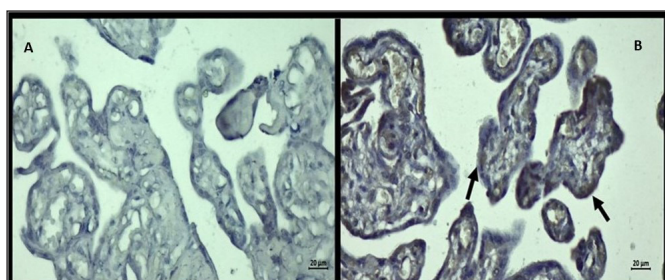
	Control Placentas						COVID-19 Placentas						Comparison between groups
	Number	Mean	Std deviation	Median	Min	Max	Number	Mean	Std deviation	Median	Min	Max	
IL-6	10	0.5	0.52	0.5	0	1	10	3.8	0.42	4	3	4	p<0.01
Bax	10	0.4	0.52	0	0	1	10	2.4	0.52	2	2	3	p<0.01



**Figure 2.** HE staining of placental tissue: fibrin deposition (star) and fibrinoid necrosis in vascular wall (arrow) in the placenta belonging to the COVID-19 group (X20)



**Figure 3.** IL-6 immunohistochemical staining of placental tissue (A) Generally negative expression was observed in the control group (B) IL-6 expression was observed mostly in syncytiotrophoblast cytoplasm (arrow) and syncytial knots (arrowhead) in COVID-19 placentas (X40)



**Figure 4.** Bax immunohistochemical staining of placental tissue (A) Generally negative expression was determined in the control group (B) Bax expression was determined mostly in syncytiotrophoblast cytoplasm in COVID-19 placentas (arrows) (X40)

## DISCUSSION

The placenta develops dynamically during pregnancy and may undergo various changes depending on pregnancy pathology. Changes in the placenta provide clues about maternal and fetal morbidity (26). Inflammatory and infectious diseases are among the indications that require histopathological evaluation of the placenta (27). However, the relationship of some diseases to pregnancy is not fully understood because some placental lesions do not have pregnancy-specific changes and some placental lesions are not associated with perinatal mortality and morbidity (28). COVID-19 infection during pregnancy is also one of the diseases whose maternal and fetal effects are not yet very clear (29). Therefore, the diagnosis and treatment of the illness during pregnancy is essential to control maternal and infant complications correlate with the disease.

Former coronavirus pandemics, such as SARS and the Middle East respiratory disease (MERS), have been linked to maternal and perinatal complications, including infections, mortality, and spontaneous abortion during pregnancy (30). Similarly, related to COVID-19 disease, conditions such as miscarriage, preterm birth and stillbirth have been reported (31). Therefore, the results of the histopathological analysis of the placenta may have significant contributions to maintaining of maternal and fetal health.

COVID-19 is a disease caused by SARS-CoV-2 that induces inflammation (32). In some studies, it is stated that COVID-19 infection is not present in the placenta, and vertical contamination is quite infrequent (33). Accordingly, the placental alterations produced by COVID-19 may be due to inflammation and maternal infection rather than fetal illness (32). In our study, the laboratory values of pregnant women who have COVID 19 agreed with literature. Additionally, we found that CRP values were high, and patients had leukopenia (Table 1).

During pregnancy, viral infections can cause specific placental alterations (32). In the histopathological examination of placentas from SARS patients, decreased placental perfusion, subchorionic and intervillous fibrin aggregation, achorionic villus areas, and fetal thromboangiopathy were observed (30,34). On the other hand, how COVID-19 affects placental pathology during pregnancy is not completely known yet (35). Shanes et al. (32) study on placentas from infected pregnant women with COVID-19 demonstrated that maternal fibrinoid necrosis, vascular malperfusion, decidual arteriopathy and atherosclerosis. Authors also suggested that; perivillous fibrin accumulation, intervillous thrombi, villous oedema, and chorangiosis in some placental tissues. According to these findings, chorangiosis is linked to a decrease in maternal oxygen saturation (32). In another research of placentas from COVID-19 patients, perivillous fibrin accumulation, locally increased syncytial knots, and pathology of fetal vascular malperfusion (thrombosis, intramural fibrin deposition, stromal vascular karyorrhexis, avascular villi) were reported. In addition, in some cases, chronic villitis associated with obliterative vasculopathy has also been observed (10).

In our study, placentas with COVID-19, increased syncytial knots, fibrin deposition, intervillous hemorrhage, inflammation, neutrophil accumulation, fetal villi with chorangiosis, and oedema findings were observed (Figures 1 and 2). Both our study and other studies (32) reveal that the observation of various histopathological changes in the placenta suggests that it may be linked to COVID-19.

In the study, placentas were analyzed by immunohistochemical methods in symptomatic COVID-19 in second trimester pregnancy. It has been reported that in the fetomaternal gap of the placenta, the SARS-CoV-2 virus is mostly found in syncytiotrophoblast cells by SARS-CoV-2 spike protein immunostaining. In addition, histological examination showed macrophages and T-lymphocyte infiltration suggesting a histiocytic intervillous space by CD68 and CD3 immunostaining (35). In our study, we showed inflammation and apoptosis in the placenta by using IL-6 and Bax immunostaining (**Table 2**).

Cytokines, which act as immunomodulators during pregnancy, are of great importance for a healthy pregnancy (36). Implantation, placental development, extravillous trophoblast invasion, cytotrophoblast proliferation, angiogenesis, spiral artery remodeling, cell growth, and apoptosis are all regulated by the maternal-fetal space to the existence of cytokines. IL-6 is an important proinflammatory cytokine that plays a role in the acute phase response to injury and infection (37). Furthermore, increased levels of this cytokine in the fetomaternal gap are associated with fetal loss (38). Therefore, elevated IL-6 values may be important in the follow-up of the threat of miscarriage in pregnant women.

Patients with COVID-19 infection usually have high serum inflammatory markers, including high CRP and cytokine (IL-6) levels (39). We found intense IL-6 expression in the placentas of pregnant women with COVID-19 infection, especially in syncytial knots and syncytiotrophoblast cytoplasm (**Figure 3**). Similarly, CRP values were considerably higher in these patients. As a result, IL-6 and CRP readings can be utilized together as indicators to assess the severity of the illness of COVID-19 patients throughout pregnancy.

Monoclonal antibodies are currently used to diagnose, research, prevent, and treat diseases (40). In the treatment of some COVID-19 patients, the effectiveness of monoclonal antibodies developed against cytokines such as IL-6 are evaluated (41,42). In cytokine release syndrome and acute inflammation, there is a significant role of IL-6 (43). Additionally, a rise in IL-6 levels triggers CRP production, and this increase is linked to the severity of COVID-19 as a risk factor (44). Thus, some drugs may be effective in COVID-19 patients by blocking the signal transduction pathway of IL-6 (43). Studies have reported that these drugs cause a significant decrease in CRP levels, an increase in lymphocyte count, and a decrease in COVID-19 clinical symptoms and prognosis (41,45). Tocilizumab is an IL-6 inhibitor and is used in the context of clinical trials in the handling of COVID-19 (46). This drug may be safe due to the small amount of transplacental interaction during pregnancy (47). On the other hand, as the teratogenic effects of such drugs

in pregnancy are not fully known, more comprehensive studies are needed to be used in these cases.

Increases in the number of COVID-19 patients lead to the emergence of new variants (Alpha, Beta, Gamma, Delta, and Omicron). Of these, emerging variants such as Omicron adversely affect the success of monoclonal antibody therapy due to mutations in the spike protein receptor binding sites (48). The fact that newly emerged variants (Delta and Omicron) can lead to unsuccessful results in monoclonal antibody treatment (48) reveals that new variants should be taken into account when making arrangements for the treatment of pregnant women with COVID-19.

Apoptotic cell death in endothelial cells of vascular structures due to SARS-CoV-2 infection has been demonstrated in various organs (49). Furthermore, apoptosis has important roles in placental homeostasis, growth, and reform. Abnormalities in the expression of Bax protein, which is involved in apoptosis, are associated with some pathological placental changes (24). In a study, Bax protein was discovered to be a good indicator of apoptotic alterations in placentas with gestational diabetes and preeclampsia (50). In another study, it was reported that the Bax gene could be responsible for pregnancy loss, and variation of this gene would be useful in the evaluation of recurrent pregnancy loss (51).

In our study, Bax expression was observed in the syncytiotrophoblast cytoplasm in the COVID-19 group (**Figure 4**). It is founded that the cytokine storm and oxidative stress seen in some COVID-19 cases lead to reactive oxygen species-dependent apoptosis of endothelial cells (39). In addition, cytokines such as IL-6 produced in the cytokine storm seen in COVID-19 patients are known to cause apoptosis in lymphoid organs (52). Apoptosis in lymphoid organs due to COVID-19 may also apply to syncytiotrophoblast cells in the placenta. As a matter of fact, the fact that IL-6 and Bax expressions were found to be high together in COVID-19 positive placentas in our study supports this idea. All these data suggest that COVID-19 infection triggers the apoptotic process in placental tissue by increasing the expression of the proapoptotic Bax protein. At this point, it may be beneficial to use Bax and IL-6 expression as a marker to determine apoptotic changes in the placenta in COVID-19.

### Limitations

Our study has some limitations; first, the limited number of patients limits the accuracy of the results, necessitating comprehensive studies of large numbers of patients. Second, IL-6 and Bax antibodies were used for immunohistochemistry in this study. Therefore, the scope of research could be expanded in the future by using other markers of inflammation and apoptosis.

## CONCLUSION

We believe that COVID-19 causes placental inflammation and damage to trophoblast cells, which can lead to severe maternal and infant disease during pregnancy. Therefore, clinical follow-up of pregnant women infected with COVID-19 is of great significance. During this follow-up, IL-6 and Bax expression levels in the placenta, together with histopathological findings and serum CRP levels, can guide the evaluation of the prognosis, severity and response to treatment of the disease. More comprehensive research is needed to support our recommendations.

## ETHICAL DECLARATIONS

**Ethics Committee Approval:** The study was carried out with the permission of Siirt University Non-Interventional Clinical Researches Ethics Committee (Date: 23.09.2020, Decision No: E.11597).

**Informed Consent:** Patients who approved to participate in this study were informed about it and completed an informed consent form.

**Referee Evaluation Process:** Externally peer-reviewed.

**Conflict of Interest Statement:** All authors state that there is no conflict of interest.

**Financial Disclosure:** This research received specific grant from Siirt University Scientific Research Center with protocol number 2020-SİÜTIP-037. We kindly thank to Siirt University for their financial aid to conduct this study.

**Author Contributions:** All of the authors declare that they have all participated in the design, execution, and analysis of the paper, and that they have approved the final version.

## REFERENCES

- Cucinotta D, Vanelli M. WHO declares COVID-19 a pandemic. *Acta Biomed* 2020; 91: 157-60.
- Eastin C, Eastin T. Clinical characteristics of coronavirus disease 2019 in China. *J Emerg Med* 2020; 58: 711-2.
- Özüdoğru O, Bolatlı G, Tas F. Investigation of revers-transcriptase polymerase chain reaction values of patients with COVID-19 findings in lung computed tomography results. *J Teknology Laboratorium* 2020; 9: 41-8.
- Chen H, Guo J, Wang C, et al. Clinical characteristics and intrauterine vertical transmission potential of COVID-19 infection in nine pregnant women: a retrospective review of medical records. *Lancet* 2020; 395: 809-15.
- Shoenfeld Y. Corona (COVID-19) time musings: our involvement in COVID-19 pathogenesis, diagnosis, treatment and vaccine planning. *Autoimmun Rev* 2020; 19: 102538.
- Turner PJ, Ansotegui IJ, Campbell DE, et al. COVID-19 vaccine-associated anaphylaxis: A statement of the World Allergy Organization Anaphylaxis Committee. *World Allergy Organization Journal* 2021; 14: 100517.
- Koblinsky M, Chowdhury ME, Moran A, Ronsmans C. Maternal morbidity and disability and their consequences: neglected agenda in maternal health. *J Health Popul Nutr* 2012; 30: 124-30.
- Golden TN, Simmons RA. Maternal and neonatal response to COVID-19. *Am J Physiol Endocrinol Metab* 2020; 319: 315-9.
- Hromadnikova I, Kotlabova K, Ondrackova M, et al. Expression profile of C19MC microRNAs in placental tissue in pregnancy-related complications. *DNA Cell Biol* 2015; 34: 437-57.
- Baergen RN, Heller DS. Placental pathology in COVID-19 positive mothers: preliminary findings. *Pediatr Dev Pathol* 2020; 23: 177-80.
- Chen S, Huang B, Luo DJ, et al. Pregnancy with new coronavirus infection: clinical characteristics and placental pathological analysis of three cases. *Zhonghua bing li xue za zhi= Chinese J Pathol* 2020; 49: 418-23.
- Cemgil Arıkan D, Aral M, Coskun A, Ozer A. Plasma IL-4, IL-8, IL-12, interferon- $\gamma$  and CRP levels in pregnant women with preeclampsia, and their relation with severity of disease and fetal birth weight. *J Matern Fetal Neonatal Med* 2012; 25: 1569-73.
- Li A, Yang S, Zhang J, Qiao R. Establishment of reference intervals for complete blood count parameters during normal pregnancy in Beijing. *J Clin Lab Anal* 2017; 31: e22150.
- Sharma A, Satyam A, Sharma JB. Leptin, IL-10 and inflammatory markers (TNF-alpha, IL-6 and IL-8) in pre-eclamptic, normotensive pregnant and healthy non-pregnant women. *Am J Reprod Immunol* 2007; 58: 21-30.
- Popko K, Gorska E, Stelmaszczyk-Emmel A, et al. Proinflammatory cytokines IL-6 and TNF- $\alpha$  and the development of inflammation in obese subjects. *Eur J Med Res* 2010; 15: 120-2.
- Stinson LF, Payne MS, Keelan JA. Placental and intra-amniotic inflammation are associated with altered fetal immune responses at birth. *Placenta* 2019; 85: 15-23.
- Granger JP, Alexander BT, Llinas MT, Bennett WA, Khalil RA. Pathophysiology of preeclampsia: linking placental ischemia/hypoxia with microvascular dysfunction. *Microcirculation* 2002; 9: 147-60.
- Hsiao EY, Patterson PH. Activation of the maternal immune system induces endocrine changes in the placenta via IL-6. *Brain Behav Immun* 2011; 25: 604-15.
- Chen X, Zhao B, Qu Y, et al. Detectable serum severe acute respiratory syndrome coronavirus 2 viral load (RNAemia) is closely correlated with drastically elevated interleukin 6 level in critically ill patients with coronavirus disease 2019. *Clin Infect Dis* 2020; 71: 1937-42.
- Herold T, Jurinovic V, Arnreich C, et al. Level of IL-6 predicts respiratory failure in hospitalized symptomatic COVID-19 patients. *MedRxiv* 2020; doi.org/10.1101/2020.04.01.20047381.
- Luo P, Liu Y, Qiu L, Liu X, Liu D, Li J. Tocilizumab treatment in COVID-19: a single center experience. *J Med Virol* 2020; 92: 814-8.
- Peña-Blanco A, García-Sáez AJ. Bax, Bak and beyond-mitochondrial performance in apoptosis. *Febs J* 2018; 285: 416-31.
- Cil N, Kabukçu C. Effect of vitamin D application on the endometrium. *Pamukkale Med J* 2021; 14: 175-83.
- Fan J, Yu S, Cui Y, et al. Bcl-2/Bax protein and mRNA expression in yak (*Bos grunniens*) placentomes. *Theriogenology* 2017; 104: 23-9.
- Karakoç Z, Topaloğlu U, Ketani MA. Immunohistochemical distribution of ghrelin, obestatin, and leptin hormones in the abomasum of hair goat. *Eurasian J Vet Sci* 2019; 35: 204-9.
- Curtin WM, Krauss S, Metlay LA, Katzman PJ. Pathologic examination of the placenta and observed practice. *Obstet Gynecol* 2007; 109: 35-41.
- Lema G, Mremi A, Amsi P, et al. Placental pathology and maternal factors associated with stillbirth: An institutional based case-control study in Northern Tanzania. *PLoS One* 2020; 15: e0243455.

28. Roescher AM, Hitzert MM, Timmer A, Verhagen EA, Erwich JJH, Bos AF. Placental pathology is associated with illness severity in preterm infants in the first twenty-four hours after birth. *Early Human Development* 2011; 87: 315-9.
29. Mullins E, Evans D, Viner RM, O'Brien P, Morris E. Coronavirus in pregnancy and delivery: rapid review. *Ultrasound Obstet Gynecol* 2020; 55: 586-92.
30. Schwartz DA, Graham AL. Potential maternal and infant outcomes from (Wuhan) coronavirus 2019-nCoV infecting pregnant women: lessons from SARS, MERS, and other human coronavirus infections. *Viruses* 2020; 12: 194.
31. Di Mascio D, Khalil A, Saccone G, et al. Outcome of coronavirus spectrum infections (SARS, MERS, COVID-19) during pregnancy: a systematic review and meta-analysis. *Am J Obstet Gynecol MFM* 2020; 2: 100107.
32. Shanes ED, Mithal LB, Otero S, Azad HA, Miller ES, Goldstein JA. Placental pathology in COVID-19. *Am J Clin Pathol* 2020; 154: 23-32.
33. Lamouroux A, Attie-Bitach T, Martinovic J, Leruez-Ville M, Ville Y. Evidence for and against vertical transmission for severe acute respiratory syndrome coronavirus 2. *Am J Obstet Gynecol* 2020; 223: 91-4.
34. Ng WE, Wong SF, Lam A, et al. The placentas of patients with severe acute respiratory syndrome: a pathophysiological evaluation. *Pathology* 2006; 38: 210-8.
35. Hosier H, Farhadian SF, Morotti RA, et al. SARS-CoV-2 infection of the placenta. *J Clin Invest* 2020; 130: 4947-53.
36. Risvanli A, Godekmerdan A. The effects of post-mating administration of anti-IL-10 and anti-TGF $\beta$  on conception rates in mice. *Int J Fertil Steril* 2015; 9: 65-70.
37. Lash GE, Ernerudh J. Decidual cytokines and pregnancy complications: focus on spontaneous miscarriage. *Jf Reproduct Immunol* 2015; 108: 83-9.
38. Zenclessen AC, Blois S, Stumpo R, et al. Murine abortion is associated with enhanced interleukin-6 levels at the fetomaternal interface. *Cytokine* 2003; 24: 150-60.
39. Zinovkin RA, Grebenchikov OA. Transcription factor Nrf2 as a potential therapeutic target for prevention of cytokine storm in COVID-19 patients. *Biochemistry (Mosc)* 2020; 85: 833-7.
40. Liu JKH. The history of monoclonal antibody development-progress, remaining challenges and future innovations. *Annals of Medicine and Surgery* 2014; 3: 113-6.
41. Aziz M, Haghbin H, Abu Sitta E, et al. Efficacy of tocilizumab in COVID-19: a systematic review and meta-analysis. *J Med Virol* 2021; 93: 1620-30.
42. Chen G, Wu D, Guo W, et al. Clinical and immunological features of severe and moderate coronavirus disease 2019. *J Clin Invest* 2020; 130: 2620-9.
43. Zhang C, Wu Z, Li JW, Zhao H, Wang GQ. Cytokine release syndrome in severe COVID-19: interleukin-6 receptor antagonist tocilizumab may be the key to reduce mortality. *Int J Antimicrob Agents* 2020; 55: 105954.
44. Gao YD, Ding M, Dong X, et al. Risk factors for severe and critically ill COVID-19 patients: a review. *Allergy* 2021; 76: 428-55.
45. Mazzoni A, Salvati L, Maggi L, et al. Impaired immune cell cytotoxicity in severe COVID-19 is IL-6 dependent. *J Clin Invest* 2020; 130: 4694-703.
46. Chen CH, Lin SW, Shen CF, Hsieh KS, Cheng CM. Biomarkers during COVID-19: mechanisms of change and implications for patient outcomes. *Diagnostics* 2022; 12: 509.
47. Saito J, Yakuwa N, Kaneko K, et al. Tocilizumab during pregnancy and lactation: drug levels in maternal serum, cord blood, breast milk and infant serum. *Rheumatology (Oxford)* 2019; 58: 1505-7.
48. Tanase A, Manea A, Scurtu AD, et al. The "Invisible Enemy" SARS-CoV-2: viral spread and drug treatment. *Medicina* 2022; 58: 261.
49. Seyit M, Avci E, Yilmaz A, Senol H, Ozen M, Oskay A. Predictive values of coagulation parameters to monitor COVID-19 patients. *Int J Clin Practice* 2022; 8436248.
50. Gokalp-Ozkorkmaz E, Asir F, Basaran SO, et al. Examination of Bcl-2 and Bax protein levels for determining the apoptotic changes in placentas with gestational diabetes and preeclampsia. *Proceedings* 2018; 2: 1548.
51. Mohammad Seyedhassani S, Houshmand M, Mehdi Kalantar S, et al. BAX pro-apoptotic gene alterations in repeated pregnancy loss. *Arch Med Sci* 2011; 7: 117-22.
52. Mutlu P, Mirici A, Gönügür U, et al. Evaluating the clinical, radiological, microbiological, biochemical parameters and the treatment response in COVID-19 pneumonia. *J Health Sci Med* 2022; 5: 544-51.